

## Lateral canthotomy and cantholysis: a simple, vision-saving procedure

Gord McInnes, MD;\* Daniel W. Howes, MD\*†

### ABSTRACT

Lateral canthotomy and cantholysis is a simple procedure that can be performed by emergency physicians. It has the potential to save vision, particularly in cases of blunt ocular trauma. The case of a 37-year-old man with blunt ocular trauma, a retrobulbar hemorrhage and rapidly increasing orbital pressure requiring an urgent lateral canthotomy and cantholysis is presented. Pathophysiology, indications, contraindications, procedure and follow-up care are described.

### RÉSUMÉ

La canthotomie et la cantholyse latérale est une intervention simple qui peut être effectuée par le médecin d'urgence. Elle peut permettre de sauver la vue, surtout dans les cas de traumatisme oculaire contondant. Nous présentons le cas d'un homme de 37 ans victime d'un traumatisme oculaire contondant accompagné d'une hémorragie rétrobulbaire et d'une augmentation rapide de la pression orbitaire qui nécessita une canthotomie et une cantholyse latérale d'urgence. La physiopathologie, les indications, les contre-indications, l'intervention et les soins de suivi sont décrits.

**Key words:** lateral canthotomy and cantholysis, ocular trauma, retrobulbar hematoma

### Introduction

Lateral canthotomy and cantholysis (LCC) is a simple procedure used to decompress a compartment syndrome of the orbit. It is most often used in cases of blunt trauma, when bleeding into the retrobulbar space causes an increase in pressure resulting in ischemia to the retina and optic nerve.<sup>1</sup> LCC can be easily performed by the emergency physician, and has the potential to save the patient's vision. In this article a case study is presented, then the pathophysiology, indications and contraindications, a step-by-step approach to the procedure and follow-up care are detailed.

### Case report

A previously healthy 37-year-old man was brought to the emergency department (ED) following a high-speed colli-

sion between a snowmobile and a sport utility truck. Despite having worn a helmet, he had suffered significant damage to the left side of his face. On arrival, his Glasgow Coma Scale score was 6, and the paramedics were assisting his ventilations. Shortly after intubation, ED staff noted that the patient's left eye was increasingly proptotic. A tonometer was not readily available, but the left eye also felt noticeably firmer than the right. The patient was found to have a left afferent pupillary defect, so an urgent LCC was performed.

A CT scan revealed that the source of the increased intraocular pressure (IOP) and proptosis was a medial rectus muscle hematoma. Other injuries identified included an acute subdural hematoma requiring an emergent craniotomy, a non-displaced C6 pedicle fracture and a medial-wall orbital blowout fracture.

Postoperatively, the patient was diagnosed with optic

From the \*†Department of Emergency Medicine, and †Division of Critical Care, Queen's University, Kingston, Ont., and †Kingston General Hospital, Kingston, Ont.

Received: Feb. 1, 2001; final submission: Aug. 15, 2001; accepted: Oct. 3, 2001

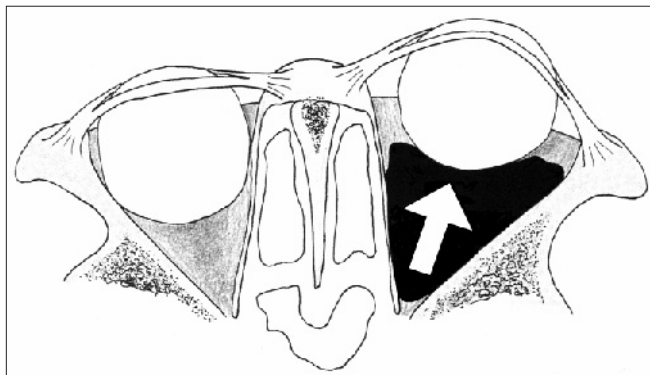
*This article has been peer reviewed.*

nerve ischemia. At the time of hospital discharge, his visual acuity was 20/200 in the affected eye, but with time and resolution of the inflammation it returned to 20/20.

## Discussion

### Pathophysiology

The orbit is composed of 7 bones that enclose all but the anterior aspect. Here, the globe obstructs the opening to the bony orbit (Fig. 1). Following trauma, the presence of hemorrhage, foreign body or edema can increase retrobulbar pressure. The orbit compensates through proptosis, but the medial and lateral canthal tendons, which attach the eyelids to the orbital rim,<sup>2</sup> limit the forward movement of the globe. As proptosis is restricted, the orbital pressure increases and impedes the optic nerve's vascular supply.<sup>3</sup> If IOP exceeds central retinal artery pressure, retinal ischemia results.<sup>2</sup> In such situations, timely LCC can save visual function. Table 1 sum-



**Fig. 1: Expanding retro-orbital hematoma.** An expanding hematoma within the orbit increases the intraorbital volume. The globe compensates by proptosis, but is limited by the canthal tendons (see also Fig. 3). Once the globe is maximally displaced, the intraorbital pressure increases.

**Table 1. Indications and contraindications for lateral canthotomy and cantholysis<sup>4</sup> (LCC)**

#### Primary indications

- Decreased visual acuity
- Intraocular pressure > 40 mm Hg
- Proptosis

#### Secondary indications

- Afferent pupillary defect
- Cherry red macula
- Ophthalmoplegia
- Nerve head pallor
- Eye pain

#### Contraindications

- Globe rupture

marizes the relevant indications and contraindications for LCC.<sup>4</sup>

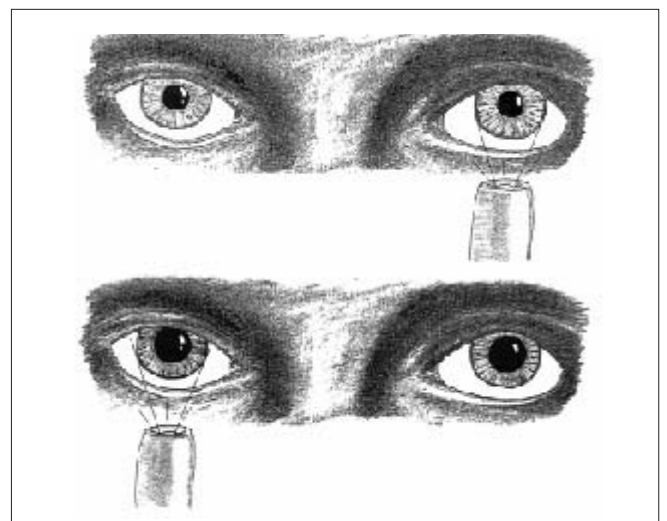
### Indications for LCC

An elevation in IOP is evidenced by either a tonometry reading greater than 40 mm Hg or a marked difference in globe compressibility on palpation over a closed lid.<sup>2</sup> Tonometry, either with a tonopen or a shiotsz tonometer is the preferred method of assessing IOP, however this instrument may not always be readily available. Of note, tonometry and globe palpation are contraindicated in patients with an open globe injury.<sup>5</sup>

In unconscious or uncooperative patients with periorbital trauma, the presence of an IOP >40 mm Hg is sufficient to proceed with LCC.<sup>6</sup> If tonometry is not available but a marked globe compressibility difference exists, an LCC should be performed if there is obvious proptosis or the presence of secondary indications (Table 1). In the presence of severe maxillofacial injury, proptosis may be difficult to discern and swelling may hinder examination of the globe.

The afferent pupillary defect, or Marcus Gunn pupil, is 1 of 5 secondary indications. It indicates a unilateral lesion of the retina or the optic nerve, and can be demonstrated by the swinging flashlight test (Fig. 2). With an intact afferent pupillary system, shining a light in either eye causes rapid bilateral pupil constriction. If an afferent pupillary defect exists, both pupils dilate when the defective eye is illuminated and both constrict when the normal eye is illuminated.<sup>7</sup> This occurs because afferent signals conducted through cranial nerve II from the affected side are compromised, while efferent signals conducted down cranial nerve III (after stimulation of the unaffected eye), are not.<sup>8</sup>

Complete lesions of the oculomotor nerve produce oph-



**Fig. 2. Afferent pupillary defect of the patient's right eye.**

thalmoplegia and diplopia. In such cases, the affected eye looks laterally (external strabismus) and downwards because the extraocular muscles supplied by the third cranial nerve are paralyzed, but the lateral rectus and superior oblique remain functional. This is often referred to as a “down and out eye.” Ptosis, the drooping of the upper eyelid secondary to the paralysis of the levator palpebrae superioris, is also seen. Visual accommodation is typically compromised, and the pupillary sphincter may be paralyzed, resulting in a non-reactive dilated pupil.

Eye pain is another of the secondary indications for an LCC. Assessment, as with the evaluation of visual acuity, requires an awake patient who is able to communicate the perception of eye pain or a headache.

In the setting of trauma with suspected IOP, a cherry red macula or nerve head pallor suggest the need for LCC. However, these findings are subjective and less reliable than the findings previously listed. If primary indications (Table 1) mandate emergent LCC, the presence of secondary findings emphasizes the urgency of this procedure. If only secondary indications are present, it may not be appropriate to perform the procedure until seeking emergent ophthalmologic consultation.

### The procedure

Table 2 outlines the equipment required to perform an LCC. This equipment is often available on a standard ED suture tray.

**Step 1:** Clear debris and secretions away from around the lateral canthus and prep the surrounding skin with normal saline to improve visualization and reduce the risk of infection. If the patient is awake, an assistant should stabilize the head and maintain cervical immobilization. Although LCC is no more painful than laceration repair, it can be visually disturbing for the patient, especially if confused.

**Step 2:** Inject 1–2 cc of 1%–2% lidocaine with epinephrine into the lateral canthus. This provides both pain relief and hemostasis at the time of devascularization and incision (Figs. 3 and 4).

**Table 2. Equipment required to perform LCC**

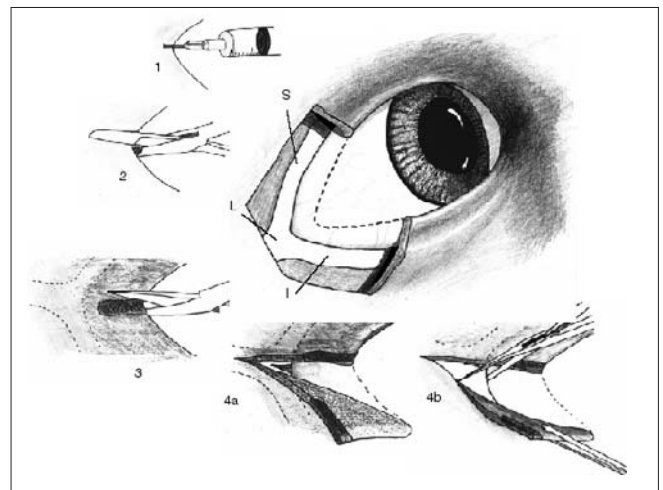
1. Lidocaine with epinephrine
2. Syringe with 25-gauge 5/8 needle
3. Hemostat or needle driver
4. Iris or suture scissors
5. Forceps

**Step 3:** Apply a hemostat or needle driver from the lateral canthus towards the bony orbit to devascularize the area for 30–90 seconds (Figs. 3 and 5).

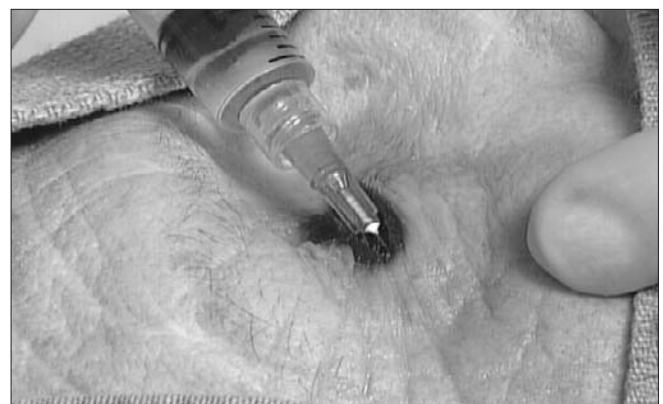**Step 4:** Remove the devascularizing instrument and cut the demarcated area laterally 1–2 cm in length (Figs. 3 and 6).

**Step 5:** Using the forceps, pull the lower lid down to visualize the inferior lateral canthal tendon and cut through this tendon. (Figs. 3 and 7).

**Step 6:** After the inferior canthal tendon has been cut, reassess intraocular pressure with a tonometer. If IOP remains >40 mm Hg, then decompression is inadequate. Lift the upper lid and also sever the superior lateral canthal tendon.



**Fig. 3. Anatomy of the lateral canthus. I = inferior canthal tendon. L = lateral canthal tendon. S = superior canthal tendon. Stages of the procedure: 1: Infiltration of the local anaesthetic. 2: Devascularization. 3: Cut through skin and lateral canthus. 4a: Expose the inferiolateral canthal tendon. 4b: Cut inferior canthal tendon.**



**Fig. 4. Anesthetizing the lateral canthus. Note: This is a cadaveric picture and proptosis does not exist. After death, the eyes recess naturally into the orbit.**



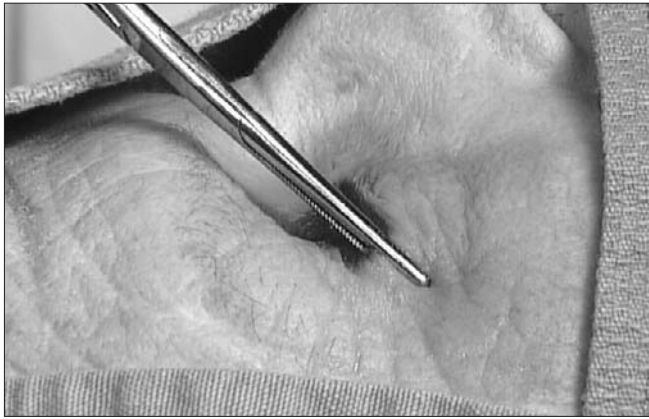

Fig. 5. Devascularizing the lateral canthus

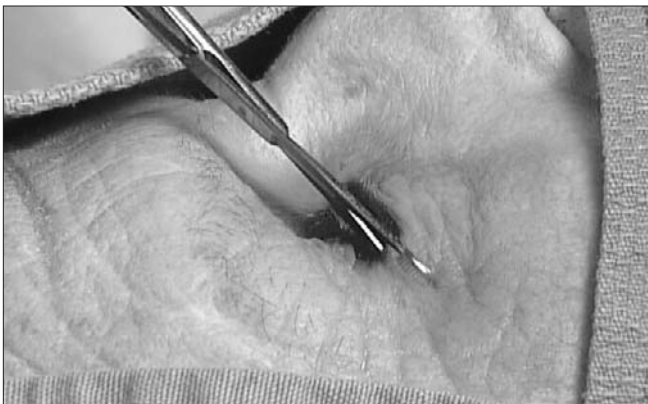

Fig. 6. Incising the lateral canthus

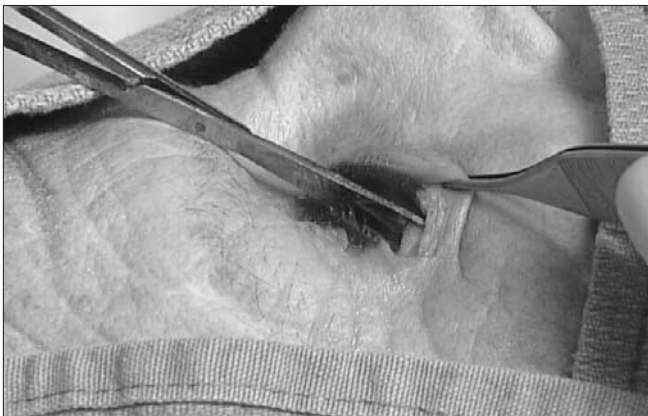

Fig. 7. Cutting the inferior lateral canthal tendon

### Complications

As with any other minor surgical procedure, there is a risk of infection and hemorrhage, as well as mechanical injury of the globe. These complications are rare and respond to therapy, while prolonged retinal ischemia does not. Lateral canthotomy wounds heal well without suturing or significant scarring.<sup>9</sup>

### Consultation and follow-up

Ideally, an ophthalmologist would be present to assess patients with orbital trauma when they present to the ED, but this is rarely feasible. Whenever possible, in cases of suspected retinal ischemia, emergency physicians should rapidly involve ophthalmology consultants. As is the case with heart or brain ischemia, more rapid reperfusion leads to better outcomes. The retina may tolerate approximately 2 hours of ischemia before the potential to recover normal vision is lost,<sup>10</sup> but this figure is based on expert opinion only, and is likely variable. Whether or not an ophthalmologist is available at the time of LCC, any patient who has had an LCC in the ED requires ophthalmology follow-up and ongoing treatment.

### Summary

Traumatic retrobulbar hematoma is a serious complication that should be recognized in the ED. LCC is a simple, vision-saving procedure that can be performed by emergency physicians.

**Competing interests:** None declared.

**Acknowledgements:** Illustrations by Dr. Daniel W. Howes.

### References

1. Linden JA, Renner GS. Trauma to the globe. *Emerg Med Clin North Am* 1995;13(3):581-605.
2. Samples JR, Hedges JR. Ophthalmologic procedures. In: Roberts JR, Hedges JR, editors. *Clinical procedures in emergency medicine*. 3rd ed. Philadelphia: W.B. Saunders Co; 1998. p. 1089-119.
3. Baker SM, Hurwitz JJ. Sports and industrial ophthalmology: management of orbital and ocular adnexal trauma. *Ophthalmol Clin North Am* 1999;12(3):435-55.
4. Crumpton KL, Shockley LW. Ocular trauma: a quick, illustrated guide to treatment, triage, and medicolegal implications. *Emerg Med Rep* 1997;18(23):223-34.
5. Keeney AH. *Ocular examination*. St Louis: CV Mosby; 1970. p. 120-3.
6. Lubeck D. Penetrating ocular injuries. *Emerg Med Clin North Am* 1988;6(1):127-46.
7. Brunette DD, Ghezzi K, Renner GS: Ophthalmologic disorders. In: Rosen P, Barkin R, Danzl DF, Hockberger RS, Ling LJ, Markovchick V, et al, editors. *Emergency medicine: concepts and clinical practice*. 4th ed. St. Louis: Mosby-Year Book Inc.; 1998. p. 2700.
8. Wilson-Pauwels L, Akesson EJ, Stewart PA. Cranial nerves. Toronto: BC Decker Inc.; 1988. p. 10-39.
9. Knoop K, Trott A. Ophthalmological procedures in the emergency department: immediate sight-saving procedures. *Acad Emerg Med* 1994;1:408-12.
10. Larsen M, Wieslander S. Acute orbital compartment syndrome after lateral blow-out fracture effectively relieved by lateral cantholysis. *Acta Ophthalmol Scand* 1999;77:232-3.

**Correspondence to:** Dr. Gord McInnes, Department of Emergency Medicine, Kingston General Hospital, 76 Stuart St., Kingston ON K7L 2V7; gordmcinnes@home.com