

Minimally Invasive versus Open Approach for Cervical Laminoforaminotomy

Mark J. Winder, Kenneth C. Thomas

ABSTRACT: Background: Minimally invasive posterior cervical foraminotomy for radicular symptoms has become more prevalent. The reported experience with microscopic tubular assisted posterior cervical laminoforaminotomy (MTPF) for the treatment of radicular pain is lacking. Tubular assisted techniques have been considered to offer significant benefit, over open procedures, in terms of minimizing tissue damage, operative time, blood loss, analgesic requirements and length of hospital stay. We hypothesized that MTPF reduces post-operative analgesic requirements and length of hospital stay over the traditional open laminoforaminotomy, with no difference in complication rates and, secondly, that MTPF is comparable to endoscopic posterior foraminotomy (EPF). **Methods:** We conducted a retrospective review of 107 patients who underwent posterior cervical laminoforaminotomy for radicular pain between 1999 and 2009. Patient demographics, intra-operative parameters, length of hospitalization, post-operative analgesic use, complications and short-term neurological outcome were compared between groups. **Results:** Between 1999 and 2009, a total of 107 patients were identified to have undergone a cervical foraminotomy. An open approach was used in 65 patients, while 42 underwent MTPF. Operative time and complications were comparable between groups. Significant differences favoring MTPF were observed in operative blood loss, post-operative analgesic use and length of hospital stay ($p < 0.001$). All results were comparable to previous reports utilizing EPF. **Conclusions:** MTPF for the treatment of cervical radiculopathy significantly reduces blood loss, post-operative analgesic use and length of hospital stay compared to the standard open approach. Operative time and complication rates were comparable between both techniques, whilst MTPF offered similar results compared to EPF.

RÉSUMÉ: Approche minimalement effractive versus approche ouverte pour la laminoforaminotomie cervicale. Contexte : La foraminotomie cervicale postérieure minimalement effractive pour traiter des symptômes radiculaires est devenue plus courante. Il existe peu de publications rapportant l'expérience de laminoforaminotomie cervicale postérieure sous microscopie, avec insertion d'écarteur tubulaire (FPMT), pour le traitement de la douleur radiculaire. Les techniques avec écarteur tubulaire sont considérées comme offrant des bénéfices significatifs par rapport aux chirurgies ouvertes, parce qu'elles minimisent le dommage tissulaire, le temps opératoire, la perte de sang, les besoins analgésiques et le séjour hospitalier. Nous avons émis l'hypothèse que la FPMT diminue les besoins en analgésiques après la chirurgie et la durée du séjour hospitalier par rapport à la laminoforaminotomie ouverte traditionnelle, qu'il n'existe pas de différence quant au taux de complications et que la FPMT est comparable à la foraminotomie postérieure endoscopique (FPE). **Méthode :** Nous avons effectué une revue rétrospective des dossiers de 107 patients qui ont subi une laminoforaminotomie cervicale postérieure pour des douleurs radiculaires entre 1999 et 2009. Nous avons comparé les données démographiques des patients, les paramètres intra-opératoires, la durée d'hospitalisation, l'utilisation d'analgésiques en période postopératoire, les complications et l'issue neurologique à court terme entre les deux groupes. **Résultats :** Nous avons identifié 107 patients qui ont subi une foraminotomie cervicale entre 1999 et 2009. Une approche ouverte a été utilisée chez 65 patients et 42 ont subi une FPMT. Le temps opératoire et les complications étaient comparables dans les deux groupes. Nous avons observé des différences significatives en faveur de la FPMT quant à la perte de sang opératoire, l'utilisation d'analgésiques dans la période postopératoire et la durée d'hospitalisation ($p < 0,001$). Tous les résultats étaient comparables à ceux des études rapportées antérieurement concernant la FPE. **Conclusions :** La FPMT pour traiter la radiculopathie cervicale diminue significativement la perte sanguine, l'utilisation d'analgésiques en période postopératoire et la durée d'hospitalisation par rapport à l'approche ouverte standard. Le temps opératoire et le taux de complications étaient comparables, alors que les résultats des deux techniques étaient identiques.

Can J Neurol Sci. 2011; 38: 262-267

The surgical management for cervical radiculopathy utilizing a posterior approach originated over 65 years ago and has gradually evolved¹⁻⁵. The limitations of the posterior approach for treatment of cervical myelopathy related to canal stenosis was evident and subsequently the anterior approach, originally pioneered by Smith and Robinson^{6,7} and modified by Cloward⁸, offered a viable alternative for myelopathic symptoms. Extending the concept, the anterior approach offered an effective treatment for cervical radiculopathy and has since been extensively utilized. Multiple modifications of the anterior approach including allografts, cages, fixed and dynamic plating have led many to consider it to be the gold standard for cervical

disc disease. Yet with evolving imaging modalities, a definitive focus on preservation of normal biomechanics and the development of minimally invasive approaches, there has been a

From the Department of Neurosurgery (MJW), St. Vincent's Hospital, Sydney, Australia; Department of Orthopedic Surgery (KCT), Department of Neurosurgery (MJW), Foothills Hospital, University of Calgary, Calgary, Alberta, Canada.

RECEIVED JULY 26, 2010. FINAL REVISIONS SUBMITTED SEPTEMBER 27, 2010.
Correspondence to: Mark J. Winder, Level 7, St Vincent's Clinic, 430 Victoria St, Darlinghurst, NSW, Australia.

shift in recognition as to the most appropriate indications for either an anterior or posterior approach.

It has been appreciated that anterior cervical approaches culminating in fusion result in abnormal spinal motion thus placing higher shear strains on adjacent levels, increasing adjacent intra-discal pressures and leading to greater risk of adjacent level degenerative disease⁹⁻¹⁵. Reports of adjacent segment disease range from 3-8% per year¹⁶⁻¹⁹ with a reported incidence of 25.6% at ten years¹⁶. It is uncertain whether this may simply represent the natural history of cervical disc degeneration or is a direct result of cervical fusion and the associated altered biomechanics. Short-term results following the introduction of cervical disc arthroplasty seem to suggest preservation of motion segments with trends towards reduced adjacent segment surgeries²⁰⁻²³.

Despite anterior cervical exposure being considered a relatively straightforward procedure, complications may include tracheal and esophageal penetration, vessel injury including the carotid, vertebral and internal jugular vein, neural injury of the sympathetic chain, cervical nerve roots and recurrent laryngeal nerve²⁴. The incidence of vocal fold paralysis has been reported as high as 5%, with the incidence of post-operative dysphagia reported as high as 49.3% with a higher preponderance in females²⁵.

The posterior laminoforaminotomy offers an alternative treatment for cervical radiculopathy with maintenance of motion preservation. It does not require additional stabilization or implantation of a prosthesis and as such adjacent level disease has a minimal incidence²⁶⁻²⁸. It offers excellent access to lateral disc herniations and bony foraminal compromise secondary to cervical spondylosis²⁹⁻³⁴.

The initial posterior laminoforaminotomy was devised as a midline approach, utilizing a sub-periosteal laminae dissection to minimize bleeding. However, the advent of microsurgical and endoscopic techniques has now modified the access, using a para-median incision with placement of tubular retractors. There are several reports of endoscopic cervical posterior foraminotomies^{29,30,35-37}, yet to our knowledge there is only a single study detailing results of MIS microscopic approaches³⁸. The advantages of the minimally invasive approaches include smaller incisions, preservation of paraspinal muscle with minimal retraction, a direct surgical corridor to the offending region with comparable or better visualization, combined with the subjective patient perception that they are receiving the best available care. The MIS approaches are complemented with shorter hospital stays, including day surgery, faster recovery times and reduced blood loss^{29,30,35,37,39,40}, post-operative pain and analgesic requirements³⁸.

The primary aim of this study was to determine any appreciable differences between the use of microscopic tubular assisted posterior foraminotomies (MTPF) compared with traditional open foraminotomies. As a secondary outcome we compared results of MTPF to the reported results of micro-endoscopic posterior foraminotomies.

METHODS

A retrospective review of all cervical cases over the past 11 years was undertaken. Inclusion criteria included one, two or three level foraminotomies performed using either open or

MTPF techniques. Any cases where a hemi-laminectomy or more extensive procedure was performed were excluded. Repeat cases, same or separate level were included. Our Spinal Unit included nine surgeons, four orthopedic and five neurosurgical, all of whom performed the operations. Initially, all surgeons performed the operation using the traditional open technique, however, over the last eight years, five surgeons have altered their technique and now perform the operation as a minimally invasive technique as described below. The open technique is as described elsewhere and was always performed under microscopic vision.

Outcome variables assessed included operative time, complications, blood loss, length of hospital stay, recovery and discharge analgesic requirements. All analgesic requirements were normalized based on dosage equivalence^{41,42}.

Surgical Technique

Following intubation the patients were placed in a head fixator (Mayfield or Sugita) and positioned prone on the operating table. The neck was placed in a flexed position with the head of the bed slightly elevated.

The skin was marked and a lateral x-ray taken to ensure the trajectory for the correct level. A 1.5 cm incision was performed on the affected side (midline if bilateral foraminotomies), the paraspinal fascia incised and a blunt dilator passed to the affected laminae and lateral masses. Gentle soft tissue dissection was performed, allowing placement of the tubular dilators and tubular port. A confirmatory lateral x-ray was always taken prior to definitive bony exposure. The overlying laminae and interlaminae space were identified using a combination of monopolar and bipolar cautery under microscopic vision. A small laminotomy was performed using a high speed burr. This allowed lateral exposure of the spinal cord at the origin of the affected nerve root and a formal rhizolysis was completed using the high speed burr and Kerrison punches. In the case of soft lateral disc herniation, the underlying disc was visualized and a focal discectomy performed to ensure adequate decompression. Following hemostasis, the tubular retractor was removed under microscopic vision and the wound closed.

Table 1: Patient demographic data

Parameter	Open (n=65)	MTPF (n=42)
Mean Age (yr)	51.2	49.8
Gender (% men)	60.0	66.7
Smokers (%)	26.2	19.0
Workers Compensation (%)	10.8	4.8
Number of Surgical Levels	86	51
Complications (N)	7	3
Discharge same day (%)	9.2%	61.9%

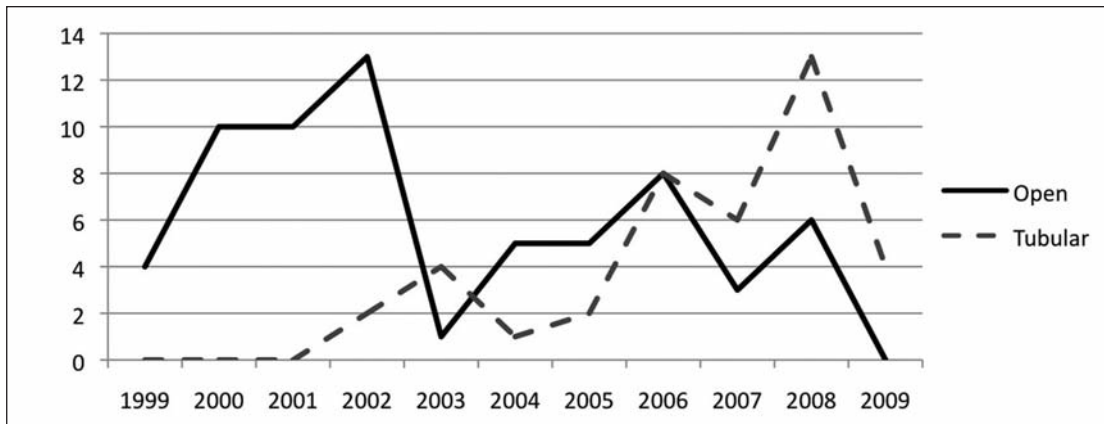


Figure 1: Frequency of Operations

RESULTS

A review of all cervical cases between 1999 and 2009 identified 107 foraminotomies: 65 open and 42 using MTPF. The results were stratified according to the approach utilized. The patient demographic data is presented in Table 1.

The frequency of operations and operative levels are demonstrated in Figures 1 and 2. Outcome variables are summarized in Table 2. There was a trend over time towards utilization of MTPF, since inception in 2002. The most frequent operative levels were C5/6 and C6/7.

The mean operative times for open and MTPF assisted groups were 103.3 and 100.7 minutes respectively, with no statistical or clinical differences. The mean operative time for each procedure showed minimal change over the duration of the study. A minor

decrease was seen for both procedures, but no significance detected. Mean operative time for single level, unilateral procedures was 93.8 and 92.2 minutes ($p=0.64$) for open and MTPF respectively.

Mean blood loss was 233 ml for the open and 96 ml for the MTPF group, which was statistically significant ($p<0.0001$). There were 11 bilateral procedures, 3 three level and 8 two level operations in the open group as compared to 3 bilateral, 1 three level and 2 two level cases in the MTPF group. Assessment of blood loss in single level cases revealed a mean blood loss of 210 ml and 78 ml ($p<0.001$) for open and MTPF groups respectively. The average length of hospital stay proved to be significantly shorter for MTPF procedures compared to open: 26.9 and 58.6 hours ($p= <0.001$). Sixty-two percent of patients undergoing

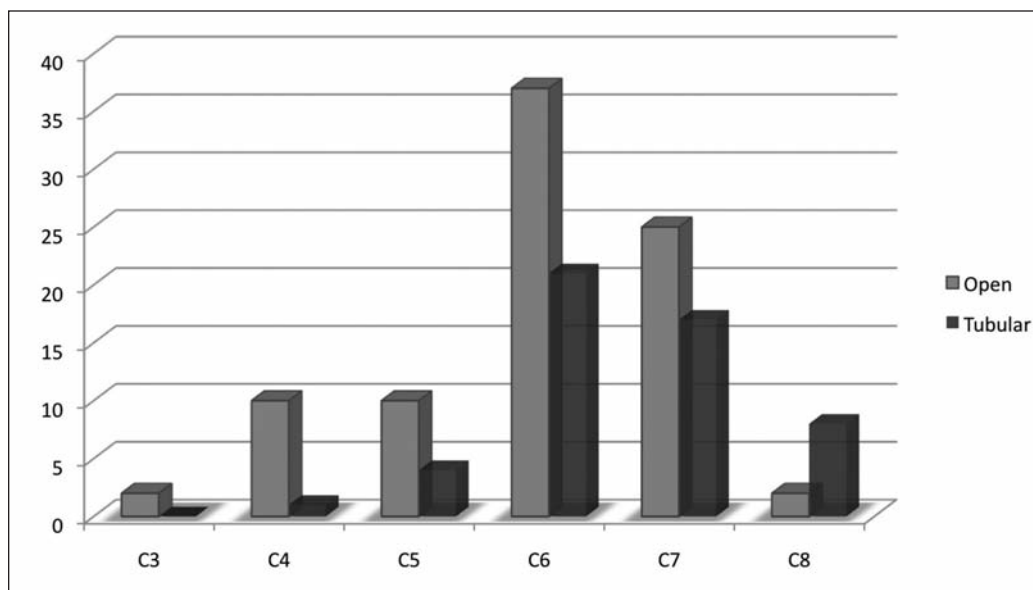


Figure 2: Frequency of Operative Levels

Table 2: Outcome measures

Outcome Variable		N	Mean	95% CI Lower	Upper	p
Blood Loss (mL)	Open	65	233.20	90.84	183.33	<0.001
	MTPF	42	96.10			
Operative Time (min)	Open	65	103.25	-9.97	14.99	0.69
	MTPF	42	100.74			
Recovery Room Analgesia (SU)	Open	65	26.57	15.21	20.35	<0.001
	MTPF	42	8.79			
Discharge Analgesia (SU)	Open	65	9.88	2.02	5.73	<0.001
	MTPF	42	6.01			
LOHS* (Hrs)	Open	65	58.60	11.54	16.80	<0.001
	MTPF	42	26.86			

*LOHS: Length of Hospital Stay; SU: Standardized Units for Opioid Equivalent Doses^{15,41}.

MTPF operations were discharged the day of procedure as compared to 9.2% for the open group.

Recovery room analgesia was significantly less for the tubular assisted group, 8.8 compared to 26.6 ($p < 0.001$). This was also true for discharge analgesic requirements, 6.0 and 9.9 ($p < 0.001$) for tubular and open groups respectively. Nineteen patients (31%) in the open group compared to 4 (9.5%) in the MTPF groups complained of moderate to severe post-operative neck discomfort prior to discharge. Of these, all post-operative discomfort was in multilevel operations in the MTPF group, whereas in the open group 11 were multilevel and 8 were single level.

Complications occurred in seven (10.8%) and three (7.1%) of the open and tubular groups respectively, with Chi square analysis showing no significance.

In an effort to establish comparative homogenous cohorts, we subsequently analyzed the data to include single level operations only (43 and 32 for open and MTPF respectively). We found no changes to statistical significance for any of the outcome variables when compared to the former analysis, which included multilevel operations.

DISCUSSION

The surgical management for cervical radiculopathy has been used for many decades with proven efficacy and a low incidence of serious complications^{1,18,26,27,31,33-35,38,40,43-46}. The surgical procedure of choice, utilizing either a posterior or anterior approach, is one of debate. Despite anterior cervical discectomy and fusion being considered by many as the gold standard, there is a strong and competing belief towards maintenance of normal spine biomechanics, favoring the posterior approach. However posterior approaches, despite their advantages, are limited to lateral disc herniations and foraminal stenosis whilst open posterior procedures are clearly associated with post-operative neck discomfort. When indicated, the posterior laminoforaminotomy yields equivalent clinical outcomes when compared to anterior approaches in the treatment of radiculopathy, eliminating the need for short segment fusion with evidence

suggesting a decrease in adjacent segment disease with this paradigm^{26-28,45}.

There is a definitive trend towards minimally invasive spine surgery which has led the way towards tubular assisted, either endoscopic or microscopic, posterior foraminotomies. This approach has been shown to have good success with several large case series reporting reduced blood loss, post-operative pain and analgesic requirements, shorter hospital stays, faster recovery time, all leading to excellent clinical results^{26,29-31,35-40,43,44}. The majority of these studies utilized endoscopic procedures. To our knowledge there appears to be only one study comparing open to microscopic tubular assisted approaches for cervical foraminotomies³⁸. This prospective randomized trial, albeit with small numbers, showed reduced analgesic requirements and hospital stays for the MTPF group with equivocal clinical improvements.

In this study we compared open foraminotomies to MTPF. The most common operative levels were C5/6 and C6/7. There was an increasing prevalence of cervical foraminotomies utilizing the MTPF compared to open procedures throughout the study time interval.

There were no significant differences in operative time or complications between the two surgical approaches, yet there were significant differences in blood loss, recovery and discharge analgesia and length of hospital stay.

Despite there being no statistical differences in the complication rate, 31.5% of open procedures were associated with early post-operative neck pain, compared to 9.5%. All of these cases in the tubular group were associated with either a bilateral or a multilevel operation, whilst 42% were single level operations in the open group. This fact mimics the significance of reduced recovery and discharge analgesic requirements seen in the MTPF group, further supporting the results seen in other series^{26,29-31,43,44}.

Length of hospital stay was significantly reduced in the MTPF group ($p < 0.001$), corroborating data from previous studies^{26,29,30,33,35-40,43}. Given that minimally invasive tubular foraminotomies have been shown to at least offer equivocal

clinical results, the fiscal implications inherent to a reduction in length of hospital stay, may become an important consideration to clinical practice in the climate of burgeoning health care costs and hospital waiting periods.

Comparison of results with other MIS endoscopic published studies

The experiences of endoscopic posterior foraminotomy (EPF) report greater than 95% patient satisfaction with 1-3% complications, suggesting it is comparable to the open procedures^{26,29,34,35,40}. Comparing MTPF to EPF highlights similar findings; Fessler et al reported operative times of 115 minutes and 171 minutes for EPF and open respectively, with hospital stay averaging at 20 hours and 68 hours respectively³⁵. Our results of 26.9 hrs and 58.1 hrs for MTPF versus open are comparable to that reported in EPF, yet significantly shorter than those reported by Kyoung-Tae et al³⁸. This latter discrepancy is likely due to hospital post-operative care protocols. Adamson's series reported 90% patients being discharged the same day compared to 62% in our series²⁹. Complication rates were comparable between EPF and MTPF averaging 1 to 4%^{29,35,38}. Reviewing the available data, there appears to be little difference between EPF and MTPF.

This study is limited by the fact that it is a retrospective review with moderate numbers. It does not take into account the learning curves associated with new procedures, nor the experience of individual surgeons performing the operations. The significance of blood loss is not clinically relevant as it refers to an estimate from patient's charts rather than defined criteria for measurement. Further there is little clinical significance of 100 ml versus 200 ml of blood loss and it really only serves to add support to a surgical technique. A final confounder relates to patient expectation: if a patient is under the impression that they are having a day procedure they will often expect to leave the same day. This is likely true for both open and MTPF procedures, yet there seems to be more conviction for same day procedures with MTPF, which may vary between units. This paper highlights an increasing trend towards the use of the minimally invasive microscopic tubular assisted posterior foraminotomies. Our results concur with those of other published papers, supporting the notion that minimally invasive tubular assisted procedures are an efficacious option for the treatment of cervical radiculopathy, reducing operative blood loss, analgesic use and length of hospital stay, whilst being associated with a low rate of complications.

CONCLUSION

The advent of adequate retraction systems has enabled minimally invasive posterior cervical foraminotomies to be performed. Given the tubular ports, surgeons are afforded the options of endoscopic or microscopic visualization. Our results suggest that MTPF is comparable to EPF and enables shorter hospital stays, minimizes analgesic requirements, with equivocal complication rates when compared to open procedures performed.

REFERENCES

- Spurling RG, Scoville WB. Lateral rupture of the cervical intervertebral disc. A common cause of shoulder and arm pain. *Surg Gynecol Obstet.* 1944;798:350-8.
- Frykholm R. Cervical root compression resulting from disc degeneration and root sleeve fibrosis. *Acta Chir Scand.* 1951; 160:S1-149.
- Scoville WB, Dohrman GJ, Corkill G. Late results of cervical disc surgery. *J Neurosurg.* 1976;45:203-10.
- Murphey F, Simmons JC, Brunson B. Surgical treatment of laterally ruptured cervical disc. Review of 648 cases, 1939 to 1972. *J Neurosurg.* 1973 Jun;38(6):679-83.
- Semmes RE, Murphey F. Syndrome of unilateral rupture of the sixth intervertebral disk, with compression of the seventh cervical nerve root. Report of four cases with symptoms simulating coronary disease. *JAMA.* 1943;121:1209-14.
- Robinson R, Smith G. Anterolateral cervical disc removal and interbody for cervical disc syndrome. *Bull John Hopkins Hosp.* 1955;96:223.
- Smith GW, Robinson RA. The treatment of certain cervical-spine disorders by anterior removal of the intervertebral disc and interbody fusion. *J Bone Joint Surg Am.* 1958 Jun;40-A(3): 607-24.
- Cloward R. The anterior approach for removal of ruptured cervical discs. *J Neurosurg.* 1958;15:602-17.
- Clements DH, O'Leary PF. Anterior cervical discectomy and fusion. *Spine (Phila Pa 1976).* 1990 Oct;15(10):1023-5.
- Bertalanffy H, Eggert HR. Clinical long-term results of anterior discectomy without fusion for treatment of cervical radiculopathy and myelopathy. A follow-up of 164 cases. *Acta Neurochir (Wien).* 1988;90(3-4):127-35.
- Hilibrand AS, Yoo JU, Carlson GD, Bohlman HH. The success of anterior cervical arthrodesis adjacent to a previous fusion. *Spine (Phila Pa 1976).* 1997 Jul 15;22(14):1574-9.
- Hunter LY, Braunstein EM, Bailey RW. Radiographic changes following anterior cervical fusion. *Spine (Phila Pa 1976).* 1980 Sep-Oct;5(5):399-401.
- Braunstein EM, Hunter LY, Bailey RW. Long term radiographic changes following anterior cervical fusion. *Clin Radiol.* 1980 Mar;31(2):201-3.
- Wu W, Thuomas KA, Hedlund R, Leszniewski W, Vavruch L. Degenerative changes following anterior cervical discectomy and fusion evaluated by fast spin-echo MR imaging. *Acta Radiol.* 1996 Sep;37(5):614-7.
- Pospiech J, Stolke D, Wilke HJ, Claes LE. Intradiscal pressure recordings in the cervical spine. *Neurosurgery.* 1999 Feb;44(2): 379-84; discussion 384-5.
- Hilibrand AS, Carlson GD, Palumbo MA, Jones PK, Bohlman HH. Radiculopathy and myelopathy at segments adjacent to the site of a previous anterior cervical arthrodesis. *J Bone Joint Surg Am.* 1999 Apr;81(4):519-28.
- Ishihara H, Kanamori M, Kawaguchi Y, Nakamura H, Kimura T. Adjacent segment disease after anterior cervical interbody fusion. *Spine J.* 2004 Nov-Dec;4(6):624-8.
- Robertson JT, Papadopoulos SM, Traynelis VC. Assessment of adjacent-segment disease in patients treated with cervical fusion or arthroplasty: a prospective 2-year study. *J Neurosurg Spine.* 2005 Dec;3(6):417-23.
- Yue WM, Brodner W, Highland TR. Long-term results after anterior cervical discectomy and fusion with allograft and plating: a 5- to 11-year radiologic and clinical follow-up study. *Spine (Phila Pa 1976).* 2005 Oct 1;30(19):2138-44.
- Mummaneni PV, Burkus JK, Haid RW, Traynelis VC, Zdeblick TA. Clinical and radiographic analysis of cervical disc arthroplasty compared with allograft fusion: a randomized controlled clinical trial. *J Neurosurg Spine.* 2007 Mar;6(3):198-209.
- Mummaneni PV, Robinson JC, Haid RW, Jr. Cervical arthroplasty with the PRESTIGE LP cervical disc. *Neurosurgery.* 2007 Apr;60(4 Suppl 2):310-4; discussion 314-5.
- Sasso RC, Smucker JD, Hacker RJ, Heller JG. Artificial disc versus fusion: a prospective, randomized study with 2-year follow-up on 99 patients. *Spine (Phila Pa 1976).* 2007 Dec 15;32(26):2933-40; discussion 2941-2.
- Sasso RC, Smucker JD, Hacker RJ, Heller JG. Clinical outcomes of BRYAN cervical disc arthroplasty: a prospective, randomized, controlled, multicenter trial with 24-month follow-up. *J Spinal Disord Tech.* 2007 Oct;20(7):481-91.

24. Morpeth JF, Williams MF. Vocal fold paralysis after anterior cervical discectomy and fusion. *Laryngoscope*. 2000 Jan;110(1):43-6.
25. Papaverio L, Heese O, Klotz-Regener V, Buchalla R, Schroder F, Westphal M. The impact of esophagus retraction on early dysphagia after anterior cervical surgery: does a correlation exist? *Spine (Phila Pa 1976)*. 2007 May 1;32(10):1089-93.
26. Jagannathan J, Sherman JH, Szabo T, Shaffrey CI, Jane JA. The posterior cervical foraminotomy in the treatment of cervical disc/osteophyte disease: a single-surgeon experience with a minimum of 5 years' clinical and radiographic follow-up. *J Neurosurg Spine*. 2009 Apr;10(4):347-56.
27. Clarke MJ, Ecker RD, Krauss WE, McClelland RL, Dekutoski MB. Same-segment and adjacent-segment disease following posterior cervical foraminotomy. *J Neurosurg Spine*. 2007 Jan;6(1):5-9.
28. McCormick PC. The adjacent segment. *J Neurosurg Spine*. 2007 Jan;6(1):1-4; discussion
29. Adamson TE. Microendoscopic posterior cervical laminoforaminotomy for unilateral radiculopathy: results of a new technique in 100 cases. *J Neurosurg*. 2001 Jul;95 Suppl 1:51-7.
30. Coric D, Adamson T. Minimally invasive cervical microendoscopic laminoforaminotomy. *Neurosurg Focus*. 2008;25(2):E2.
31. Epstein NE. A review of laminoforaminotomy for the management of lateral and foraminal cervical disc herniations or spurs. *Surg Neurol*. 2002 Apr;57(4):226-33; discussion 233-4.
32. Epstein NE. Minimally invasive/endoscopic vs "open" posterior cervical laminoforaminotomy: do the risks outweigh the benefits? *Surg Neurol*. 2009 Mar;71(3):330-1.
33. Parker WD. Cervical laminoforaminotomy. *J Neurosurg*. 2002 Mar;96 Suppl 2:254; author reply -5.
34. Henderson CM, Hennessy RG, Shuey HM, Jr., Shackelford EG. Posterior-lateral foraminotomy as an exclusive operative technique for cervical radiculopathy: a review of 846 consecutively operated cases. *Neurosurgery*. 1983 Nov;13(5):504-12.
35. Fessler RG, Khoo LT. Minimally invasive cervical microendoscopic foraminotomy: an initial clinical experience. *Neurosurgery*. 2002 Nov;51(5 Suppl):S37-45.
36. Ruetten S, Komp M, Merk H, Godolias G. A new full-endoscopic technique for cervical posterior foraminotomy in the treatment of lateral disc herniations using 6.9-mm endoscopes: prospective 2-year results of 87 patients. *Minim Invasive Neurosurg*. 2007 Aug;50(4):219-26.
37. Ruetten S, Komp M, Merk H, Godolias G. Full-endoscopic cervical posterior foraminotomy for the operation of lateral disc herniations using 5.9-mm endoscopes: a prospective, randomized, controlled study. *Spine (Phila Pa 1976)*. 2008 Apr 20;33(9):940-8.
38. Kyoung-Tae K, Young-Baeg K. Comparison between open procedure and tubular retractor assisted procedure for cervical radiculopathy: results of a randomized controlled study. *J Korean Med Sci*. 2009;24:649-53.
39. Adamson TE. The impact of minimally invasive cervical spine surgery. Invited submission from the Joint Section Meeting on Disorders of the Spine and Peripheral Nerves, March 2004. *J Neurosurg Spine*. 2004 Jul;1(1):43-6.
40. Gala VC, O'Toole JE, Voyadzis JM, Fessler RG. Posterior minimally invasive approaches for the cervical spine. *Orthop Clin North Am*. 2007 Jul;38(3):339-49; abstract v.
41. Hanks G, Cherny N, Fallon M. Opioid analgesic therapy. *Oxford Textbook of Palliative Medicine*. Oxford: Oxford University Press; 2004. p. 316-41.
42. Shaheen PE, Walsh D, Lasheen W, Davis MP, Lagman RL. Opioid equianalgesic tables: are they all equally dangerous? *J Pain Symptom Manage*. 2009 Sep;38(3):409-17.
43. Caglar YS, Bozkurt M, Kahilogullari G, et al. Keyhole approach for posterior cervical discectomy: experience on 84 patients. *Minim Invasive Neurosurg*. 2007 Feb;50(1):7-11.
44. Heary RF, Ryken T, Matz PG, et al. Cervical laminoforaminotomy for the treatment of cervical degenerative radiculopathy. *J Neurosurg Spine*. 2009;11(Aug):198-202.
45. Russell SM, Benjamin V. Posterior surgical approach to the cervical neural foramen for intervertebral disc disease. *Neurosurgery*. 2004 Mar;54(3):662-5; discussion 665-6.
46. Shiraishi T. A new technique for exposure of the cervical spine laminae. Technical note. *J Neurosurg*. 2002 Jan;96 Suppl 1:122-6.