

Brief Report

Cite this article: Park J, Brekke DR, and Bratincsak A (2022) Self-limited myocarditis presenting with chest pain and ST segment elevation in adolescents after vaccination with the BNT162b2 mRNA vaccine. *Cardiology in the Young* **32**: 146–149. doi: [10.1017/S1047951121002547](https://doi.org/10.1017/S1047951121002547)

Received: 28 May 2021
Revised: 2 June 2021
Accepted: 6 June 2021
First published online: 28 June 2021

Keywords:

myocarditis; ST segment elevation; troponin; COVID-19; vaccine

Author for correspondence:

Andras Bratincsak, MD, Department of Pediatrics, John A. Burns School of Medicine, University of Hawaii, 1319 Punahou Street, Suite 950, Honolulu, Hawaii, USA.
Tel: 808-983-8933; Fax: 808-957-9770.
E-mail: andrasb@hphmg.org

Self-limited myocarditis presenting with chest pain and ST segment elevation in adolescents after vaccination with the BNT162b2 mRNA vaccine

Jihyun Park¹ , Dona R. Brekke^{1,2} and Andras Bratincsak^{1,2} 

¹Department of Pediatrics, John A. Burns School of Medicine, University of Hawaii, Honolulu, Hawaii, USA and ²Pediatric Cardiology, Hawaii Pacific Health Medical Group, Honolulu, Hawaii, USA

Abstract

Two adolescent males presented within 3 days after the first and second dose of the BNT162b2 vaccine with chest pain. Elevated troponin levels, ST segment elevation, and enhancement of the myocardium in cardiac MRI suggested myocarditis. Left ventricular function remained normal, symptoms resolved, and patients were discharged in 4 days. BNT162b2 vaccine may be associated with self-limited myocarditis in youth.

COVID-19 vaccination has been available since December 2020. On 10 May, 2021, the Food and Drug Administration approved the use of the BNT162b2 vaccine in the paediatric population aged 12 years and older. Vaccination of youth with an mRNA vaccine against SARS-CoV-2 has been recommended by the American Academy of Pediatrics and Centers for Disease Control and Prevention.^{1,2} A single case of myocarditis in an adult following administration of the BNT162b2 vaccine has been reported from Spain.³ Recently, there have been several reports about myocarditis following mRNA vaccines against SARS-CoV-2.⁴ We describe, for the first time, adolescents presenting with chest pain and imaging evidence of myocarditis in close temporal association with the BNT162b2 vaccination.

Two adolescent males, aged 15–16 years of age, presented in the Emergency Department with chest pain within 3 days of BNT162b2 vaccine administration, one of them after the first, the other after the second dose of the vaccine. One patient noted mild and typical vaccine-related symptoms including tactile fever, headache, and tender vaccination site within a day of vaccine administration, while the other patient had no such symptoms. Within a couple of days after vaccination, both patients developed acute onset, mid-sternal, non-radiating chest pain associated with chest tightness. One patient had a history of mild intermittent asthma, otherwise, they had no known medical conditions and no prior surgeries.

Their initial vital signs were notable for sinus tachycardia with heart rate of 108–116 beats per minute, but normal blood pressure. They had a normal cardiac exam without a murmur or friction rub. Inflammatory markers were mildly elevated (Table 1). Complete blood count was notable for neutrophilia without leukocytosis. Cardiac enzymes were elevated in both cases at presentation (Table 1). Infectious workup including immunoglobulin G and real-time reverse transcription polymerase chain reaction for SARS-CoV-2 and respiratory viral panel polymerase chain reaction containing the most common aetiologic agents of viral myocarditis were negative in both patients.

Chest X-rays were unremarkable. Electrocardiograms showed ST elevation and T wave inversion in lateral leads (Fig 1). Both patients had normal left ventricular systolic function on echocardiogram (Table 1). Small areas of increased echogenicity could be detected throughout the myocardium in one of the patients, especially in the interventricular septum and lateral wall of the left ventricle (Fig 1). Cardiac MRI with early gadolinium enhancement using electrocardiogram-gated turbo spin echo T1-weighted sequences showed mild global early enhancement of the myocardium, with pronounced enhancement in the subendocardial layer of the left ventricle (Fig 1), findings consistent with inflammation of the myocardium without evidence of myocardial necrosis, fibrosis, or oedema. Cardiac catheterisation was not performed as there was low suspicion for acute coronary syndrome and the cardiac MRI was consistent with myocarditis.

One patient received intravenous immunoglobulin, while the other patient improved without any treatment. Echocardiograms continued to show normal left ventricular function throughout the hospitalisation. Troponin T peaked at 832 and 1210 ng/L, but creatine kinase myocardial band did not increase beyond initial levels (Table 1). Chest pain resolved a day after admission and both patients were discharged from the hospital within 4 days of admission. Electrocardiograms showed improved, but continued mild ST segment elevation at discharge.

Table 1. Demographics, clinical findings, and diagnostic test results of the patients with myocarditis following BNT162b2 vaccine administration

		Patient A	Patient B	
Demographics	Age, years	15	16	
	Sex	Male	Male	
	Ethnicity/race	Filipino	Filipino, Caucasian	
History of cardiac conditions		None	None	
BNT162b2 vaccine	Number of doses given	1	2	
	Days after last vaccine administration to onset of chest pain	3	2	
Vital signs at presentation	Heart rate, beats per minute	116	108	
	Blood pressure, mmHg	119/72	131/91	
	Temperature, °C	37.2	37.2	
	Respiratory rate	18	20	
	SpO ₂ in room air, %	96	100	
Cardiac markers (normal range)	Troponin T, ng/L (<20 ng/L)	At presentation	304	431
		Peak	832	1210
	CKMB, U/L (<4.1 U/L)	At presentation	54.6	39.3
		Peak	54.6	39.3
	NT-proBNP, pg/mL (0–125 pg/mL)	At presentation	108	325
		Peak	498	364
Other laboratory results (normal range)	ESR, mm/hr (0–15 mm/hr)	7	31	
	Procalcitonin (<0.10 ng/mL)	0.15	<0.06	
	CRP, mg/L (<5.0 mg/L)	18.5	24.3	
	SARS-CoV-2 RT-PCR	Negative	Negative	
	SARS-CoV-2 IgG (<1.40 index)	Negative (0.24)	Negative (0.03)	
	Respiratory viral panel PCR	Negative	Negative	
Electrocardiogram findings	ST segment elevation in lateral leads, left axis deviation	ST segment elevation in inferolateral leads, T wave inversion		
Echocardiogram findings	LVEF 63%, increased patchy echogenicity of the myocardium	LVEF 60%		
Cardiac MRI findings	Not obtained	Early gadolinium enhancement (4 minutes) of the myocardium		

CKMB = creatine kinase myocardial band; CRP = C-reactive protein; ESR = erythrocyte sedimentation rate; IgG = immunoglobulin G; LVEF = left ventricular ejection fraction; NT-proBNP = N-terminal prohormone of brain natriuretic peptide; PCR = respiratory viral panel polymerase chain reaction; Respiratory viral panel RT-PCR = real-time reverse transcription polymerase chain reaction; SpO₂ = blood oxygen saturation.

Discussion

We present two adolescents with evidence of myocarditis shortly after BNT162b2 vaccination. The presentation of these adolescents were consistent with myocarditis based on clinical, imaging, and laboratory findings, and no other alternative aetiology was found. We excluded acute or recent COVID-19 infection and did not find evidence of other viral aetiologies. The temporal association with the preceding COVID-19 vaccine raised the suspicion of a vaccine-related self-limited myocarditis. Myocarditis have been rarely reported in association with vaccinations in the past.⁵ BNT162b2 vaccine has certain adverse effects, including localised reaction such as swelling, pain, itchiness at the inoculation site, and generalised fatigue, headache and chills.⁶ A single case report of myocarditis in a young adult after COVID-19 vaccination was reported in April 2021 from Spain, and recent reports and clinical

consideration from the Centers for Disease Control and Prevention appeared during the month of May 2021.^{3,4,7} In the state of Hawaii, 33,470 adolescents aged 12–17 years have received at least one dose of BNT162b2 vaccine and of those, 10,029 adolescents have received two doses as of 1 June, 2021.⁸ To our knowledge, there have been no other reported cases of myocarditis following BNT162b2 vaccine administration in the state of Hawaii in population 17 years or younger besides the two patients presented here. These reports, consistent with our findings, suggest that the BNT162b2 vaccine could rarely be associated with the development of myocarditis.

The pathomechanism of vaccine-induced myocarditis associated with the BNT162b2 vaccine is not clear. Since there is no infectious viral particle in the vaccine, the myocarditis cannot be due to an infectious agent. We hypothesise that the myocarditis

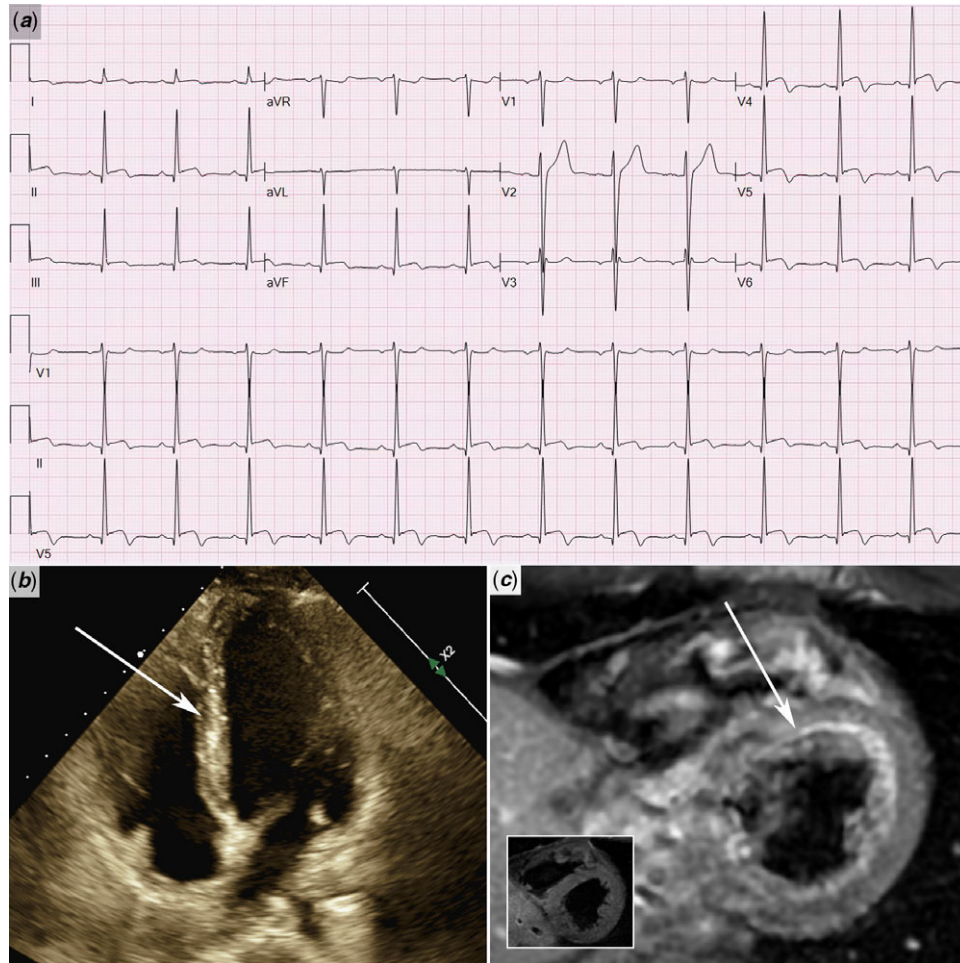


Figure 1. Electrocardiogram, echocardiogram, and cardiac MRI findings associated with myocarditis after BNT162b2 vaccination. (a) Electrocardiogram shows ST segment elevation, especially in the lateral leads. (b) The echocardiogram shows patchy echogenic foci in the left ventricle with intact left ventricular systolic function. Arrow indicates echogenic areas in the interventricular septum. (c) Cardiac MRI with gadolinium enhancement using electrocardiogram-gated turbo spin echo T1-weighted sequences demonstrates early enhancement of the myocardium of the left ventricle, especially in the subendocardial layer, but no necrosis or significant oedema, consistent with myocarditis. Arrow indicates bright, enhanced areas of the left ventricular myocardium. Insert shows pre-gadolinium image with no myocardial enhancement.

is related to the immune response triggered by the vaccine in a genetically susceptible host. As the host generates antibodies against the viral particle assembled in response to the mRNA vaccine, the antibodies may cross react with surface antibodies on the cardiomyocytes resulting in an inflammatory reaction with cell damage. This cell damage, manifesting as focal patchy myocarditis, causes the ST segment elevation and chest pain. Based on our limited experience and recent vaccine-related news reports, it is possible that myocarditis in temporal association with the BNT162b2 vaccine is an important side effect to monitor. Myocarditis associated with the current mRNA vaccine seems self-limited without any circulatory collapse. Our case series suggests that chest pain within a week of COVID-19 vaccination with an mRNA vaccine should raise the suspicion of focal myocarditis. Although this focal myocarditis may be self-limited and resolve without intervention, ST segment elevation and troponin elevation may occur, and patients should be monitored for the extent of cardiac involvement, symptoms, and cardiac function. These patients with vaccine-related myocarditis should refrain from physical activity following general guidelines for myocarditis.⁹

Acknowledgements. We would like to acknowledge Dr. Marian Melish and Dr. Sanah Christopher for their contribution in the management of patients included in this report.

Financial support. This research received no specific grant from any funding agency, commercial or not-for-profit sectors.

Conflict of interest. None.

Ethical standards. Appropriate consent was obtained from the patients' families. The current report is exempt from Institutional Review Board review.

Supplementary material. To view supplementary material for this article, please visit <https://doi.org/10.1017/S1047951121002547>

References

1. Committee on Infectious Diseases. COVID-19 vaccines in children and adolescents. *Pediatrics* 2021; e2021052336.
2. Wallace M, Woodworth KR, Gargano JW, et al. The Advisory committee on immunization practices' Interim recommendation for use of Pfizer-BioNTech COVID-19 vaccine in adolescents aged 12–15 years — United States, May 2021. *MMWR Morb Mortal Wkly Rep* 2021; 70: 749–752.

3. García JB, Ortega PP, Fernández JAB, et al. Acute myocarditis after administration of the BNT162b2 vaccine against COVID-19. *Rev Esp Cardiol* 2021; S1885-5857(21)00133-X.
4. Advisory Committee on Immunization Practices. COVID-19 VaST Work Group Technical Report – May 17, 2021. Centers for Disease Control and Prevention Vaccine Safety Technical Work Group Reports 2021 May.
5. Mei R, Raschi E, Forcesi E et al. Myocarditis and Pericarditis after Immunization: gaining Insights through the Vaccine Adverse Event Reporting System. *Int J Cardiol* 2018; 273: 183–186.
6. Kadali RAK, Janagama R, Peruru S et al. Side effects of BNT162b2 MRNA COVID-19 vaccine: a randomized, cross-sectional study with detailed self-reported symptoms from healthcare workers. *Int J Infect Dis* 2021; 106: 376–381.
7. Centers for Disease Control and Prevention. Clinical considerations: Myocarditis and pericarditis after receipt of mRNA COVID-19 vaccines among adolescents and young adults. Centers for Disease Control and Prevention 2021 May.
8. State of Hawaii Department of Health, Disease Outbreak Control Division COVID-19 Response. Hawaii COVID-19 Data. State of Hawaii Department of Health, Disease Outbreak Control Division 2021 June.
9. Maroon BJ, Udelson JE, Bonow RO, et al. Eligibility and Disqualification Recommendations for Competitive Athletes with Cardiovascular Abnormalities: task Force 3: hypertrophic Cardiomyopathy, Arrhythmogenic Right Ventricular Cardiomyopathy and Other Cardiomyopathies, and Myocarditis. *Circulation* 2015; 132: e273–e280.