

Battlefield, Barracks, or Hospital? A Bioarchaeological Investigation of a Mass Grave at the Jičín Observatory, Czech Republic

LESLIE QUADE^{1*} , LAIA SEVILLANO²  AND DANIEL GAUDIO³ 

¹ Department of Anthropology, Masaryk University, Brno, Czech Republic

² Departament de Biologia Evolutiva, Universitat de Barcelona, Spain

³ Department of Archaeology, Durham University, UK

*Author for correspondence: Quade@sci.muni.cz

In 2016, a rescue excavation at the Jičín Natural Sciences Centre and Observatory uncovered a mass grave containing multiple commingled individuals buried in several layers. Zinc buttons and clothing remnants possibly related to eighteenth–nineteenth-century military uniforms found in the grave suggest that these individuals were soldiers. During this period, the Jičín region experienced numerous battles and was the location of several military barracks, hospitals, and transport routes, in addition to supporting civilian populations. To contextualize this burial site, bioarchaeological analyses including assessments of age-at-death, sex, and stature, and recording the presence of injury or medical intervention were conducted. A high frequency of young adult males suggests that the grave was related to military activity. The presence of infants, limited evidence of perimortem trauma, and absence of signs of medical treatment could indicate that this mass grave was related to military encampments rather than battlefield contexts.

Keywords: eighteenth–nineteenth-century military, Napoleonic Wars, encampments, perimortem injury, march foot, conflict archaeology

INTRODUCTION

In 2016, a rescue excavation at the Jičín Natural Sciences Centre and Observatory in the north of the Czech Republic uncovered a mass grave (Figure 1). It revealed multiple commingled individuals buried in several layers, some separated by thin deposits of soil. Simple, unmarked zinc buttons and clothing remnants possibly related to eighteenth–nineteenth-century military uniforms

were found in the grave, suggesting that these individuals were soldiers. The Jičín area had seen extensive military presence and campaigning, including numerous battles, the establishment of military barracks and hospitals, and the transport of soldiers across the region (Table 1). In the eighteenth and nineteenth centuries, Czech lands were largely under the control of the Habsburgs and as a result played an important role within Holy Roman Imperial and

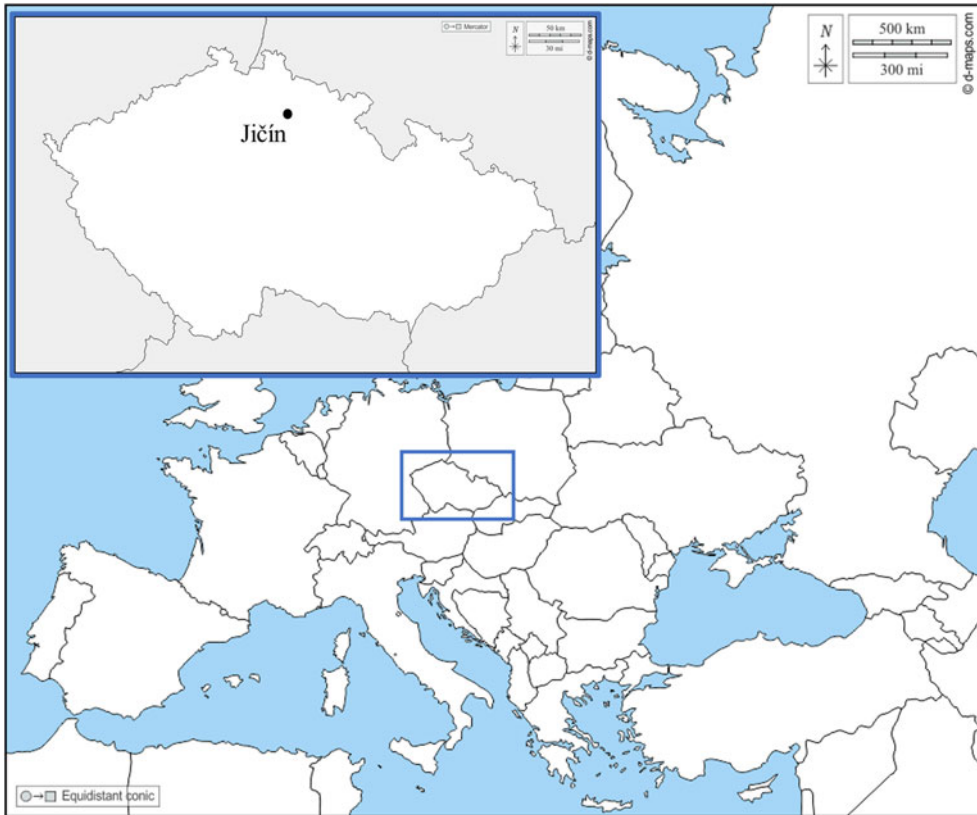


Figure 1. Location of Jičín in present-day Czech Republic and surrounding countries.

Austrian politics and military strategy. Jičín is located between several major Habsburg cities (Prague, Vienna) and Prussia, a regular adversary and occasional ally throughout the eighteenth and nineteenth centuries. Additionally, Jičín lay along an important military route during the Napoleonic Wars. Due to its strategic location, Austrian, French, Prussian, and Russian soldiers and prisoners passed through, convalesced, or fought in and around Jičín throughout this period.

Given the limitations of the archaeological evidence and layering of the mass grave, the individuals buried in Jičín may have been the casualties of any of the multiple battles, hospital stays, or transport events that took place in the region during the War of Austrian Succession (1740–1748), the Seven Years War (1756–1763),

and the Napoleonic Wars (1803–1815). Alternative explanations remain possible, as there were civilian communities living in and around the area. To contextualize this burial site, bioarchaeological analyses were conducted, including assessment of age-at-death, sex, stature, and presence of trauma. Identifying the demographic profile of the individuals and the presence of injury or medical intervention may indicate whether the deceased were related to battlefield, hospital, or other contexts.

EIGHTEENTH- AND NINETEENTH-CENTURY MILITARY MASS BURIALS

Research on eighteenth- and nineteenth-century military mass burials provides an important framework for analysing the Jičín

Table 1. *Events related to the movement of troops or prisoners in Jičín and its surroundings, 1742 to 1814 (modified from Novák, 2018: 9–10).*

Year	Name/description	Larger conflict
1742	Battle of Chotusitz	War of the Austrian Succession (1740–1748)
1744	King of Prussia Frederick II invade Bohemia, the Prussians occupy Jičín	
1745	Saxons move beginning 15 May from Mladá Boleslav to Jičín	
1748	Arrival of the Austrian army and its accommodation in Jičín	
c. 1750	Permanent military garrison in Jičín, barracks set up in Nové Město	
1757, spring	Prussian field marshal marches through Jičín, army camp established between Šibeňák and Libosad	Seven Years War (1756–1763)
1757, winter	Jičín forced to care for hundreds of sick and wounded Austrian soldiers	
1763	Military registry office established; Prussian Cossacks invade Jičín	
1776	Jičín hosts six companies of the Austrian Arenberg/Ahremberg Regiment	
1802	Archduke Charles calls the army in and around the Jičín region for service	Napoleonic Wars (1803–1815)
1813 (second half of year)	Thousands of (Russian?) soldiers pass through Jičín; hospital set up in the school and barracks; at the end of 1813, up to 700 French prisoners housed within the city until Easter 1814	
1814	Russian prisoners waiting near the Šibeňák river transported into and through Jičín	

mass grave (Cooper, 2006; Binder, 2008; von Grumbkow et al., 2012; Dutour & Buzhilova, 2013; Quade & Binder, 2018). These burials (and other military mass graves) have typically been identified through a combination of features, including finds from the graves, grave location, body positioning, the demographic profile of those buried, and the presence and frequency of skeletal trauma (Knüsel, 2005).

Mass graves are used when the number of dead overwhelms a community's ability to observe traditional burial rituals (Rugg, 2000). Such situations include disease, famine, and mass violence, all of which occurred in Europe during the eighteenth and nineteenth centuries. Although large numbers of the dead need to be buried as quickly as possible to reduce the outbreak of disease (Rugg, 2000), the relationships between a surviving local community and those who died from illness or warfare,

respectively, would likely have been different. Mass burials stemming from illness or famine may demonstrate signs of care or the maintenance of certain burial or funeral rites (Knüsel, 2005: 58–60); body positioning may be more consistent, and soil may separate the layers of the dead (Hawkins, 1990). The victims of interpersonal violence are usually handled in a less methodical way (Gaudio et al., 2015). Soldiers were often rapidly interred in shallow graves with little to no organization of the bodies and limited, if any, funerary customs (Binder & Quade, 2018). Soldiers could have belonged to the opposing faction, and both allied and combatant soldiers can have poor, exploitative, or violent interactions with local communities (Wszolek & Podruczny, 2010). These same communities might then be responsible for burying deceased soldiers (Ranseder et al., 2017). There may not have been time, resources,

or interest in performing traditional burial rites, or even treating the bodies with respect.

In addition to the positioning of the body and treatment of the grave, several features relating to human remains are consistently used to distinguish between graves resulting from mass mortality and those related to military or other violent encounters. Most military burials contain a disproportionately high number of young to middle-aged adult males compared to attritional cemeteries and mass graves from mortality crises (Signoli et al., 2004: 224-26; Gowland & Chamberlain, 2005; Binder, 2008; Buzhilova et al., 2009: 378-80). While mortality crises such as famine or disease tend to affect broad sections of the population, a high proportion of young adult males can reflect recruitment for military service. Additionally, minimum height requirements were often mandatory for entry into military service. Some divisions or regiments specified stature, requiring recruits or conscripts to have heights within specific (often tall) ranges (Komlos, 1989; Weir, 1997: 174, 193). Therefore, soldiers often represent a distinct subset of the population (Stegmann, 1985: 78; Sledzik & Sandberg, 2002), suggesting that stature data can support other demographic information when identifying military burials.

The identification of military mass graves can be further supported by analysing skeletal trauma (Knüsel, 2005: 50-58). In addition to heightened frequency, the type of trauma and stage of healing also provide important contextual information. For example, the presence of multiple ballistic or projectile injuries can be particularly suggestive of combat or battlefield experience. Blunt and sharp force trauma is often observed in military mass graves but, depending on the period and social context, can also be the result of small-scale interpersonal violence or accidents.

Despite the frequency of war across most of eighteenth- and nineteenth-century Europe, only a few excavated mass graves seem to be directly related to battlefields, displaying multiple cases of perimortem trauma (Binder & Quade, 2018). In these contexts, injuries were too severe for individuals to survive and/or there was no detectable evidence of healing, treatment, or medical intervention. The concept of treating injured soldiers during battle only became common in the nineteenth century (Skandalakis et al., 2006). Before then, treatment was largely reserved for individuals who were able to return to nearby field hospitals or could wait until battle had ended. Most eighteenth- and nineteenth-century military mass graves have been related to retreating or hospitalized soldiers, dying of illness, starvation, or infection from at least initially survivable injuries (Signoli et al., 2004; Buzhilova et al., 2009; Jankauskas, 2012). As a result, these studies report higher incidences of injuries with signs of healing or treatment, such as amputations. Additionally, the skeletons of females and children are also more commonly found within the context of retreating or convalescing soldiers. Families sometimes accompanied soldiers on campaigns and women undertook important work in military camps and their environs (Cardoza, 2010). Therefore, the frequency and type of injuries, their state of healing and treatment, and the demographic profile of buried individuals can reveal whether mass graves are directly related to a battle or other military contexts.

RESEARCH QUESTIONS AND AIMS

The primary goal of our study was to assess the individuals buried in the Jičín mass grave and to ascertain whether their remains could be associated with military activity (combat, hospital, or transport) in

the area, through the following research questions:

1. Does the demographic profile of the individuals suggest a military or other type of mass mortality event? Does the bioarchaeological evidence support the historical record?
2. Can evidence of skeletal trauma provide useful insights into the archaeological and historical context? What types of injuries are present and how frequent are they?
3. Can the analysis of the skeletal remains provide information about the military context (combat, hospital, or transport)? If observed, does skeletal trauma show signs of healing, treatment, or medical intervention?

MATERIALS AND METHODS

A small rescue excavation was conducted in November–December 2016 in advance of building a septic tank and biofilter next to the Jičín Natural Sciences Centre and Observatory. The excavation of a rectangular area (not the entire burial pit) measuring 1.8 m × 1.7 m and up to 1.5 m deep uncovered the remains of multiple individuals along with remnants of clothing, bronze fastenings, and simple zinc buttons (Novák, 2018: 3–11). The buttons ranged from 17 mm to 23 mm in diameter; most were produced in a similar fashion without distinguishing features. The excavators concluded that the buttons probably belonged to Austrian or Prussian standardized military attire from between the eighteenth century and the first half of the nineteenth century (Novák, 2018: 8–11) (Figure 2). Because only a small part of what is thought to be a much larger burial was uncovered, the exact dimensions of the grave and its contents are unknown.

Within the excavated segment, thirty-six *in situ* skeletons retaining varying degrees of anatomical connection were found (more articulated individuals were identified in later analysis, see below). The grave also contained multiple isolated bones and fragments, with a minimum of thirty-nine additional individuals identified subsequently (Kubálek, 2018). The articulated bodies were buried crosswise and overlapping one another (Novák, 2018: 7–8). Most were highly fragmented and were represented by partial skeletons, commingled with other remains. Thirty-three of the thirty-six individuals were buried in a supine position. The orientation of the head and position of the upper and lower limbs were highly variable (Novák, 2018: 7–8), seemingly indicating a lack of consistent or systematic funerary treatment. Thin layers of soil between some individuals might suggest that they were interred gradually, perhaps at short intervals.

The remains were assessed to obtain their demographic profile (age-at-death, sex, stature) and to ascertain the presence of skeletal trauma and signs of medical treatment (Sevillano & Quade, 2022). A full accounting of the methods can be found in the [Online Supplementary Material](#). Briefly, age-at-death was assessed through analyses of dental development and wear (Brothwell, 1981; AlQahtani et al., 2010), stage of epiphyseal fusion (Scheuer & Black, 2000a and 2000b), and morphological changes of the sternal rib ends, pubic symphysis, and auricular surface of the os coxae (Işcan et al., 1984; Lovejoy et al., 1985; Brooks & Suchey, 1990). Individuals were then assigned into broad age categories (Table 2). Sex was estimated for adult individuals from a combination of sexually dimorphic features in the skull and pelvis (Brothwell, 1981; Buikstra & Ubelaker, 1994) and metric analyses (Bass, 1995).




Figure 2. The Jičín Observatory site mass grave during excavation and multiple buttons recovered from the grave. Reproduced by permission of the Regional museum and gallery in Jičín.

Stature was calculated from measurements of long bones and regression formulae (Trotter, 1970). All bones were examined macroscopically for evidence of skeletal trauma (Ubelaker & Adams, 1995; Knüsel, 2005: 58; Lovell, 1997; Sauer, 1998; Loe, 2016; Symes et al., 2014: 347). Where possible, the type of antemortem and perimortem trauma was investigated (blunt, sharp, projectile, ballistic), based on the morphological characteristics of the injuries (Berryman & Haun, 1996; Berryman & Symes, 1998; Symes et al., 2001, 2012; Berryman et al., 2012; DiMaio, 2015).

RESULTS

The analysis of the Jičín Observatory remains revealed forty-seven articulated individuals (eleven more than originally reported) and a minimum of thirty-nine individuals generated from the assemblage of disarticulated bones. For the remainder of this assessment, only the forty-seven articulated individuals are considered. The bone surface was generally well preserved, showing only slight surface erosion, and fragmentation was slight. The average completeness of each skeleton was quite low, at around 35–40

Table 2. Age categories, age range in years, and number of individuals and percentage of total individuals assessed in this analysis.

Non-adult (<18 years)				Adult (>18 years)			
Age Categories	Years	No.	Percent	Age Categories	Years	No.	Percent
Infant	0–1.9	2	4.3%	Young adult	18–25.9	14	29.8%
Young child	2–4.9	0		Young-middle adult	26–35.9	7	14.9%
Mature child	5–9.9	0		Old-middle adult	36–45.9	2	4.3%
Young adolescent	10–14.9	0		Mature adult	46+	3	6.4%
Mature adolescent	15–17.9	7	14.9%	Adult	18+	11	23.4%
Adolescent (unspecified)	10–17.9	1					
Total		10				37	

No. = number of individuals

per cent, and could explain discrepancies between the thirty-six articulated individuals originally identified at excavation and the subsequent identification of more individuals. Of the forty-seven articulated individuals, 34.0 per cent (sixteen individuals) were males, 21.3 per cent (ten individuals) were probable males and 44.7 per cent (twenty-one individuals) were of indeterminate sex or without sex assessment (Figure 3). No individuals with marked female traits were observed. For the remainder of the analysis, ‘males’ and ‘probable males’ are pooled into the ‘male’ category. Thirty-seven, or the majority of individuals, were adults (78.7%). Young adults were the most frequent (29.8%), followed by young-middle adults (14.9%), mature adults (6.4%), and old-middle adults (4.3%) (Table 2). Eleven individuals were classified only as ‘adults’ (18+ years) (23.4%). Ten non-adult individuals were identified, including eight adolescents, seven of which could be classed as mature adolescents. One adolescent had an age range from ten to eighteen years old. Two infants less than two years old were also identified. These results show that the majority of the

deceased were young males, between fifteen and thirty-five years old (59.6%, twenty-eight individuals).

Stature

Due to the low level of completeness of the remains, stature was estimated for only eight individuals, generating values ranging from 160.36 cm to 181.06 cm. The mean estimated stature is 170.71 cm. These individuals were all classified as male or probable male, with one exception, whose sex was indeterminate. Considering only those with assigned male or probable male sex, the stature ranges between 163.42 cm and 181.06 cm, with an average stature of 172.24 cm.

Skeletal trauma

Antemortem lesions were recorded in two individuals. SK19, a mature adolescent, had a depressed fracture on the right medial tibial plateau, resulting in a significant compression of the trabecular bone. The depressed surface displays moderate

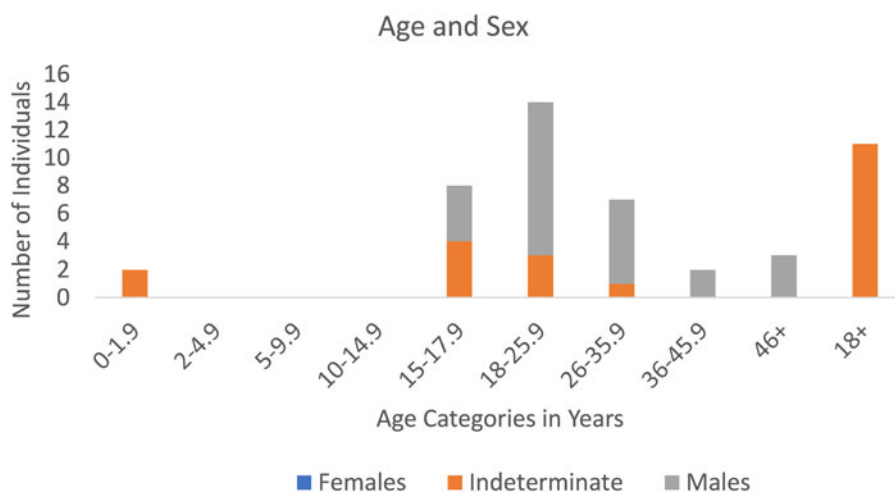


Figure 3. Sex and age estimation of the individuals recovered from the Jičín Observatory site.

porosity, suggesting that degenerative joint disease is related to this injury. SK32b, an adult (18+ years old) of indeterminate sex, demonstrated an antemortem transverse fracture of the right second metatarsal. There is a callous, or thickened bone, formation at mid-shaft, with no evidence of overlap of the bone fragments. In both cases, adjacent bones were examined for complementary or additional signs of trauma. None were identified, preventing further identification of the origin of these fractures.

Three individuals demonstrated signs of perimortem trauma. All occurrences of perimortem injury were at least partially obscured by postmortem damage and in many cases relevant bone elements were not preserved, limiting analysis of injury type or origin. SK19 presented comminuted fractures of the distal shaft of the left femur (Figure 4) and the right ilium. The femoral shaft has a minimum of three fragments, which displayed features of perimortem comminuted fractures. The right ilium shows a curved fracture in the centre of the anterior iliac fossa (26 mm

long). The adjacent fragments or bones were not recovered. The presence of comminuted fractures suggests an impact of considerable force, consistent with blunt force or low velocity projectile/ballistic forms of injury.

Two individuals presented perimortem fractures of the cranium and mandible (Figure 5). The remains of SK26 (a mature adolescent) were heavily fragmented, but several fragments of the skull had shared perimortem fracture edges. The left half of the frontal bone displays a perimortem oblique radiating fracture curving from the orbital margin, extending superiorly to the supraorbital ridges, and crossing a retained metopic suture. An angular flake of bone extends from the fracture margin on the ectocranial surface of the frontal bone (Figure 5A). The fracture ends approximately 15 mm into the right half of the frontal bone and was fragmented postmortem. That the fracture extends through the metopic suture suggests an impact with considerable force (Sanchez et al., 2010). The remainder of the cranium was heavily damaged, leaving no




Figure 4. Perimortem trauma of the distal left femur fragment of individual SK19. The arrows point to a perimortem comminuted fracture of similar patination and flake shape (postmortem damage is present and obscures most of the bone's edges).

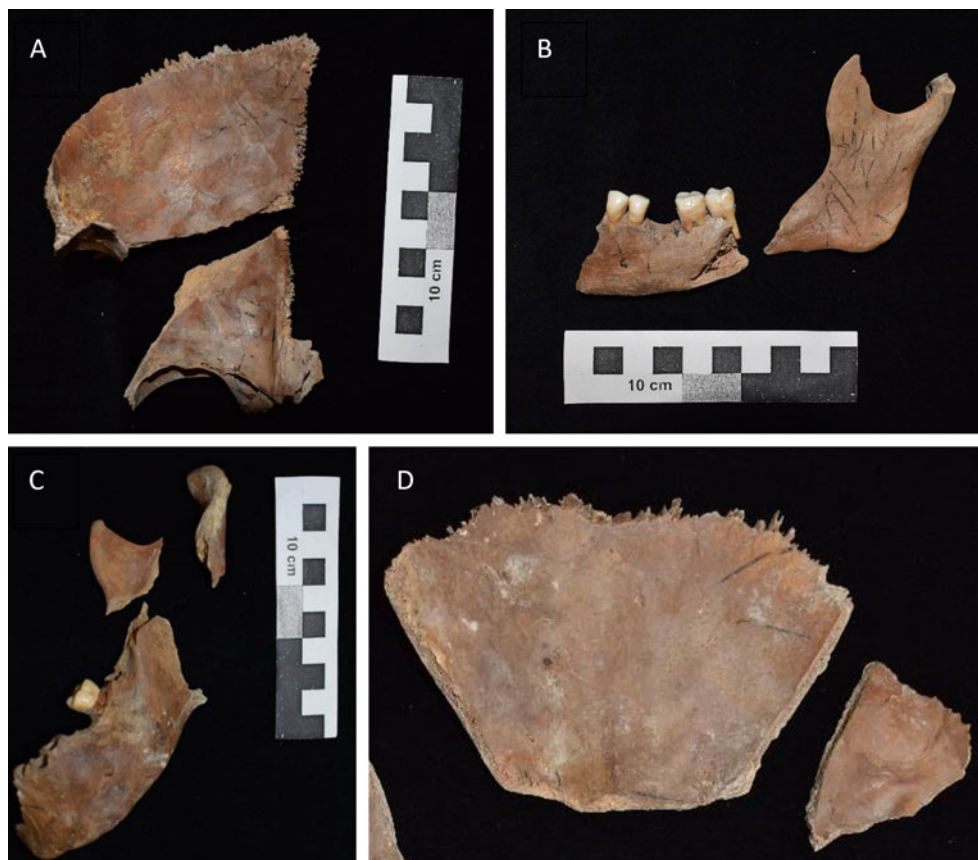


Figure 5. A. Endocranial surface of the left frontal bone of SK26, displaying perimortem fracture in the transverse plane and a retained metopic suture. B. Mandible of SK26, displaying perimortem fracture of the horizontal ramus. C. Perimortem fractures in the left ascending ramus of the mandible of SK36A. D. Perimortem fracture of the frontal bone near the coronal suture (endocranial surface) of SK36A.

other unambiguous signs of perimortem trauma. The mandible also shows several perimortem fractures, separating the mandible into seven fragments. Both ascending rami are separated from the horizontal ramus through V-shaped fractures, leaving sharp angled flakes of bone (Figure 5B). We attempted to reconstruct the cranium and mandible to ascertain the origin of these injuries, but fragmentation and post-mortem damage prevented us from locating a precise point of impact or potential entry or exit wounds. This suggests that either blunt force or projectile forms of

trauma remain possible explanations for this injury.

Individual SK36A, a young adult male, presented perimortem fractures of the cranium, mandible, and first cervical vertebra. The frontal bone is fragmented into multiple pieces, several of which display features of perimortem trauma. Two linear fractures separate the frontal bone along the sagittal plane between the temporal line and the sagittal sulcus (midline of the bone) on either side of the bone (Figure 5D). The right temporal bone has a perimortem fracture running between

the pars petrosa and squama, separating the bone. The parietal bones are highly fragmented, obscuring possibly pertinent information connected to the injuries in the frontal and right temporal bones. The mandible is fragmented into several pieces, three of which display some features of perimortem injury such as smooth angled flaking and bevelling of the fractured edge. The left condylar neck and coronoid process show perimortem fractures at the mandibular notch, separating them from each other and from the rest of the ascending ramus (Figure 5C). The first cervical vertebra has an angled perimortem fracture in the left retroarticular surface. Because radiating fractures extend away from the location of the impact (Symes et al., 2014: 357-60), it is possible that many of these fractures are the result of an injury to the face. Very few facial bones were recovered, limiting extensive interpretation. As with previous cases, it was not possible to specify whether these injuries resulted from blunt force or low velocity projectile trauma. No signs of sharp force trauma or medical intervention, such as amputation, were observed in the Jičín remains.

DISCUSSION

Demography

Several aspects of our analysis suggest that the Jičín mass grave was related to military activity. The high frequency of young adult males is broadly consistent with other eighteenth- and nineteenth-century military burials (Signoli et al., 2004: 224-25; Rigeade et al., 2006: 904-05; Binder, 2008; Buzhilova et al., 2009: 378-80; Danforth et al., 2016; Vymazalová et al., 2021: 4). In these graves, as at Jičín, the burials contained primarily males between eighteen and thirty-five years old. This corresponds with military recruitment

or conscription policies of the late eighteenth and early nineteenth centuries, which preferentially selected individuals between the ages of twenty and thirty (Steegmann, 1985: 78). Several adolescents were also interred at Jičín. Most (seven individuals) were older adolescents, aged fifteen to eighteen, who could potentially have been engaged in military service. Although conscription was supposed to begin at twenty, several studies have reported finding the remains of adolescents (and even young adolescents less than fifteen years old) in military graves (Horáčková & Benešová, 1997; Buzhilova et al., 2009: 378-79; Quade & Binder, 2018: 29-31). British military records from the late eighteenth century include data for soldiers ranging in age from nine to sixty-one years old, suggesting that in some cases much younger (and much older) individuals were enlisted (Steegmann, 1985: 79). When recruited for military service, young boys were officially taken on as musicians and helpers (Steegmann, 1985: 79), but individuals may also have concealed their age to join the service. The presence of adolescents in the Jičín burial lends further support for it being a military mass grave.

Stature

Stature data can be compared with contemporary skeletal remains as well as eighteenth- and nineteenth-century recruitment or conscription requirements. The estimated mean stature of the Jičín individuals was 172.24 cm, largely aligning with individuals from contemporary military burials, including soldiers from the Napoleonic Grande Armée retreating through Vilnius in 1812 (mean = 171.6 cm; Jankauskas et al., 2007). Because height reflects a combination of genetic and environmental factors during development, adult stature

has in the past (and today) been used as an indicator of health, wellbeing, and overall fitness (Komlos, 1989). During the eighteenth and nineteenth centuries, British, French, and Habsburg armies had minimum height requirements for entry into military service and also recorded the heights of service members (Steegmann, 1985: 78-79; Komlos, 1989; Weir, 1997: 174-77). The minimum height to join the French army during the Napoleonic Wars was 154 cm, with the average height of conscripts recorded as 163.6 cm (Weir, 1997: 192-97). Based on these criteria, the eight Jičín individuals whose stature could be calculated met the minimum height requirements for military service, and all but one exceeded the average reported height for conscripts. Therefore, not only do the Jičín individuals represent a particularly tall subsection of the general population, but they are also tall within military populations. Certain regiments had greater height requirements. In the French army, the tallest recruits (178+ cm) were assigned to heavy cavalry units, the next tallest (173–178 cm) went to the young Imperial Guards, followed by the artillery (169–173 cm) and light cavalry (165–169 cm) (Buzhilova et al., 2009: 380-81). Several of the Jičín individuals exceeded even the tallest height requirements, which could suggest that the burial was related to specific units, and could be an interesting avenue of future research. The stature data provide additional evidence that the mass grave at Jičín is linked to military activity.

Trauma

The Jičín individuals do not show any discernible evidence of previous combat (in the form of skeletal antemortem weapon-related injuries), as observed in contemporary burials (Buzhilova et al., 2009: 380-81; Quade & Binder, 2018:

29-32). However, at least one Jičín individual had an antemortem fracture of the second metatarsal. Fractured metatarsals have been reported in multiple contemporaneous military burials, and are thought to be the result of ‘march foot’ (Buzhilova et al., 2009: 380-81; Dutour & Buzhilova, 2013; Quade & Binder, 2018: 30-31). March foot, or stress fractures of the second or third metatarsals can be caused by long-distance marches while carrying heavy loads and/or wearing poor or ill-fitting footwear (Weinfeld et al., 1997). The condition is commonly observed in military personnel in the past and present, possibly strengthening the case for the Jičín burial being a military grave.

In Jičín, three individuals showed unambiguous evidence of perimortem trauma. Although few in number, these injuries were severe and indicative of substantial force (comminuted fractures of the femur and skull), indicating extremely violent encounters that are compatible with combat. However, the weaponry or type of force causing these injuries could not be further identified, partly because postmortem alterations affected the observed fractures, complicating their interpretation. Additionally, linear cranial and comminuted fractures, such as those seen in the Jičín individuals, can be caused by both blunt force and low-velocity projectile trauma (Knüsel, 2005: 55-58; Berryman et al., 2012; Symes et al., 2012). High-velocity ballistic trauma most often penetrates the bone, leaving characteristic entry and/or exit wounds (Knüsel, 2005: 55-58). In the eighteenth and early nineteenth centuries, most musket balls would have been fired at low velocities, which were more likely to create crushing or ‘ricochet’ damage to the skeleton (Larrey, 1812: 200-02, 459-68; Magee, 1995: 892-95; DiMaio, 2015: 88). In such cases, especially in the absence of clear entry or

exit wounds and associated weaponry or ammunition, it can be challenging or even impossible to distinguish between blunt force injury and low-velocity projectile/ballistic forms of trauma (Symes et al., 2012; Loe, 2016; Binder & Quade, 2018). The available evidence of perimortem trauma in the Jičín individuals is, therefore, less definitive than the demographic profiles from the grave.

An alternative explanation for the observed trauma is linked to the challenges posed by assessing perimortem and post-mortem alterations to bone. Perimortem trauma refers to injury that occurs while the bone is still wet or fresh, when organic components are retained (Quatrehomme & Işcan, 1997). Because bone retains some of these qualities immediately following death, perimortem injuries include trauma that occurs slightly before, during, and slightly after death (Symes et al., 2014: 341–43). Moreover, it is not entirely clear or consistent when a bone transitions from ‘wet’ to ‘dry’, and many factors, including bone type and burial environment, contribute to variations in this process (Symes et al., 2014: 346–49). It is possible that the perimortem fractures observed at Jičín could be a form of ‘pseudotrauma’, in which bones were fractured shortly after death, while the bone was still wet. Previous research has identified that animal, plant, and human activity can be mistakenly identified as fatal injuries (Symes et al., 2014: 341–42). Perimortem linear fractures, such as those seen in the Jičín skulls, result from deformation of the skull in response to ‘tensile strain’ (Knüsel, 2005: 56). This tensile strain could have occurred when the bodies were placed or stacked in the grave, overlapping one another. This seems an especially plausible explanation as there is little clear evidence of weapon-related perimortem trauma. Among the Napoleonic soldiers retreating from Vilnius, Signoli and colleagues

(2004: 226) found extensive ‘perimortem fractures’ that they attributed to looting of the bodies after death. We should therefore not entirely exclude postmortem treatment or burial conditions (before bone became ‘dry’) as an explanation for the trauma observed at Jičín.

Although only three individuals with unambiguous evidence of perimortem trauma were identified, most data have thus far suggested that the Jičín mass grave was related to military activity. Many contemporaneous military mass graves show high frequencies of perimortem injury (Meyer, 2003; Signoli et al., 2004: 226; Cooper, 2006; Rigeade et al., 2006: 905–06; Binder & Quade, 2018). The prevalence of such injuries is seen as a key feature to distinguish between military mass graves and those related to other forms of mortality crises (Knüsel, 2005: 58) and, therefore, the paucity of their occurrence at Jičín presents further challenges for our interpretation.

What kind of military environment?

Although dramatic and dynamic, battles were short episodes (lasting hours, sometimes days) in a soldier’s military experience. Months and years were spent travelling, preparing for combat, waiting in encampments, or convalescing in hospitals (Wszolek & Podruczny, 2010). It is therefore plausible that the Jičín mass grave was an encampment burial. In addition to the scarcity of perimortem trauma, there is some evidence that supports this interpretation. Although no individuals with markedly female traits were identified at Jičín, two infants were found in the grave. Many of the contemporaneous military mass graves related to hospitalized or retreating soldiers contained a small number of females, as well as children and infants (Horáčková & Benešová, 1997;

Buzhilova et al., 2009: 378-79; Thèves et al., 2016). Women may have been officers' wives travelling with the campaign or civilians providing various services to the soldiers (Cardoza, 2010). Accordingly, the Jičín infants may have been the children of military personnel, unable to survive harsh conditions, or possibly local children who were simply buried in an already open grave. In their dietary isotopic analysis of individuals (including a few females) buried in a mass grave at Vilnius, Holder and colleagues (2017) found that the grave did not contain local Lithuanians but individuals/soldiers from the greater European area. This could suggest that the Jičín infants were more likely to have been related to military personnel, but biochemical methods would be required to explore this hypothesis. The presence of infants in the Jičín mass grave could also suggest that the burial is related to military encampments or hospitals rather than battlefield settings.

The Jičín grave exhibits some contradictory features. In the Napoleonic mass graves at Vilnius, Austerlitz, and Aspern, as well as in the burials related to the siege of Douai in northern France during the War of Spanish Succession in 1710–1712 (rue Martin-du-Nord site), body position was extremely varied and disorganized (Signoli et al., 2004: 223; Rigeade et al., 2006: 903-04; Ranseder et al., 2017; Vymazalová et al., 2021: 3). In contrast, several small burial pits within the mass grave of Napoleon's Great Army at Kaliningrad showed consistency in head-to-head placement and care in how the initial corpses were interred (Buzhilova et al., 2009: 378-79). These graves have been associated with soldiers taken to military hospitals, based on the high frequency of healing wounds and the presence of medical flasks and civilian buttons within the burials (Buzhilova et al., 2009: 378-81). These individuals may have spent longer within the local community

than soldiers engaging in or fleeing from battle. Although the position of the upper and lower limbs and orientation of the head appears to have been haphazard in Jičín, most individuals were buried in a supine position. Further, thin layers of soil separated some of the bodies, which has been proposed as one potential sign of mass burials related to illness or famine (Hawkins, 1990). Therefore, the Jičín burial has features associated with military mass graves, but also several features that could indicate more 'care' or consistency. The burial evidence (presence of infants and paucity of perimortem injury) in Jičín may therefore be interpreted as representing the grave of people who died in a non-battlefield context, perhaps in a setting where soldiers were present for longer periods (hospital or barracks).

Treatment, healing, or disease

Multiple military mass graves from the eighteenth and nineteenth centuries have been associated with military, field, or local hospitals. This has largely been identified through the presence of medical equipment within the burials and signs of healing or treatment in the interred individuals (Rigeade et al., 2006: 905-07; Buzhilova et al., 2009: 380-81; Vymazalová et al., 2021: 4-7, 11). At Kaliningrad, extensive evidence of healing and signs of treatment were noted (Buzhilova et al., 2009: 380). Skeletal signs of healing take time to develop, suggesting that the individuals survived the initial injury. Soldiers might receive treatment near the battlefield but could also be taken to temporary or civilian hospitals in the surrounding areas, or even at considerable distances (Vymazalová et al., 2021: 9-13). The most common form of skeletally detectable treatment are amputations (either individuals with severed limbs or the severed limbs

themselves; Buzhilova et al., 2009; 379–81; Vymazalová et al., 2021: 6–7, 11). As mentioned, treatment was largely reserved for post-battle conditions and environments. Consequently, the presence of surgical amputations along with most other skeletally detectable forms of treatment suggests a mass grave related to hospital contexts. Other evidence of treatment, in the form of trepanation, has also been reported in an earlier eighteenth century mass grave in Douai (Rigeade et al., 2006: 905). There is limited evidence suggesting that the Jičín grave was related to the temporary hospitals known in the area (see Table 1). No evidence of healing, treatment, or medical intervention was observed, but this may have been obscured by postmortem damage. The absence of skeletal evidence does not exclude the possibility that injured soldiers were interred at Jičín, as many conditions, injuries, and treatments are not detectable in the skeleton.

The separation of military and disease-related mass graves can, in some cases, be a false dichotomy. Military actions and infectious diseases were often related. Infectious disease was an acknowledged common occurrence and a serious problem in military settings (Larrey, 1812). Soldiers lived in crowded conditions, in less than hygienic conditions, generally had poor diets, and were exposed to infectious agents as well as mental, emotional, and physical stressors (Larrey, 1812; Muir, 2000). Bioarchaeologically, several infectious diseases have been identified within military mass graves through aDNA analyses, including typhus (*Rickettsia prowazekii*) and trench fever (*Bartonella quintana*) (Raoult et al., 2006; Nguyen-Hieu et al., 2010). Other diseases, such as dysentery and tetanus, were also rampant (Larrey, 1812). Moreover, the military could transfer pathogens and disease from one location to another (e.g. typhus on the retreat from Vilnius to Kaliningrad),

potentially infecting local civilian populations as soldiers travelled or stayed in local hospitals (Buzhilova et al., 2009: 381). In such cases, the inclusion of women and children from local hospitals might be anticipated. Although destructive analyses were not possible for the Jičín individuals, skeletal signs of infection were observed in several individuals. This mostly included signs of non-specific infection, such as porosity and new bone formation on the endocranial vault, maxillary sinusitis, and periosteal reaction of the long bones. No signs of specific infection were observed but their presence cannot be excluded (Sevillano & Quade, 2022). Consequently, the possibility that the Jičín mass grave was related to military hospitals cannot be entirely excluded.

CONCLUSION

The purpose of this study was to ascertain whether the mass grave at the Jičín Observatory was related to military activity and, if possible, attribute it to a battlefield, encampment, or hospital setting. Combined with the existing documentation relating to extensive military activity in the area and the presence of military uniform buttons, the high frequency of young adult males and older adolescents of tall stature suggests that this was a military grave. Our study explored whether soldiers may have died on the battlefield, or were travelling, retreating, or staying in barracks and hospitals. Several lines of evidence differ from contemporaneous military mass graves (presence of infants, some organization of the burial, little ante- and perimortem trauma, and absence of signs of medical treatment). We therefore suggest that this mass grave was most likely to have been related to encampments rather than combat; although we cannot exclude a connection with hospital

contexts. In future research, biochemical analyses, including aDNA (Raoult et al., 2006; von Grumbkow et al., 2012), stable isotope analyses indicative of diet and mobility (Holder et al., 2017), and Energy-Dispersive X-Ray Spectroscopy (Vymazalová et al., 2021; 4, 6-8) could provide further information to contextualize the Jičín grave, as well as military activity in the surrounding area, shedding light on the origins and experiences of the individuals buried there. This study demonstrates how multiple strands of enquiry are essential for contextualizing the complex scenarios that characterize conflict archaeology in the recent past.

ACKNOWLEDGEMENTS

This work was supported by the Postdoc 2MUNI under grant number CZ.02.2.69/0.0/0.0/18_053/0016952, awarded to L. Quade. We would like to thank Jiří Unger, Dominika Schmidtová, the Regionální muzeuma galerie v Jičíně (Regional museum and gallery in Jičín), Petr Hejhal, Petra Urbanová, and the reviewers and editors for their help and support in this analysis.

SUPPLEMENTARY MATERIAL

To view supplementary material for this article please visit <https://doi.org/10.1017/ea.2023.36>.

REFERENCES

- AlQahtani, S.J., Hector, M.P. & Liversidge, H.M. 2010. Brief Communication: The London Atlas of Human Tooth Development and Eruption. *American Journal of Physical Anthropology*, 142: 481–90. <https://doi.org/10.1002/ajpa.21258>
- Bass, W.M. 1995. *Human Osteology: A Laboratory and Field Manual* (4th edn). Columbia (MO): Missouri Archaeological Society.
- Berryman, H.E. & Haun, S.J. 1996. Applying Forensic Techniques to Interpret Cranial Fracture Patterns in an Archaeological Specimen. *International Journal of Osteoarchaeology*, 6: 2–9. [https://doi.org/10.1002/\(SICI\)1099-1212\(199601\)6:1<2::AID-OA244>3.0.CO;2-R](https://doi.org/10.1002/(SICI)1099-1212(199601)6:1<2::AID-OA244>3.0.CO;2-R)
- Berryman, H.E. & Symes, S.A. 1998. Recognizing Gunshot and Blunt Cranial Trauma through Fracture Interpretation. In: K.J. Reichs, ed. *Forensic Osteology: Advances in the Identification of Human Remains*. Springfield (IL): Charles C. Thomas, pp. 333–52.
- Berryman, H.E., Lanfear, A.K. & Shirley, N.R. 2012. The Biomechanics of Gunshot Trauma to Bone: Research Considerations within the Present Judicial Climate. In: D.C. Dirkmaat, ed. *A Companion to Forensic Anthropology*. Chichester: Wiley-Blackwell, pp. 390–99. <https://doi.org/10.1002/9781118255377.ch18>
- Binder, M. 2008. *Der Soldatenfriedhof in der Marchettigasse in Wien: die Lebensbedingungen einfacher Soldaten in der Theresianisch-Josephinischen Armee anhand Anthropologischer Untersuchungen* (Monografien der Stadtarchäologie Wien, 4). Wien: Phoibos.
- Binder, M. & Quade, L. 2018. Death on a Napoleonic Battlefield: Peri-Mortem Trauma in Soldiers from the Battle of Aspern 1809. *International Journal of Paleopathology*, 22: 66–77. <https://doi.org/10.1016/j.ijpp.2018.05.007>
- Brooks, S. & Suchey, J.M. 1990. Skeletal Age Determination Based on the Os Pubis: A Comparison of the Acsádi-Nemeskéri and Suchey-Brooks Methods. *Human Evolution*, 5: 227–38. <https://doi.org/10.1007/BF02437238>
- Brothwell, D.R. 1981. *Digging Up Bones: The Excavation, Treatment, and Study of Human Skeletal Remains*. Ithaca (NY): Cornell University Press.
- Buikstra, J.E. & Ubelaker, D.H. 1994. *Standards for Data Collection from Human Skeletal Remains* (Arkansas Archaeological Survey Research Series, 44). Fayetteville (AR): Arkansas Archaeological Survey.
- Buzhilova, A., Rigeade, C., Shvedchikova, T., Ardagna, Y. & Dutour, O. 2009. The Discovery of a Mass Grave of Napoleon's Great Army in Kaliningrad (Formerly Königsberg), Russian Federation:

- Preliminary Results and Interpretations. In: L. Buchet, C. Rigeade, I. Séguy & M. Signoli, eds. *Vers une anthropologie des catastrophes. Actes des 9e journées d'anthropologie de Valbonne*. Antibes: APDCA & Paris: INED, pp. 375–83.
- Cardoza, T. 2010. *Intrepid Women: Cantinières and Vivandières of the French Army*. Bloomington (IN): Indiana University Press.
- Cooper, C. 2006. Soldaten von 1799/1800: Massengräber aus Zürich und Schaffhausen. *Bulletin der Schweizerischen Gesellschaft für Anthropologie*, 12: 23–34.
- Danforth, M.E., Funkhouser, J.L. & Martin, D.C. 2016. The United States–Mexican War Soldiers of Greenwood Island, Mississippi: An Historical, Archaeological, and Bioarchaeological Analysis. *Historical Archaeology*, 50: 92–114. <https://doi.org/10.1007/BF03379201>
- DiMaio, V.J. 2015. *Gunshot Wounds: Practical Aspects of Firearms, Ballistics, and Forensic Techniques*. Boca Raton (FL): CRC Press.
- Dutour, O. & Buzhilova, A. 2013. Palaeopathological Study of Napoleonic Mass Graves Discovered in Russia. In: C.J. Knüsel & M.J. Smith, eds. *The Routledge Handbook of the Bioarchaeology of Human Conflict*. London: Routledge, pp. 557–70.
- Gaudio, D., Betto, A., Vanin, S., De Guio, A., Galassi, A. & Cattaneo, C. 2015. Excavation and Study of Skeletal Remains from a World War I Mass Grave. *International Journal of Osteoarchaeology*, 25: 585–92. <https://doi.org/10.1002/oa.2333>
- Gowland, R.L. & Chamberlain, A.T. 2005. Detecting Plague: Palaeodemographic Characterisation of a Catastrophic Death Assemblage. *Antiquity*, 79: 146–57. <https://doi.org/10.1017/S0003598X00113766>
- Hawkins, D. 1990. The Black Death and the New London Cemeteries of 1348. *Antiquity*, 64: 637–42. <https://doi.org/10.1017/S0003598X0007856X>
- Holder, S., Dupras, T.L., Jankauskas, R., Williams, L. & Schultz, J. 2017. Reconstructing Diet in Napoleon's Grand Army Using Stable Carbon and Nitrogen Isotope Analysis. *American Journal of Physical Anthropology*, 163: 53–63. <https://doi.org/10.1002/ajpa.23184>
- Horáčeková, L. & Benešová, L. 1997. Findings of War-Time Injuries from the Battle of Austerlitz. *Anthropologie (Brno)*, 35: 283–89.
- Işcan, M.Y., Loth, S.R. & Wright R.K. 1984. Age Estimation from the Rib by Phase Analysis: White Males. *Journal of Forensic Science*, 29: 1094–104. <https://doi.org/10.1520/JFS11776J>
- Jankauskas, R. 2012. *Inciderunt itaque in fossam quam sibi ipsi fecerunt*: Mass Grave of Napoleon's Soldiers in Vilnius December 1812. *Revue des Études Slaves*, 83: 981–91. <https://doi.org/10.3406/slave.2012.8288>
- Jankauskas, R., Palubeckaitė-Miliauskienė, Ž., Barkus, A. & Urbanavičius, A. 2007. Military Stature Variation During the 19th Century: Napoleonic Versus German Soldiers of World War. *Papers on Anthropology*, 16: 122–31.
- Knüsel, C.J. 2005. The Physical Evidence of Warfare: Subtle Stigmata? In: M. Parker Pearson & I.J.N. Thorpe, eds. *Warfare, Violence and Slavery in Prehistory (Proceedings of a Prehistoric Society Conference at Sheffield University)*. Oxford: Archaeopress, pp. 49–65.
- Komlos, J. 1989. *Nutrition and Economic Development in the Eighteenth-Century Habsburg Monarchy*. Princeton (NJ): Princeton University Press.
- Kubálek, P. 2018. Základní antropologické zpracování lidských kosterních nálezů z výzkumu v Jičíně, akce Hvězdárna, provedeném v roce 2016, IČ: 700 77 304. Unpublished osteological report. Prague: Regionální muzeum a galerie v Jičíně.
- Larrey, D.B. 1812. *Mémoires de chirurgie militaire et campagne*. Paris: J. Smith.
- Loe, L. 2016. Perimortem Trauma. In: D.H. Ubelaker & S. Blau, eds. *Handbook of Forensic Anthropology and Archaeology*. London: Routledge, pp. 388–414.
- Lovejoy, C.O., Meindl, R.S., Pryzbeck, T.R. & Mensforth, R.P. 1985. Chronological Metamorphosis of the Auricular Surface of the Ilium: A New Method for the Determination of Adult Skeletal Age at Death. *American Journal of Physical Anthropology*, 68: 15–28. <https://doi.org/10.1002/ajpa.1330680103>
- Lovell, N.C. 1997. Trauma Analysis in Paleopathology. *American Journal of Physical Anthropology*, 104: 139–70. [https://doi.org/10.1002/\(SICI\)1096-8644\(1997\)25+<139::AID-AJPA6>3.0.CO;2-%23](https://doi.org/10.1002/(SICI)1096-8644(1997)25+<139::AID-AJPA6>3.0.CO;2-%23)

- Magee, R. 1995. Muskets, Musket Balls and the Wounds They Made. *Australian and New Zealand Journal of Surgery*, 65: 890–95. <https://doi.org/10.1111/j.1445-2197.1995.tb00583.x>
- Meyer, C. 2003. Osteological Evidence for the Battles of Zürich, 1799: A Glimpse into Soldierly of the Past. *International Journal of Osteoarchaeology*, 13: 252–57. <https://doi.org/10.1002/oa.683>
- Muir, R. 2000. *Tactics and the Experience of Battle in the Age of Napoleon*. New Haven (CT): Yale University Press.
- Nguyen-Hieu, T., Aboudharam, G., Signoli, M., Rigeade, C., Drancourt, M. & Raoult, D. 2010. Evidence of a Louse-Borne Outbreak Involving Typhus in Douai, 1710–1712 During the War of Spanish Succession. *PLoS ONE*, 5: e15405. <https://doi.org/10.1371/journal.pone.0015405>
- Novák, R. 2018. *Jičín, u hvězdárny, nálezová zpráva číslo akce: C-201671289*. Unpublished report. Jičín: Regionální muzeum a galerie v Jičíně.
- Quade, L. & Binder, M. 2018. Life on a Napoleonic Battlefield: A Bioarchaeological Analysis of Soldiers from the Battle of Aspern, Austria. *International Journal of Paleopathology*, 22: 23–38. <https://doi.org/10.1016/j.ijpp.2018.03.006>
- Quatrehomme, G. & İşcan, M.Y. 1997. Postmortem Skeletal Lesions. *Forensic Science International*, 89: 155–65. [https://doi.org/10.1016/S0379-0738\(97\)00113-8](https://doi.org/10.1016/S0379-0738(97)00113-8)
- Ranseder, C., Sakl-Oberthaler, S., Penz, M., Binder, M. & Czeika, S. 2017. *Napoleon in Aspern: Archäologische Spuren der Schlacht 1809*. Wien: Phoibos.
- Raoult, D., Dutour, O., Houhamdi, L., Jankauskas, R., Fournier, P.-E., Ardagna, Y., et al. 2006. Evidence for Louse-Transmitted Diseases in Soldiers of Napoleon's Grand Army in Vilnius. *The Journal of Infectious Diseases*, 193: 112–20. <https://doi.org/10.1086/498534>
- Rigeade, C., Willot, J.-M., Demolon, P., Rabino Massa, E. & Signoli, M. 2006. Approche anthropologique de sépultures de catastrophe du XVIIIe siècle (rue Martin-du-Nord, Douai, France). *Comptes Rendus Palevol*, 5: 901–07. <https://doi.org/10.1016/j.crpv.2006.06.002>
- Rugg, J. 2000. Defining the Place of Burial: What Makes a Cemetery a Cemetery? *Mortality*, 5: 259–75. <https://doi.org/10.1080/713686011>
- Sanchez, T., Stewart, D., Walvick, M. & Swischuk, L. 2010. Skull Fracture vs. Accessory Sutures: How Can We Tell the Difference? *Emerging Radiology*, 17: 413–18. <https://doi.org/10.1007/s10140-010-0877-8>
- Sauer, N.J. 1998. The Timing of Injuries and Manner of Death: Distinguishing Among Antemortem, Perimortem and Postmortem Trauma. In: K. Reichs, ed. *Forensic Osteology: Advances in the Identification of Human Remains*. Springfield (IL): Charles C. Thomas, pp. 321–31.
- Scheuer, J.L. & Black, S. 2000a. Development and Ageing of the Juvenile Skeleton. In: M. Cox & S. Mays, eds. *Human Osteology in Archaeology and Forensic Science*. Cambridge: Cambridge University Press, pp. 9–21.
- Scheuer, J.L. & Black, S. 2000b. *Developmental Juvenile Osteology*. San Diego (CA): Academic Press.
- Sevillano, L. & Quade, L. 2022. Osteological Analysis of the Jičín Observatory Excavations. Unpublished osteological report. Brno: Masaryk University.
- Signoli, M., Ardagna, Y., Adalian, P., Devriendt, W., Lalys, L., Rigeade, C., et al. 2004. Discovery of a Mass Grave of Napoleonic Period in Lithuania (1812, Vilnius). *Comptes Rendus Palevol*, 3: 219–27. <https://doi.org/10.1016/j.crpv.2004.02.003>
- Skandalakis, P.N., Lainas, P., Zoras, O., Skandalakis, J.E. & Mirilas, P. 2006. 'To Afford the Wounded Speedy Assistance': Dominique Jean Larrey and Napoleon. *World Journal of Surgery*, 30: 1392–99. <https://doi.org/10.1007/s00268-005-0436-8>
- Sledzik, P.S. & Sandberg, L.G. 2002. The Effects of Nineteenth-Century Military Service on Health. In: R.H. Steckel & J.C. Rose, eds. *The Backbone of History: Health and Nutrition in the Western Hemisphere*. Cambridge: Cambridge University Press, pp. 185–207.
- Steggmann, A.T. 1985. 18th Century British Military Stature: Growth Cessation, Selective Recruiting, Secular Trends, Nutrition at Birth, Cold and Occupation. *Human Biology*, 57: 77–95. <https://digitalcommons.wayne.edu/humbiol/vol57/iss1/20>

- Symes, S.A., L'Abbé, E.N., Chapman, E.N., Wolff, I. & Dirkmaat, D.C. 2012. Interpreting Traumatic Injury to Bone in Medicolegal Investigations. In: D.C. Dirkmaat, ed. *A Companion to Forensic Anthropology*. Oxford: Wiley-Blackwell, pp. 340–89. <https://doi.org/10.1002/9781118255377.ch17>
- Symes, S.A., L'Abbé, E.N., Stull, K.E., LaCroix, M. & Pokines, J.T. 2014. Taphonomy and the Timing of Bone Fractures in Trauma Analysis. In: J.T. Pokines & S.A. Symes, eds. *Manual of Forensic Taphonomy*. Boca Raton (FL): CRC Press, pp. 341–65.
- Symes, S.A., Williams, J.A., Murray, E.A., Hoffman, J.M., Holland, T.D., Saul, J.M., et al. 2001. Taphonomic Context of Sharp-Force Trauma in Suspected Cases of Human. In: W.D. Haglund & M.H. Sorg, eds. *Advances in Forensic Taphonomy: Method, Theory, and Archaeological Perspectives*. Boca Raton (FL): CRC Press, pp. 403–34.
- Thèves, C., Cabot, E., Bouakaze, C., Chevet, P., Crubézy, É. & Balaresque, P. 2016. About 42% of 154 Remains from the 'Battle of Le Mans', France (1793) Belong to Women and Children: Morphological and Genetic Evidence. *Forensic Science International*, 262: 30–36. <https://doi.org/10.1016/j.forsciint.2016.02.029>
- Trotter, M. 1970. Estimation of Stature from Intact Long Limb Bones. In: T.D. Stewart, ed. *Personal Identification in Mass Disasters*. Washington, DC: Smithsonian Institution, pp. 71–83.
- Ubelaker, D.H. & Adams, B.J. 1995. Differentiation of Perimortem and Postmortem Trauma Using Taphonomic Indicators. *Journal of Forensic Science*, 40: 509–12. <https://doi.org/10.1520/JFS13818J>
- von Grumbkow, P., Zipp, A., Großkopf, B., Fueldner, K. & Hummel, S. 2012. Analyses to Help Identify Individuals from a Historical Mass Grave in Kassel, Germany. *Anthropologischer Anzeiger*, 69: 1–43. <https://doi.org/10.1127/0003-5548/2011/0140>
- Vymazalová, K., Vargová, L., Horáčková, L., Kala, J., Přichystal, M., Brzobohatá, K., et al. 2021. Soldiers Fallen in the Battle of Austerlitz. *Archaeological and Anthropological Sciences*, 13: 1–18. <https://doi.org/10.1007/s12520-021-01445-7>
- Weinfeld, S.B., Haddad, S.L. & Myerson, M.S. 1997. Metatarsal Stress Fractures. *Clinics in Sports Medicine*, 16: 319–38. [https://doi.org/10.1016/S0278-5919\(05\)70025-9](https://doi.org/10.1016/S0278-5919(05)70025-9)
- Weir, D. 1997. Economic Welfare and Physical Well-Being in France, 1750–1990. In: R.H. Steckel & R. Floud, eds. *Health and Welfare During Industrialization*. Chicago: University of Chicago Press, pp. 161–200. <http://www.nber.org/chapters/c7431>
- Wszolek, J. & Podruczny, G. 2010. Lost Elements: Earthworks of the Fortified Camp of the Russian Army from the Time of the Battle of Kunersdorf in the Light of the Recent Research. *Archaeologia Postmedievale*, 14: 65–80.

BIOGRAPHICAL NOTES

Leslie Quade is a biological anthropologist investigating stress, health, and injury in human skeletal remains. Her research often incorporates life course approaches. She completed her PhD in bioarchaeology and paleopathology at Durham University in 2021 and was a postdoctoral researcher in the Anthropology Department of Masaryk University in the Czech Republic from 2021–2023. She is currently a researcher with the Austrian Archaeological Institute at the Austrian Academy of Sciences. She has published on health status and trauma among Napoleonic soldiers, patterns of health and stress in Roman and post-Roman Gaul, as well as the development of dental cortisol analyses in archaeological and modern teeth.

Address: Department of Anthropology, Faculty of Science, Masaryk University, Kotlářská 267/2, 611 37, Brno, Czech Republic. [email: Quade@sci.muni.cz]. ORCID: 0000-0002-5453-3975.

Laiá Sevillano Oriola is a junior human biologist specialized in biological and forensic anthropology. She trained in 3D modelling and virtual anthropology and her research includes forensic applications to virtual

models of cranial remains. She is interested in forensic analysis of trauma and paleopathology, and exhumations and identifications of skeletons in mass graves from the Spanish Civil War. She has fieldwork experience on mass graves in Spain and has undertaken anthropological analyses to identify victims. She is currently working on medieval sites, including the exhumation of mass graves.

Address: Departament de Biologia Evolutiva, Ecologia i Ciències Ambientals, Facultat de Biologia, Universitat de Barcelona (UB), Av. Diagonal, 643, 08028 Barcelona, Spain. [email: laia.sevillano.oriola@gmail.com].

Daniel Gaudio is assistant professor in bioarchaeology and forensic science at the Department of Archaeology at Durham

University (UK). He studied skeletal remains from periods including the Neolithic, ancient Egypt and Rome, the Middle Ages, the Risorgimento, and World War I conflict contexts. He also worked as a consultant in forensic casework and as a researcher and lecturer in Ireland, Canada, the Czech Republic, and the UK. His research focuses on conflict archaeology and new methodologies in human bioanthropology and forensic anthropology, including age-at-death, skeletal trauma, and taphonomy. He currently directs the MSc programme in Forensic Archaeology and Anthropology at Durham University.

Address: Department of Archaeology, Durham University, South Rd, Durham DH1 3LE, UK. [email: daniel.gaudio@durham.ac.uk]. ORCID: [0000-0002-2009-1574](https://orcid.org/0000-0002-2009-1574).

Champ de bataille, caserne ou hôpital ? Un examen bioarchéologique de la fosse commune de l'Observatoire de Jičín en Tchéquie

Des fouilles d'urgence en 2016 sur le site du Centre des Sciences naturelles et Observatoire de Jičín ont mis à jour une fosse commune contenant les restes entremêlés d'individus disposés sur plusieurs couches. Des boutons en zinc et des lambeaux de vêtements découverts dans cette fosse représentent probablement les restes d'uniformes militaires portés par des soldats du XVIIIe–XIX siècle. À cette époque, la région de Jičín fut le théâtre de nombreuses batailles et on y établit plusieurs casernes militaires, des hôpitaux et des axes routiers, ajoutant ainsi aux charges de la population locale. L'étude bioarchéologique présentée ici, qui a pour but de contextualiser la fosse commune, comprend des analyses de l'âge au décès, du sexe et de la stature des défunts ainsi qu'un examen des blessures ou interventions médicales présentes. Le nombre élevé de jeunes individus masculins semble indiquer une fosse commune associée à des activités militaires. La présence d'enfants, la rareté des traumatismes mortels et l'absence de signes de traitement médical font penser à une fosse liée à un campement militaire plutôt qu'à un champ de bataille.
Translation by Madeleine Hummler

Mots-clés: activité militaire au XVIIIe–XIX siècle, guerres napoléoniennes, campements, traumatismes, troubles du pied causés par la marche, archéologie des conflits

Schlachtfeld, Kaserne oder Spital? Eine bioarchäologische Untersuchung eines Massengrabes im Observatorium von Jičín in Tschechien

Im Jahre 2016, während Notausgrabungen im naturwissenschaftlichen Zentrum und Observatorium von Jičín wurde ein Massengrab entdeckt. Es enthielt die vermengten und mehrschichtig verteilten menschlichen Überreste von mehreren Individuen. Die im Grab geborgenen Knöpfe aus Zink und

Kleidungsreste könnten zu Militäruniformen des 18. und 19. Jahrhunderts gehören und liegen es nahe, dass die Toten Soldaten waren. Mehrere Schlachten fanden im Gebiet von Jičín statt und Kasernen, Spitale und Transportwege wurden in der Gegend errichtet, was zu den Lasten der Zivilbevölkerung beitrug. Bioarchäologische Untersuchungen des Sterbealters, des Geschlechts und der Körpergröße der Toten sowie die Aufzeichnung von Verletzungen oder Zeichen von medizinischen Eingriffen wurden durchgeführt, um das Massengrab in seinem Kontext zu setzen. Der hohe Anteil junger erwachsener Männer lässt darauf schließen, dass das Grab mit militärischen Aktivitäten verbunden war. Die Anwesenheit von Kindern, die Seltenheit von tödlichen Verletzungen und die Abwesenheit von medizinischen Behandlungen lassen es vermuten, dass das Massengrab im Zusammenhang mit Militärlager und nicht mit Schlachtfeldern steht. Translation by Madeleine Hummler

Stichworte: Militär im 18. und 19. Jahrhundert, napoleonische Kriege, Lager, tödliche Verletzungen, Fußerkrankungen durch Eilmarsch, Konfliktarchäologie