

Neuroimaging Highlight

Editor: David Pelz

Angiographic Demonstration of Upward Transtentorial Herniation

Submitted by: Cameron M. McDougall, Andrew Jack, Jean Raymond, Michel W. Bojanowski, Tim E. Darsaut

Can J Neurol Sci. 2014; 41: 82-83

A 47-year-old female experienced a sudden onset headache with associated nausea and vomiting, and was found on computed tomogram (CT) scan to have suffered a Grade 3 subarachnoid hemorrhage (SAH) with associated vermian hemorrhage. Subsequent CTA demonstrated a posterior fossa arteriovenous malformation (AVM) with two flow-associated aneurysms, a posterior inferior cerebellar artery (PICA) aneurysm, and a superior cerebellar artery (SCA) aneurysm, which was felt responsible for the hemorrhage (Figure A).

During hospital transfer, her level of consciousness became compromised, decreasing to a Glasgow Coma Score (GCS) of 10. An external ventricular drain (EVD) was placed, releasing cerebrospinal fluid (CSF) under moderate pressure. An hour following placement of the EVD, her GCS further decreased to 6, with a loss of her left corneal and gag reflexes, in spite of a supratentorial intracranial pressure (ICP) of 14 mm H₂O. While the surgical team was mobilized for posterior fossa decompression, the patient was treated with 500 mL of 20%

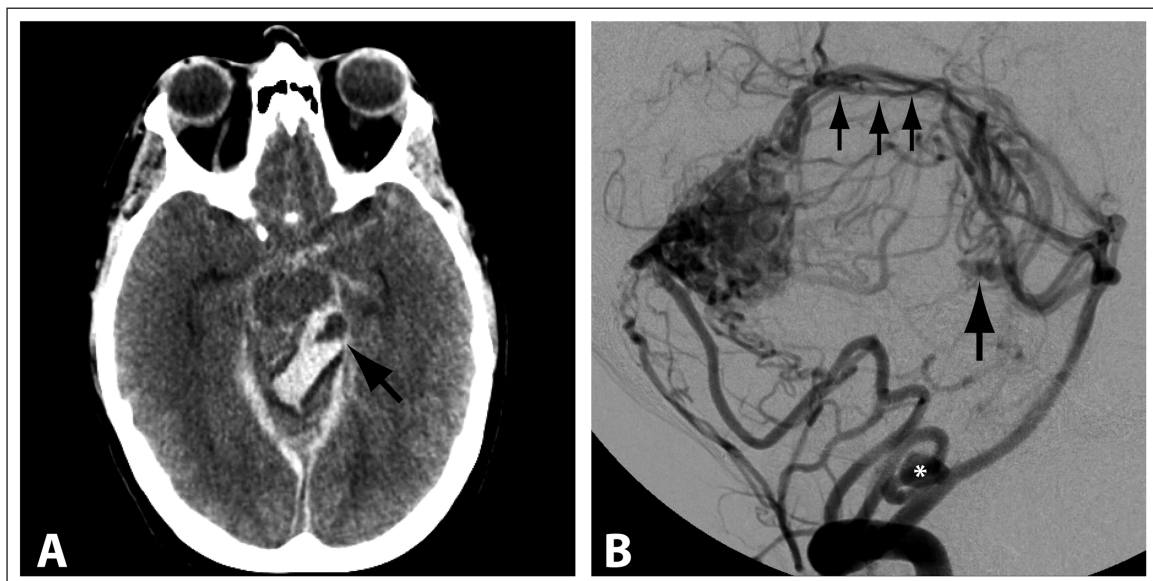


Figure: A) CT head showing distal SCA aneurysm (arrow) surrounded by hematoma in the superior vermis. B) Lateral projection of left vertebral artery injection demonstrates PICA origin aneurysm (asterisk), with ruptured distal SCA aneurysm (large arrow), both on vessels supplying a cerebellar AVM. As a result of localized vermian mass effect, the upward arching SCAs and superior vermician branches are elevated through the tentorial hiatus (arrows).

From the Division of Neurosurgery, Department of Surgery (CMM, AJ, TED), Mackenzie Health Sciences Centre, University of Alberta Hospital, Edmonton, Alberta; Department of Radiology (JR), Department of Surgery (MWB), Division of Neurosurgery, Hôpital Notre-Dame, Centre Hospitalier de l'Université de Montréal, Montréal, Québec, Canada.

RECEIVED JULY 24, 2013. FINAL REVISIONS SUBMITTED AUGUST 27, 2013.

Correspondence to: Tim E. Darsaut, Division of Neurosurgery, Department of Surgery, Mackenzie Health Sciences Centre, 2D1.02 - University of Alberta Hospital, 8440 - 112 Street, Edmonton, Alberta, T6G 2B7, Canada. Email: tdarsaut@ualberta.ca.

mannitol and urgently brought to the angiography suite to better delineate the AVM angio-architecture, and with a view to potentially coil the ruptured aneurysm.

Catheter angiography revealed several findings consistent with upwards transtentorial herniation (Figure B). The ruptured SCA aneurysm was quickly occluded (total duration of angiography and intervention was 29 minutes), and the patient underwent subsequent emergency posterior fossa decompression, leaving the AVM undisturbed. Within two days post-operatively, she had recovered sufficiently to follow commands, albeit with a mild left hemiparesis. In the subsequent months, she underwent staged, combined embolization and surgical resection of the AVM, with angiographically confirmed cure. At 15 months follow-up, she had retained a mild cerebellar syndrome, with left dysmetria and rotatory nystagmus.

DISCUSSION

Management of posterior fossa lesions is frequently complicated by hydrocephalus necessitating CSF diversion and increasing the risk of upward transtentorial herniation (UTH). Clinical deterioration following ventriculostomy in the setting of high posterior fossa intracranial pressure has been attributed to UTH.¹⁻³ The mechanism of clinical deterioration in UTH is debated: classically, the deterioration is a result of upwards mobilization of the superior vermis, which compresses the midbrain and pons. Alternatively, the cause of deterioration is asserted to be due to progression of the existent high pressure within the infratentorial compartment, and the upwards herniation is claimed to be an associated finding.⁴

The consequences of sudden upwards herniation, superimposed on the existing high pressure existing within the posterior fossa, are often dramatic and devastating: detailed angiographic images of this phenomenon are therefore uncommon, as surgical management of this condition mandates posterior fossa decompression, at least when the patient's clinical condition is not judged to be too dire. The images acquired in this case, after EVD insertion but before definitive surgical management, were made possible because of immediate access to interventional neuroradiology while the surgical team was mobilized for an urgent posterior fossa decompression. The urgent embolisation prior to craniectomy served to protect the proven friable SCA aneurysm from re-rupture during the decompressive precedure.

When posterior fossa craniectomy to decrease the localized intracranial pressure can be performed early enough, good outcomes can be attained.^{3,5} It is not uncommon to have normal pressure readings from ICP monitors in the supra-tentorial compartment co-existent with life-threatening infratentorial ICP. Finally, recognition of the angiographic signs of upward herniation of the vermis remains important; although in this case the poor status of the patient was known, in some cases angiographic recognition of this condition can be the only clue of intra-procedural vascular rupture within the posterior fossa.

CONCLUSION

Upwards transtentorial herniation is an uncommon, life-threatening event which is rarely captured at angiography. It is important to be able to recognize the angiographic features of UTH during an endovascular case, in order to initiate definitive treatment with surgical decompression.

REFERENCES

1. Cuneo RA, Caronna JJ, Pitts L, Townsend J, Winestock DP. Upward transtentorial herniation: seven cases and a literature review. *Arch Neurol.* 1979 Oct;36(10):618-23.
2. Ecker A. Upward transtentorial herniation of the brain stem and cerebellum due to tumor of the posterior fossa with special note on tumors of the acoustic nerve. *J Neurosurg.* 1948 Jan;5(1): 51-61.
3. Kase CS, Wolf PA. Cerebellar infarction: upward transtentorial herniation after ventriculostomy. *Stroke.* 1993 Jul;24(7):1096-8.
4. Fisher CM. Brain herniation: a revision of classical concepts. *Can J Neurol Sci.* 1995 May;22(2):83-91.
5. Yadav G, Sisodia R, Khuba S, Mishra L. Anesthetic management of a case of transtentorial upward herniation: An uncommon emergency situation. *J Anaesthesiol Clin Pharmacol.* 2012 Jul;28(3):413-15.