

# Treatment outcomes in patients with laryngotracheal lesions and compromised airway during and prior to the coronavirus disease 2019 pandemic: a tertiary institution's experience

## Main Article

Dr K Sandu takes responsibility for the integrity of the content of the paper

**Cite this article:** Gombert E, Ishii A, Guilcher P, Gorostidi F, Cantarella G, Pignataro L, Sandu K. Treatment outcomes in patients with laryngotracheal lesions and compromised airway during and prior to the coronavirus disease 2019 pandemic: a tertiary institution's experience. *J Laryngol Otol* 2021;**135**:897–903. <https://doi.org/10.1017/S0022215121002140>

Accepted: 11 July 2021

First published online: 13 August 2021

### Key words:

COVID-19; Laryngotracheal Stenosis; Tracheostomy

### Author for correspondence:

Dr K Sandu, Department of Otolaryngology, Lausanne University Hospital CHUV, Rue du Bugnon 46, Lausanne 1011, Switzerland  
E-mail: [kishore.sandu@chuv.ch](mailto:kishore.sandu@chuv.ch)

E Gombert<sup>1</sup>, A Ishii<sup>1</sup>, P Guilcher<sup>1</sup>, F Gorostidi<sup>1</sup>, G Cantarella<sup>2,3</sup>, L Pignataro<sup>2,3</sup> and K Sandu<sup>1</sup>

<sup>1</sup>Department of Otolaryngology, Lausanne University Hospital CHUV, Switzerland, <sup>2</sup>Department of Clinical Sciences and Community Health, University of Milan, Italy and <sup>3</sup>Department of Otolaryngology, Fondazione IRCCS Ca' Granda Ospedale Maggiore Policlinico, Milan, Italy

## Abstract

**Objective.** This study aimed to compare treatment outcomes in patients with laryngeal and tracheal stenosis treated during and prior to the coronavirus disease 2019 pandemic period.

**Method.** Patients treated for laryngotracheal lesions with impending airway compromise during the active pandemic period were matched with those treated for similar lesions in the preceding years in a monocentric tertiary hospital setting.

**Results.** During the pandemic period of 55 days, 31 patients underwent 47 procedures. Seven patients (2 children, 5 adults) had open airway surgery, and one had an operation-specific complication. Twenty-four patients (10 children, 14 adults) underwent 40 endoscopic interventions without any complications. Operation specific results during and prior to the pandemic were comparable.

**Conclusion.** The management strategy in patients with laryngotracheal lesions and impending airway compromise should not be altered during periods of risk from coronavirus disease 2019. Avoiding a tracheostomy by performing primary corrective surgery or proceeding with a definitive decannulation would be beneficial in these patients to reduce the risk of contagion.

## Introduction

Since the beginning of the year 2020, following the announcement of the novel coronavirus disease 19 (Covid-19) pandemic, the world has witnessed unprecedented events like global lockdowns, restrictions on international travel, closures of provincial borders and extreme measures of social distancing. In a way, the world came to a halt! In order to avoid overwhelming the hospital infrastructure in Switzerland, all non-emergent interventions were cancelled, and the authorities allowed only cancer, life-threatening emergent and trauma-related operations to be performed. In order to restrict the risk of hospital spread of the infection, various anaesthesia, surgery and intensive care experts issued best practice statements with regards to aerosol-generating procedures, such as head and neck oncology operations, tracheostomy and aero-digestive endoscopy.<sup>1–7</sup> There was a plethora of such publications, but they lacked clarity regarding the exact management of patients with severe laryngotracheal stenosis and similar cases who underwent operation just before the declaration of the pandemic.

Our clinic is a quaternary clinic specialising in managing patients with compromised airways and complex laryngotracheal stenosis. In this commentary, we share our unit's experience in managing patients with laryngotracheal lesions and airway compromise during the Covid-19 pandemic. Instead of temporising the airway compromise by performing a tracheostomy as advocated by some authorities,<sup>4,8</sup> we opted for definitive treatment of the lesion, which was similar to our practice followed prior to the pandemic. Here, we compare the surgical outcomes in patients who had complex laryngotracheal lesions treated during and prior to the pandemic period.

## Materials and methods

We retrospectively collected the data of all patients (paediatric and adult) who underwent endoscopic and open airway interventions for laryngotracheal lesions with airway compromise in our clinic from 11 March 2020 (the date when the World Health Organization (WHO) declared a pandemic) up to 5 May 2020 (55 days, corresponding to the pandemic wave period in our country). Following the WHO's announcement, the Lausanne University Hospital set up a task force to identify patients with significant airway problems who could need emergent or semi-emergent care during this critical period.

**Table 1.** Airway problems considered emergencies or semi-emergencies during the coronavirus disease 2019 outbreak

| Patient                      | Airway disorder   |
|------------------------------|---|
| Neonates                     | Ex utero intra-partum procedure for congenital high airway obstructive syndrome   |
| Infants and children         | Stridor with respiratory distress (bilateral vocal fold palsy, subglottic stenosis, glottic webs, tracheal stenosis)<br>Congenital malformations with failure to thrive (laryngomalacia)<br>Severe aspiration (laryngotracheoesophageal clefts, tracheoesophageal fistulas) |
| Adults                       | Severe dysphagia (Zenker's diverticulum) with airway compromise<br>Palliative airway stenting   |
| Infants, children and adults | Tracheostomy (for prolonged intubation, extubation failures)<br>Aero-digestive foreign bodies<br>Trauma (neck trauma, burns, inhalation, caustic injuries)<br>Deterioration of a compromised airway (past operated)<br>Peritonsillar and neck abscesses                     |

The airway disorders needing urgent treatment are reported in [Table 1](#). The senior author (K Sandu) performed all surgical procedures at his institution. We obtained institutional review board clearance for the study (reference number: 2020-01500 CER-VD) and appropriate patient consent.

All patients had routine clinical and blood checks prior to hospital admission. They underwent a chest X-ray and, in selected cases, a chest computed tomography scan. A nasopharyngeal swab was taken for severe acute respiratory syndrome coronavirus-2 (SARS-CoV-2) testing using the reverse transcriptase-polymerase chain reaction test, which was performed at least 48 hours prior to admission and on every occasion the patient was shifted to the operation room during the entire hospital stay. As per the guidelines of our institution as well as similar guidelines,<sup>1–3</sup> the healthcare providers underwent a reverse transcriptase-polymerase chain reaction examination only if he or she had symptoms of the viral infection. If they were positive, they quarantined for two weeks before returning to work.

Intra-operative protective measures and full personal protection equipment were used as per published guidelines.<sup>9,10</sup> The operation theatres, endoscopy suites and intensive care units observed strict policies to prevent nosocomial infection. Only the most experienced surgeons and anaesthesia, intensive care and nursing teams were involved in patient treatment. There were limited staff within the operating room during the entirety of the procedure to reduce contamination. All surgical instruments and suture materials needed for an open intervention were kept ready prior to the beginning of the surgery. Flexible and rigid endoscopes, aero-digestive stents, microlaryngoscopy and tracheo-broncho-esophagoscopy instruments were easily accessible during the intervention. In order to mitigate the risks of contagion, a runner assistant stayed in close proximity to the operating rooms in case of any special demands during the surgery. Diagnostic aero-digestive endoscopy was performed as per published recommendations.<sup>10</sup> Endoscopic interventions were performed with intermittent apnoea using age-appropriate cuffed endotracheal tube that was overinflated.

Operations involving laryngotracheal resection and anastomosis started with an oro- or naso-tracheal intubation. Intra-operative cross-field ventilation was made only when the patient had full muscle relaxation. The withdrawal of the tube (either naso-, oro- or trans-tracheal) was made during the expiratory phase of ventilation. Crico- or tracheo-tracheal anastomosis was performed under intermittent apnoea with all precautionary measures<sup>11–13</sup> to minimise aerosolisation. All adult patients were extubated in the operating room. At the end of the surgery and before extubation, the patient was

carefully shifted to a special mattress bed (Hill-Rom VersaCare P500®) with the head end raised to 30°. A Therakair® Visio-Arjo bed was used for children. In patients undergoing tracheal resection and anastomosis, we prefer complete bed rest for 7–10 days with the neck in the flexed position, and therefore a special bed is ideal to prevent bedsores.

Post-operative measures included no visits by family members for adult cases and allowing only one parent per child at any given time. Only the senior nursing and auxiliary staff cared for the patients. Post-operative patient care was as per the published protocols.<sup>11,12</sup>

Health surveillance of the healthcare providers during the study period was done as per our hospital's recommendations. Each healthcare provider watched himself or herself for fever, cough, generalised fatigue, smell and taste changes, and diarrhoea and had a reverse transcriptase-polymerase chain reaction test only in the presence of symptoms.

In this study, we included all patients aged between 0 and 90 years with a Covid-19 negative status on reverse transcriptase-polymerase chain reaction test, upper airway lesions with airway compromise, failure of previous measures to temporise an airway lesion and patients who had a recent laryngotracheal stenosis surgery with an indwelling airway stent. The exclusion criteria were Covid-19 positive status, head and neck squamous cell cancer, and patients with severe comorbidities who were unfit for general anaesthesia.

For each patient, we fixed the end point at getting a safe airway. The follow-up period was a minimum of three months following the surgery.

## Results

Details of open and endoscopic airway surgical procedures during the test period (first wave of 55 days in the year 2020) are mentioned in [Tables 2](#) and [3](#). [Table 4](#) shows the comparison of the above interventions with those that were done during similar months and giving the number of days in the two preceding years (2018 and 2019).

In the year 2020, 31 patients underwent 47 procedures. Seven patients (2 children and 5 adults) had an open airway surgery ([Figure 1](#)). One patient developed complications requiring further treatment. Twenty-four patients (10 children, 14 adults) underwent 40 endoscopic interventions, and none had complications. Sixteen patients (51.6 per cent) were referred from other regions or foreign countries; in these patients, pre- and post-operative endoscopy did not show abnormal airway reactivity that showed resistance to conservative management.

**Table 2.** Open airway surgery category

| Patient number, sex, age (years)                                     | Referral       | Pre-operative diagnosis   | Pre-operative endoscopy  | Surgery   | Follow-up status  |
|--|----------------|---|--|---|---|
| 1, female, 3.5   | International  | January 2019: alkaline battery ingestion. July 2019 (prior to referral): tracheoesophageal fistula closure with post-operative bilateral vocal folds palsy. Required endoscopic dilatation every 2 weeks for severe tracheal stenosis | Bilateral vocal folds palsy. Tracheal stenosis (70% obstruction, 4 rings, localised inflammation)            | Double-stage tracheal resection and anastomosis (6 rings excised)   | Decannulated and had an optimal age-appropriate airway. Normal oral solid and liquid feeds          |
| 2, male, 3   | Extra-cantonal | 23 weeks premature. January 2019: tracheostomy for severe posterior glottic stenosis. 11 February 2020: partial laryngofissure, posterior costal cartilage graft, laryngotracheal mold  | Laryngotracheal mold in optimal position   | Surgical closure of tracheostomy  | Optimal airway. Occasional mild aspiration  |
| 3, female, 78  | Cantonal       | Poorly differentiated (90% follicular) thyroid cancer (cT <sub>4</sub> a cN <sub>1</sub> b) right vocal fold hypomobility   | Infiltration of 2 tracheal rings. Trans-oesophageal ultrasound: muscles infiltrated, mucosa free             | Total thyroidectomy, selective neck dissection, single stage tracheal resection and anastomosis (3 rings), pectoralis major myofascial flap | Right vocal fold palsy, optimal airway, no aspiration, mild hoarseness, adjuvant chemo-radiotherapy |
| 4, male, 75<br>( <a href="#">Figure 1a–c</a> )                       | Cantonal       | Papillary thyroid cancer cT <sub>4</sub> a cNo, bilateral vocal folds mobile  | Infiltration of 3 tracheal rings. Transoesophageal ultrasound: oesophagus muscles infiltrated, mucosa spared | Total thyroidectomy, selective neck dissection, single stage tracheal resection and anastomosis (4 rings), pectoralis major myofascial flap | Bilateral vocal folds mobile, optimal airway, post-operative radioiodine I-131                      |
| 5, female, 31<br>( <a href="#">Figure 1d–g</a> )                     | International  | 2015: astrocytoma excision. January 2020: pneumonia, air ambulance transfer to our institution. February, March 2020: 2 temporising dilatations   | Tracheal stenosis (70% obstruction)  | Single stage tracheal resection and anastomosis (4 rings)   | Optimal airway, bilateral vocal folds mobile  |
| 6, male, 33  | International  | 2018: motor vehicle accident, paraplegia. Tracheostomy for severe posterior glottic stenosis. February 2020: laryngofissure, posterior costal cartilage graft, laryngotracheal mold   | Laryngotracheal mold in good position  | Surgical closure of tracheostomy  | Optimal airway. Feeds: normal without aspiration  |
| 7, female, 66<br>( <a href="#">Figure 1h</a> and <a href="#">i</a> ) | Extra-cantonal | 2008: motor vehicle accident, tracheostomy, paraplegia. 2008: decannulated. 2016: continuous positive airway pressure (24/7). February 2020: acute exacerbation   | Bilateral vocal folds mobile. Tracheal stenosis with severe A-frame deformity (90% obstruction, 3 rings)     | Single stage tracheal resection and anastomosis (4 rings)   | Optimal airway, bilateral vocal folds mobile  |

**Table 3.** Endoscopic airway surgery category

| Aero-digestive lesions   | Paediatric* (n)                           | Adult† (n) |
|--|---|------------|
| Respiratory distress   | 3 (2 foreign bodies, oesophageal atresia) | 1          |
| Laryngomalacia with failure to thrive                                    | 2   |            |
| Prolonged intubation with airway lesions                                 | 8   | 5          |
| Post-operative airway surgery  | 4   | 14         |
| Obstructive sleep apnoea syndrome  | 1   |            |
| Branchial arch cyst (4th arch with prior abscedation)                    | 1   |            |
| Extrinsic airway compression (tracheal stenting done for thyroid cancer) |   | 1          |
| Zenker's diverticulum with severe dysphagia                              |   | 1          |

\*n = 19; †n = 21

**Table 4.** Year-wise laryngotracheal stenosis interventions

| Year*                           | Open airway surgery (n) | Endoscopic airway surgery (n) |
|---------------------------------|-------------------------|-------------------------------|
| 2020                            |                         |                               |
| – Children                      | 2                       | 10                            |
| – Adults                        | 5                       | 14                            |
| – Total number of interventions | 7                       | 40                            |
| – Outstation† patients          | 5                       | 11                            |
| – Complications                 | 1                       | –                             |
| 2019                            |                         |                               |
| – Children                      | 5                       | 23                            |
| – Adults                        | 1                       | 12                            |
| – Total number of interventions | 6                       | 66                            |
| – Outstation patients           | 4                       | 26                            |
| – Complications                 | –                       | –                             |
| 2018                            |                         |                               |
| – Children                      | 3                       | 26                            |
| – Adults                        | 4                       | 10                            |
| – Total number of interventions | 7                       | 58                            |
| – Outstation patients           | 6                       | 24                            |
| – Complications                 | –                       | –                             |

\*11 March to 5 May (55 days); †outstation patients were either extra-cantonal or international

The surgery objectives in both groups (pandemic and pre-pandemic period) were: establish an optimal control over the airway disease and secure a safe airway, prefer a two-stage procedure in presence of comorbidities and attempt a single stage surgery in their absence. An existing tracheostomy was removed if the airway was found optimal and safe.

The operation specific success outcomes were similar in both groups. Tracheostomy was inserted in one child each in

the pandemic and pre-pandemic groups for a precarious airway that developed following single stage open surgery. In the 2020 group, a single stage procedure failed in patient number 1. She had an anastomotic dehiscence requiring tracheostomy and insertion of a Montgomery T-tube. The child was decannulated two months later.

No patient in 2020 received tracheostomy to temporise an airway compromise and thereby postpone the airway corrective surgery to a later date. Stent insertion rates and the indications to use them were identical in both groups. There were fewer endoscopic interventions performed in 2020 because of extreme travel restrictions. There were no deaths in any of the groups. At one year follow up, all patients who were operated on in the pandemic and pre-pandemic groups (Table 4) had a safe and age-appropriate airway. Differentiated thyroid cancer patients who underwent operations in 2020 were compared with those previously reported on by our group.<sup>13</sup> At one year follow up, all living patients were cancer free and had a safe airway.

Overall, 12 doctors (surgeons, anaesthesiologists, intensivists), 14 nurses (intensive care unit, operation theatre) and 21 auxiliary staff (endoscopy suite, operation rooms, intensive care units, wardrooms) were exposed to the patients and parents (Table 5). One surgeon tested positive prior to the study period and underwent two weeks of home quarantine. All other healthcare providers were asymptomatic during the entire study period. The infected surgeon and the healthcare providers underwent only clinical surveillance without additional swab and serology testing.

## Discussion

The first case of Covid-19 infection in Switzerland was reported on 25 February 2020, and the WHO declared the pandemic on 11 March 2020. All patients presenting to our hospital with airway lesions (Table 1) received treatment only after they tested negative for Covid-19 with a reverse transcriptase-polymerase chain reaction test. A single test was performed because of scarcity of testing means at that time; therefore, a Covid-19 positive status could not be confirmed.

A significant number of patients with impending airway compromise already have a tracheostomy or might need one with time. Additionally, to avoid a tracheostomy, these patients may need multiple endoscopic interventions to temporarily stabilise their airway. During the pandemic, organising a specialised nurse to make home visits for tracheostomy nursing or procure specific material for its care was difficult because of implementation of travel restrictions and lockdowns. Clearly, stress among parents with tracheostomised children and limited or no help is unimaginable.

During the Covid-19 pandemic wave period of 2020, two of the seven patients who underwent open interventions in our clinic had thyroid cancer with laryngotracheal invasion. Both underwent single stage total thyroidectomy and segmental tracheal resection and anastomosis with favourable airway and oncological results. Pectoralis major muscle flap was used to additionally reinforce the anastomosis and avoid the tracheal anastomotic suture line presenting directly under the subcutaneous tissue because the strap muscles were removed during the surgery. Such a flap offers the advantage of plugging a minor anastomotic dehiscence and preventing it from progressing into a complete breakdown. The surgical management of these complex patients and their outcomes were similar to

**Table 5.** Coronavirus disease 2019 infection status of the healthcare providers

| Healthcare provider  | Infection prior to the study period                 | Infection during the study period | Infection post-study and follow up |
|--|---|-----------------------------------|------------------------------------|
| Doctors*: surgeons, anaesthesiologists, paediatric intensive care unit     | 1 surgeon + (but was non-symptomatic after testing) | Non-symptomatic                   | Non-symptomatic                    |
| Support staff†: nurses, physiotherapists, dieticians, operating room staff | Non-symptomatic                                     | Non-symptomatic                   | Non-symptomatic                    |

\**n* = 12; †*n* = 35

patients our group had previously reported on in the pre-pandemic period.<sup>13</sup>

Tracheostomy is an aerosol generating procedure, and healthcare professionals are exposed to the risk of viral contagion during the surgery and subsequent care<sup>2</sup> despite adequate protective equipment against Covid-19. During the pandemic period, in patients with severe laryngotracheal stenosis, we preferred performing the definitive surgery instead of only using a tracheostomy as a temporary measure. In addition, for patients with a pre-existing tracheostomy, we favoured closing it if the airway was found optimal and safe. The objective was to reduce the number of aerosol-generating patients in the community and thus the infection spread. This would also lower the chances of recurrent lower airway infections in these patients and their possible hospitalisations.<sup>14</sup>

Three patients (2 adults and 1 child) had benign laryngotracheal stenosis, an unstable airway and were without tracheostomy. One of these patients (patient 5) had a dramatic intubation injury prior to her transfer to our unit from abroad. We tried to find a temporary solution for the intubation injury, but the patient developed progressive recurrence of her severe stenosis. The other adult patient (patient 7) had a severe A-frame tracheal deformity, was dependent on non-invasive ventilation (continuous positive airway pressure) 24 hours a day and had progressive exacerbation of her symptoms during the pandemic. Both patients did well after a single stage tracheal resection and anastomosis. The child (case number 1) had an alkaline battery-induced tracheoesophageal injury and had undergone repair in her country which caused bilateral vocal fold palsy prior to her referral to us. She had a rough post-operative period and dehiscence of the anastomosis. Her tracheal stenosis was complicated by an existing glottic incompetence and should have been managed in two stages. In her case, aspiration because of laryngeal palsy, exaggerated because of the sedation in the post-operative period, caused infection at the anastomotic site and pneumonia that led to breakdown of the anastomosis. We contemplated our decision to perform a tracheal resection and anastomosis and wondered if a slide tracheoplasty would have been a better option for her. We feel that tracheal resection and anastomosis allowed us to remove the diseased trachea and hence nullify the chances of a recurrence in the presence of subclinical micro-aspiration that she might still have secondary to the glottic palsy. Slide tracheoplasty would have reduced chances of a dehiscence and saved the airway length but could still have carried a significant risk of re-stenosis.

Two patients (1 adult and 1 child) had undergone surgery for benign laryngotracheal stenosis just before the national and international lockdowns were announced in Europe. They both had an indwelling stent, and therefore its removal was thought to make the airway safer. Their airway was found to be adequate after stent removal, and therefore both patients

underwent a successful decannulation. No patient undergoing endoscopic interventions during the pandemic and the previous years had complications. Proper case selection, meticulous execution of the endoscopic procedure(s) and optimal intra- and post-operative airway management are crucial to avoid complications.

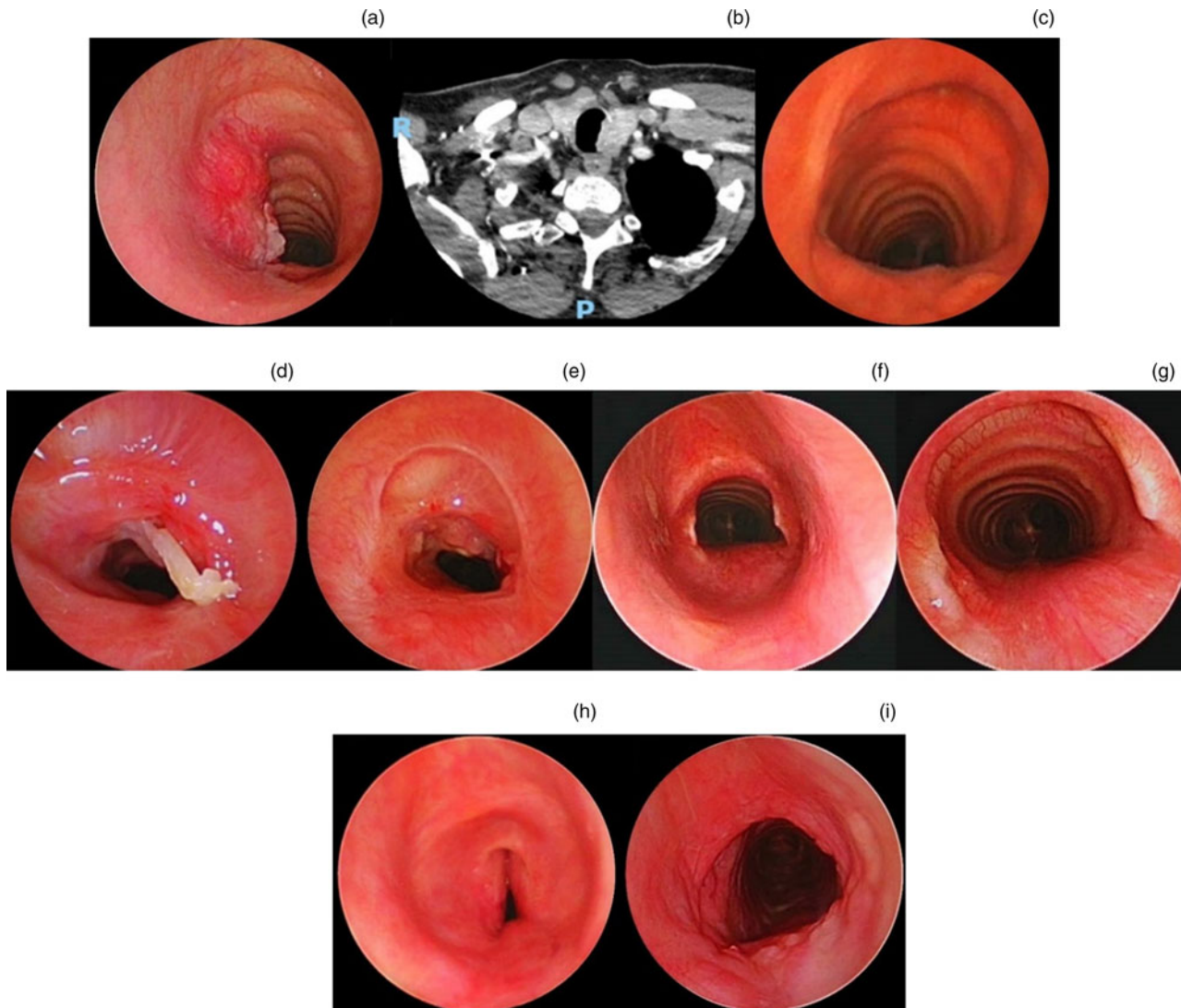
All healthcare providers recruited in this report were asymptomatic during the entire study period, and therefore were not specifically virus tested as per institutional guidelines. In-patient hospital visits by family members were kept minimal. Individual hygiene, sanitisation and social distancing were strictly followed, and this kept the hospital's nosocomial infection rates low.

This commentary on airway surgery during the Covid-19 pandemic has several limitations. It presents a single institution's anecdotal experience involving a limited number of heterogeneous patient groups. Nevertheless, patients with laryngotracheal airway compromising conditions are rare and require specialised treatment that can be difficult in a pandemic situation. Our treatment strategy did not change during the pandemic, and the outcomes were similar in patients treated in the years prior to the pandemic and during the pandemic. Rather than temporising the airway stenosis with a tracheostomy as preferred by some authors,<sup>4</sup> a primary surgery reduced aerosolisation and the overall treatment time to achieve a safe airway. It also avoided the need for specialised tracheostomy care that would have been difficult to organise because of the travel restrictions. Similar studies involving multiple centres and including larger patient cohorts would be an interesting topic for future publications. The patients described in our case series were all SARS-CoV-2 negative, although there is always a possibility of false negatives. A skilled team is strictly necessary to definitively treat the airway stenosis and thus avoid infection spread in the event of patients getting a positive test in the future. In SARS-CoV-2 positive patients with laryngotracheal stenosis, we propose early treatment as soon as the patient is deemed fit for surgery.

- Standard operating protocols during the pandemic proposed temporising the airway compromise to avoid aerosol generation
- Laryngotracheal lesions with impending airway compromise were hypothesised to be better treated by a primary single stage surgery
- Treatment outcomes in the pandemic were comparable to prior years
- During the pandemic period, definitive operations are more beneficial in this patient group

Our case series proves that adequate care of patients with laryngotracheal stenosis was feasible during the critical wave period of the Covid-19 infection and was safe for the patients and the healthcare professionals. The outcomes in patients who underwent operations in the pandemic year 2020 and those during the pre-pandemic periods (2018 and 2019)<sup>13</sup>





**Fig. 1.** (a) Endoscopic view showing T<sub>4</sub> papillary thyroid cancer with laryngotracheal invasion. (b) Axial computed tomography scan of the neck showing tumour invasion of the proximal trachea. (c) Endoscopic view showing post-single stage total thyroidectomy and segmental tracheal resection and anastomosis. (d) Endoscopic view showing third tracheal ring showing cartilage fracture following endotracheal tube tip injury. (e) Endoscopic view one week following endoscopic treatment showing recurrence of stenosis. (f) Endoscopic view showing the airway at eight weeks following segmental tracheal resection and cricotracheal anastomosis. (g) Endoscopic view at eight weeks showing a closer view of an optimally healed and fully mucosalised airway. (h) Endoscopic view showing pre-operative endoscopy showing severe A-frame deformity and 90 per cent tracheal obstruction. (i) Endoscopic view showing post-single stage segmental tracheal resection and anastomosis.

were found comparable. None of the patients who underwent operations during the pandemic period showed additional airway reactivity, which is something that can alter the surgical results. Complications during the pandemic period were because of incorrect decision-making and unrelated to the prevailing external factors. The strict respect of expert recommendations in both the operating theatre and the post-operative period minimises the risks related to viral transmission during endoscopic and open airway surgery.

### Conclusion

Adequate treatment of critical airway stenosis can be safely achieved during Covid-19 pandemic periods if strict rules and optimal caution are observed during surgery and in the post-operative period. The management strategy for these patients should not be different in the pandemic period in comparison to the previous years, and care by an expert team is crucial.

**Competing interests.** None declared

### References

- 1 Brewster DJ, Chrimes N, Do TB, Fraser K, Groombridge CJ, Higgs A *et al.* Consensus statement: Safe Airway Society principles of airway management and tracheal intubation specific to the COVID-19 adult patient group. *Med J Aust* 2020;**212**:472–81
- 2 Tran K, Cimon K, Severn M, Pessoa-Silva CL, Conly J. Aerosol generating procedures and risk of transmission of acute respiratory infections to healthcare workers: a systematic review. *PLoS One* 2012;**7**:e35797
- 3 Michetti CP, Burlew CC, Bulger EM, Davis KA, Spain DA. Critical Care and Acute Care Surgery Committees of the American Association for the Surgery of Trauma. Performing tracheostomy during the Covid-19 pandemic: guidance and recommendations from the Critical Care and Acute Care Surgery Committees of the American Association for the Surgery of Trauma. *Trauma Surg Acute Care Open* 2020 **15**;5:e000482
- 4 Smith JD, Chen MM, Balakrishnan K, Sidell DR, Di Stadio A, Schechtman SA *et al.* The difficult airway and aerosol-generating procedures in COVID-19: timeless principles for uncertain times. *Otolaryngol Head Neck Surg* 2020;**163**:934–7
- 5 Prince ADP, Cloyd BH, Hogikyan ND, Schechtman SA, Kupfer RA. Airway management for endoscopic laryngotracheal stenosis surgery during COVID-19. *Otolaryngol Head Neck Surg* 2020;**163**:78–80
- 6 Miles BA, Schiff B, Ganly I, Ow T, Cohen E, Genden E *et al.* Tracheostomy during SARS-CoV-2 pandemic: recommendations from the New York Head and Neck Society. *Head Neck* 2020;**42**:1282–90

- 7 McGrath BA, Brenner MJ, Warrillow SJ, Pandian V, Arora A, Cameron TS *et al.* Tracheostomy in the COVID-19 era: global and multidisciplinary guidance. *Lancet Respir Med* 2020;**8**:717–25
- 8 Shuman AG. Navigating the ethics of COVID-19 in otolaryngology. *Otolaryngol Head Neck Surg* 2020;**162**:811–12
- 9 Booth CM, Matukas LM, Tomlinson GA, Rachlis AR, Rose DB, Dwosh HA *et al.* Clinical features and short-term outcomes of 144 patients with SARS in the greater Toronto area. *JAMA* 2003;**289**:2801–9
- 10 Kim HJ, Ko JS, Kim TY. Recommendations for anesthesia in patients suspected of COVID-19 coronavirus infection. *Korean J Anesthesiol* 2020;**73**:89–91
- 11 Monnier P. *Pediatric Airway Surgery, Management of Laryngotracheal Stenosis in Infants and Children*. Berlin Heidelberg: Springer-Verlag, 2011
- 12 Grillo HC. *Surgery of the Trachea and Bronchi*. Shelton: PMPH, 2004
- 13 Morisod B, Monnier P, Simon C, Sandu K. Cricotracheal resection for laryngeal invasion by thyroid carcinoma: our experience. *Eur Arch Otorhinolaryngol* 2014;**271**:2261–6
- 14 Russell CJ, Simon TD, Mamey MR, Newth CJL, Neely MN. Pseudomonas aeruginosa and post-tracheotomy bacterial respiratory tract infection readmissions. *Pediatr Pulmonol* 2017;**52**:1212–18