

# Visualization of $^{90}\text{Y}$ trium Colloid Within a Cystic Craniopharyngioma Using PET/CT/MRI Fusion

Steven Burrell, Andrea L.O. Hebb, Syed Ali Imran, Aditya Mishra, George Mawko, David B. Clarke

**Keywords:** Magnetic resonance imaging, Neurosurgery, PET scanning, Pituitary tumor, Stereotactic surgery, Tumors, Tumor imaging

doi:10.1017/cjn.2016.410

Can J Neurol Sci. 2017; 44: 192-193

Untreated expansion of cystic craniopharyngiomas can have significant consequences from mass effect including worsening headache, vision loss, and obstructive hydrocephalus. Conventional surgical treatments include attempted resection, typically via craniotomy. Less invasive aspiration of cystic contents only provides a temporary solution, with cysts tending to refill and expand after a single drainage.<sup>1</sup> The beneficial effects of intracavitary irradiation for treatment of cystic craniopharyngiomas as a means to abolish the secretory capability of the cyst's epithelial lining, while sparing nearby critical brain structures, has been previously reported.<sup>2-4</sup>

$^{90}\text{Y}$ trium colloid is considered a suitable isotope for treatment of cystic craniopharyngiomas because of its short half-life and pure  $\beta$  emission.<sup>1,2</sup> Intracavitary irradiation with stereotactically implanted  $^{90}\text{Y}$ trium colloid has been shown to be effective in long-term shrinkage of the cystic portion of recurrent craniopharyngiomas. A retrospective review of 78 patients over a 36-year period showed sustained cyst reduction in 63% of patients following  $^{90}\text{Y}$ trium colloid treatment, with 33% of cysts disappearing completely.<sup>2</sup> The administered dose is calculated based on delivering 200 Gy to the inner wall of the cyst.<sup>1,5</sup> Although radiation delivery into the cyst using a stereotactically guided needle had been previously outlined in Pollack et al,<sup>3</sup> imaging techniques to demonstrate the ongoing intracystic radiation have not been previously described. Although Bremsstrahlung single-photon emission computed tomography/computed tomography (CT) can be used to image the activity distribution after administration of  $^{90}\text{Y}$ trium colloid, positron emission tomography (PET)-CT has become the preferred modality in the brain because of higher spatial and energy resolution.<sup>6</sup> In this report, we demonstrate the use of PET-CT imaging, fused to anatomic CT and magnetic resonance imaging (MRI), as a means of documenting the actual distribution of  $^{90}\text{Y}$ trium colloid delivered to the cystic craniopharyngioma.

## METHODS

As part of a Health Canada Phase III clinical trial (NCT02081768), informed consent was obtained from patients treated with  $^{90}\text{Y}$ trium colloid for a suprasellar cystic craniopharyngioma (surgical methods described elsewhere<sup>3</sup>) to undergo PET-CT 24 to 48 hours postoperatively. PET-CT was performed on a Discovery *STE16* camera (*General Electric Medical Systems, Milwaukee, WI*), to delineate the distribution of the  $^{90}\text{Y}$ trium colloid within the cyst. Although  $^{90}\text{Y}$ trium is primarily a beta emitter and does not directly emit radiation amenable to

imaging, it decays to  $^{89}\text{Zr}$ irconium, which emits a positron/electron pair, making it possible to image the radioisotope with a PET-CT scanner. Images were coregistered with MRI done on the same day. PET imaging consisted of one bed position (15 cm) centered on the sella, in 3 dimensions, 20 minutes, Vue point algorithm, 128 × 128 matrix. Given the lack of anatomic reference on the PET scan, a low-dose CT scan was performed at the same time with a helical scan (0.8 seconds), 3.75-mm slice thickness, 140 kV, 95 mA, and 512 × 512 matrix. The reconstructed  $^{90}\text{Y}$ trium colloid PET voxels have a spatial resolution of approximately 12 mm full width half maximum; the spatial correspondence between the PET and CT scans is less than 5 mm, the approximate size of one PET voxel. The CT provided anatomical landmarks and was used to facilitate attenuation correction of the PET data. PET/CT and MRI scans were coregistered using Statistical Parametric Mapping software (SPM5, Wellcome Trust Centre for Neuroimaging) and fused images displayed using Rview (version 9.073, Colin Studholme).

## RESULTS

The images shown in Figure 1 are from a patient treated with  $^{90}\text{Y}$ trium colloid for a suprasellar cystic craniopharyngioma as part of the trial. PET imaging data have been fused to both anatomical CT (top) and MRI (middle) scans.

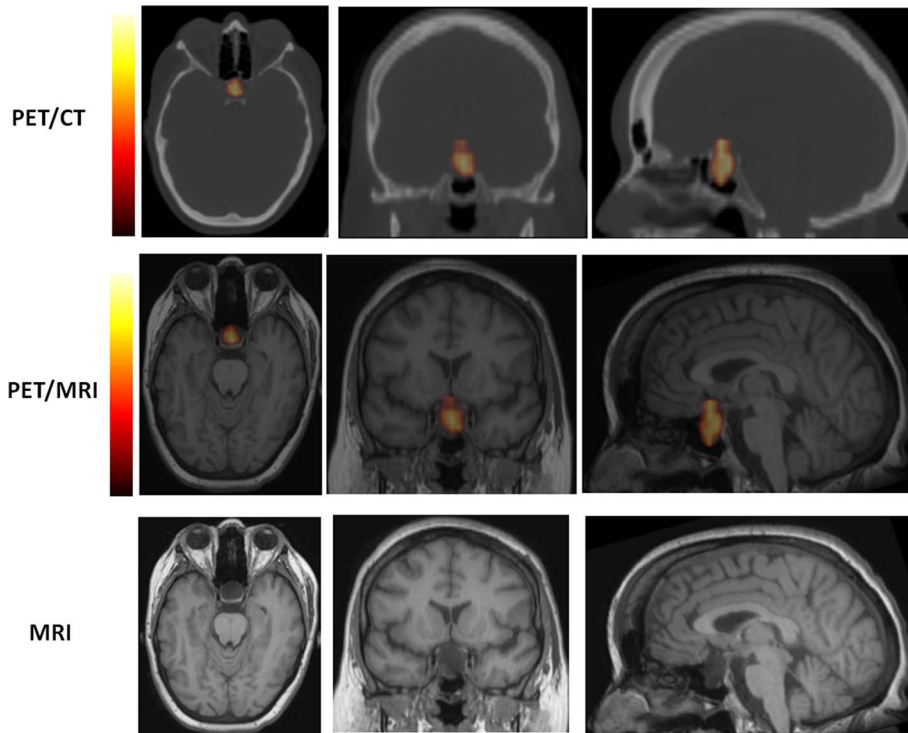
## CONCLUSIONS

We have used PET-CT imaging to characterize the distribution of  $^{90}\text{Y}$ trium colloid delivered to a cystic craniopharyngioma. Image fusion to anatomical imaging (CT and/or MRI) confirms successful injection into the target site, assesses the distribution of  $^{90}\text{Y}$ trium colloid within all of the cyst, and may provide a means

From the Department of Diagnostic Radiology, Dalhousie University, QEII Health Sciences Centre, Halifax, Nova Scotia, Canada (SB, GM); Halifax Neuroepituitary Program, Dalhousie University, QEII Health Sciences Centre, Halifax, Nova Scotia, Canada (ALOH, SAI, DBC); Division of Neurosurgery, Dalhousie University, QEII Health Sciences Centre, Halifax, Nova Scotia, Canada (ALOH, DBC); Division of Endocrinology, Dalhousie University, QEII Health Sciences Centre, Halifax, Nova Scotia, Canada (SAI, DBC); Department of Ophthalmology & Visual Sciences, Dalhousie University, QEII Health Sciences Centre, Halifax, Nova Scotia, Canada (AM, DBC).

RECEIVED JULY 14, 2015. FINAL REVISIONS SUBMITTED APRIL 28, 2016. DATE OF ACCEPTANCE JUNE 14, 2016.

Correspondence to: David B. Clarke, Department of Surgery (Neurosurgery), Dalhousie University, QEII Health Sciences Centre, Halifax, NS, B3H 3A7.  
E-mail: d.clarke@dal.ca.



**Figure 1:** PET/CT and PET/MRI fusions are presented for visualization of  $^{90}\text{Y}$ trium colloid within a suprasellar cystic craniopharyngioma. The distribution and accumulation of radiopharmaceutical within the multilobulated cystic craniopharyngioma is visualized by the positron-emitting radioisotope properties of  $^{90}\text{Y}$ trium colloid. Based on the 5.7cc volume of the cystic component of the craniopharyngioma, 50.0MBq of  $^{90}\text{Y}$ trium colloid was injected into the cyst via a stereotactic transcranial approach. Top row: PET imaging data fused to CT (axial, coronal, and sagittal images). Middle row: PET imaging data fused to MRI. Bottom row: Corresponding MRI images.

to evaluate leakage of  $^{90}\text{Y}$ trium colloid. Further studies will determine whether PET/CT/MRI proves useful in predicting short- and long-term treatment responses.

#### ACKNOWLEDGMENTS

We acknowledge Ron Hill for his help with processing imaging data and Murray Hong, Jonathan Bower, Nichole Smith, and Christina Kelly for their help in preparations for the surgical procedure.

#### DISCLOSURES

The authors do not have anything to disclose.

#### REFERENCES

1. Blackburn TP, Doughty D, Plowman PN. Stereotactic intracavitary therapy of recurrent cystic craniopharyngioma by instillation of  $^{90}\text{Y}$ trium. *Br J Neurosurg.* 1999;13:359-65.
2. Julow JV. Intracystic irradiation for craniopharyngiomas. *Pituitary.* 2013;16:34-45.
3. Pollock BE, Lunsford LD, Kondziolka D, Levine G, Flickinger JC. Phosphorus-32 intracavitary irradiation of cystic craniopharyngiomas: current technique and long-term results. *Int J Radiat Oncol Biol Phys.* 1995;33:437-46.
4. Vanhauwaert D, Hallaert G, Baert E, Van Roost D, Okito JP, Caemaert J. Treatment of cystic craniopharyngioma by endocavitary instillation of yttrium $^{90}$  radioisotope—still a valuable treatment option. *J Neurol Surg A Cent Eur Neurosurg.* 2013;74:307-12.
5. Backlund EO, Johansson L, Sarby B. Studies on craniopharyngiomas. II. Treatment by stereotaxis and radiosurgery. *Acta Chir Scand.* 1972;138:749-59.
6. Zade AA, Rangarajan V, Purandare NC, et al.  $^{90}\text{Y}$  microsphere therapy: does  $^{90}\text{Y}$  PET/CT imaging obviate the need for  $^{90}\text{Y}$  Bremsstrahlung SPECT/CT imaging? *Nucl Med Commun.* 2013;34:1090-6.