

Chronic, treatment-resistant depression and right fronto-striatal atrophy

P. J. SHAH, M. F. GLABUS, G. M. GOODWIN and K. P. EBMEIER

Background Treatment-resistant depression (TRD) is relatively common but its neurobiological basis is poorly understood. Fronto-striatal structural brain changes have been reported in patients with depression but their association with treatment resistance and chronicity has not been established.

Method Magnetic resonance images of 20 patients with TRD were compared with images of 20 recovered patients and 20 healthy controls. Images were compared using a voxel-based analysis (VBA) method; the results were validated by conventional volumetric analysis. The clinical associations of magnetic resonance imaging (MRI) changes with illness duration and severity were examined by VBA.

Results Only the TRD group exhibited right fronto-striatal atrophy, and subtle MRI changes in the left hippocampus on VBA. Atrophy was confirmed on volumetric analysis, the degree correlating with the cumulative number of electroconvulsive therapy (ECT) treatments received, suggesting an acquired deficit.

Conclusions This is the first study to demonstrate fronto-striatal atrophy in patients with depression with poor outcome; the atrophy is more marked in those with more severe illness.

Declaration of interest Support from the Royal College of Physicians (Edinburgh) and the Medical Research Council Brain Metabolism Unit.

Up to 20% of middle-aged patients with depression attending a psychiatrist follow a treatment-resistant course lasting more than 2 years (Keller *et al*, 1982; Scott, 1988). Treatment-resistant depression (TRD) is associated with a longer duration of illness before treatment (Keller *et al*, 1984; Scott, 1988) and a substantially reduced rate of recovery after the first 2 years of illness (Keller *et al*, 1982, 1984). Such patients are presumably the most likely to show structural brain changes. The most consistent structural findings from studies of mixed-outcome patients with depression are frontal and striatal atrophy (Soares & Mann, 1997), but it has not been established whether or not these changes are related to outcome. Previously we have used voxel-based analysis (VBA) to compare magnetic resonance imaging (MRI) grey matter segments between middle-aged patients with TRD, patients who had recovered from depression and normal healthy volunteers (Shah *et al*, 1998). Patients with TRD had reduced grey matter density in the frontal and temporal cortex, including the hippocampus. Additionally, reduced hippocampal grey matter density was correlated with verbal memory impairment, implying an association between observed change and function. It is not possible to be sure whether VBA changes represented atrophy or just changes in voxel intensity. This required examination by traditional volumetry and will be described here.

METHOD

Subjects

Twenty patients aged between 21 and 65 years who fulfilled DSM-IV (American Psychiatric Association, 1994) criteria for major depressive disorder (chronic), research diagnostic criteria (RDC; Endicott & Spitzer, 1978) for a primary major depressive disorder and were also treatment

resistant, were recruited from general adult in-patient units and from out-patient clinics in the south-east of Scotland. With this selection we endeavoured to maximise our chances of identifying structural brain changes. All subjects gave written informed consent following a protocol approved by the local research ethics committee prior to participation. Chronicity was defined as meeting DSM-IV diagnostic criteria for a major depressive episode for at least 2 years (American Psychiatric Association, 1994). Treatment resistance was defined as non-responsiveness to at least two treatments from different pharmacological groups employed for at least 4 weeks each at the following doses:

- (a) at least 150 mg of imipramine or an equivalent tricyclic antidepressant;
- (b) at least 60 mg of phenelzine or an equivalent monoamine oxidase inhibitor;
- (c) at least 40 mg of fluoxetine or an equivalent selective serotonin reuptake inhibitor;
- (d) at least six treatments with electroconvulsive therapy (ECT) with seizures lasting longer than 20 s each.

In reality, all patients exceeded the minimum criteria for treatment resistance. Many were on multiple and/or combination treatments. All patients were on a stable medication regime for at least 2 weeks prior to the study. Patients had not received ECT for at least 3 months prior to the study and had no history of intracranial pathology or surgery.

Twenty recovered patients who previously fulfilled DSM-IV criteria for a major depressive disorder and 20 normal healthy volunteers with no lifetime history of psychiatric illness were also examined. Subjects from both of these groups were individually matched with patients with TRD for age, gender, premorbid IQ and years of education. Recovered patients were matched for age of onset and for onset of the index episode with the treatment-resistant group. The recovered group all had had severe illness episodes (details below). Recovery was defined as scoring 5 or less on the Hamilton Rating Scale for Depression (HRSD; Hamilton, 1960) for at least 3 months prior to the study, and subjects were either medication-free or on stable medication for at least 2 weeks prior to the study.

Clinical assessment

All subjects were interviewed using the lifetime version of the Schedule for Affective Disorders and Schizophrenia (SADS-L; Endicott & Spitzer, 1978). All available psychiatric case notes were reviewed in detail, providing RDC diagnoses and allowing lifetime histories of psychiatric illness and treatment histories to be reconstructed. The total number of hospitalisations, cumulative length of psychiatric hospitalisation and cumulative number of ECT treatments were used as indices of cumulative illness severity. Estimated total lifetime illness duration was derived from psychiatric case-note histories. Healthy volunteers had no lifetime history of significant psychiatric illness, established by the SADS-L interview schedule.

Exclusion criteria were previous manic episodes, other organic cerebral pathology, significant alcohol or substance misuse, head injury associated with significant loss of consciousness, or concurrent use of steroids.

All subjects had standardised neuropsychological and clinical testing within 1 day of each other and within 1 week of the MRI. Symptom severity was measured using the HRSD, the severity of psychomotor retardation was measured using the observer-rated Widlöcher Scale (Widlöcher, 1983) and cerebral dominance was measured with a handedness scale (Annett, 1970). Subjects also performed the revised National Adult Reading Test (Nelson & Willison, 1991), which estimated premorbid IQ.

Magnetic resonance image acquisition

Subjects were imaged within 1 week of clinical assessment. Images were acquired on a 1.0 Tesla Siemens Magnetom SPE system, with subjects undergoing a magnetisation-prepared rapid-acquisition-graded echo (MPRAGE) sequence, acquired perpendicular to a line connecting the anterior and posterior commissure (AC-PC). This yielded high-resolution T1-weighted images with good contrast between white and grey matter (repetition time=10 ms, delay time=500 ms, inversion time=200 ms, flip angle=12°, block size=240 mm, 128 contiguous slices with an effective slice thickness of 1.875 mm).

Voxel-based analysis

Image analysis was performed on a SPARC workstation (Sun Microsystems Europe Inc., Surrey, UK) using ANALYZE software (version 7.5.5, 1995; Biomedical Imaging Resource, Mayo Foundation, Rochester, Minnesota, USA), and SPM'96 software for spatial normalisation and statistical parametric mapping (Wellcome Functional Imaging Laboratory, Institute of Neurology, Queen Square, London, UK), running in MATLAB (version 4.2c, 1994; The Mathworks Inc., Natick, Massachusetts, USA). The technique is fully described by Shah *et al* (1998). An ANCOVA model was applied, removing the global density of each tissue compartment for each subject. Differences between groups were displayed as statistical parametric maps (SPMs), with a 1% threshold probability. Statistical clusters were also projected onto the T1-weighted grey matter density template to facilitate interpretation of the results. Corrected probability values take into account the volume examined, the smoothness of the data, the size of the cluster with $P < 0.01$ and the peak effect (Z value).

Volumetric analysis

Images were analysed using ANALYZE (CNS Software) running on a Unix-based Sun workstation (Sun Microsystems). Images initially were converted to 8-bit images. The threshold voxel intensity between grey matter and cerebrospinal fluid (CSF) was ascertained. Tissue below this threshold (surrounding CSF) and exterior to this rim of CSF (skull, scalp and meninges) was excluded. Meningeal tissue abutting on cerebral tissue was removed manually using an anatomical atlas as a guide. Within ANALYZE, images were corrected for minor degrees of tilt, roll and yaw. Partial volume effects at the exterior edge of cerebral tissue were removed using a 1-bit image template multiplier, re-orientated in an identical manner to the original image using nearest-neighbour interpolation. Total cerebral volume thus remained unchanged after re-orientation.

Landmarks used to delineate cerebral structures

The landmarks defined by Shenton *et al* (1992) and Suddath *et al* (1990) were used as a guide to dissection. The criteria used

are available from the authors upon request. The hippocampus was divided into anterior and posterior portions, using the mamillary bodies as a landmark. No attempt was made to measure amygdala volume separately. Caudate and putamen were measured bilaterally, as was pre-frontal tissue, 'posterior frontal' tissue and the temporal lobes.

Segmentation of magnetic resonance images

Two investigators received training to identify landmarks accurately and to segment images reliably into object maps. A third investigator then removed identifying information from the magnetic resonance images. He randomly chose half of the images from each subject group to be mirrored in the midsagittal plane so that the left and right sides were exchanged. The two investigators who segmented the magnetic resonance images were thus blind to left-right orientation and the diagnostic group of the images. Each investigator independently analysed the images from half of the total subjects. Five random images were analysed independently by both investigators, allowing a measurement of interrater reliability. One of the investigators performed a repeat analysis of the same five images 2 months later, producing a measure of intrarater reliability. One-tailed t -tests were used (SPSS for Macintosh, version 4.0) because the direction of change was predicted, and no correction for multiple comparison was used because there were specific hypotheses about the regions expected to show volumetric reductions in patients with TRD. Because the total cerebral tissue volume did not differ between the three groups, controlling for total cerebral volume was not required.

Group demographics and clinical data were compared using univariate analysis of variance and *post hoc* independent t -tests to identify specific group differences. Non-continuous variables were compared using the Mann-Whitney U and χ^2 tests, with correlations made using Spearman non-parametric correlation as appropriate. Data reduction was done with the appropriate programs of SPSS 10.0 for Windows.

RESULTS

The three groups did not differ in age, gender, handedness, years of education or

the total number of years smoking (Table 1). The mean age of onset of the first and most recent and the lifetime number of depressive episodes did not differ between the TRD and recovered groups. The TRD group had longer current episode and total duration of illness and had longer total and a greater number of hospitalisations.

All TRD patients were taking anti-depressant drugs. Additionally, twelve patients took regular neuroleptic medication, five took lithium and three took benzodiazepines. Eleven patients in the recovered group were medication-free. Nine of the recovered patients were prescribed antidepressants; one also received neuroleptics and one lithium.

Both the patients with TRD and the recovered patients had, or previously had, melancholic depressive episodes. The TRD group had endogenous symptoms as measured by the Newcastle Scale (Carney *et al*, 1965) and fulfilled the DSM-IV criteria for a depressive episode with melancholic features (American Psychiatric Association, 1994). The recovered patients also previously fulfilled DSM-IV criteria for having depressive episodes with melancholic features.

The TRD group had moderately severe depressive symptoms and psychomotor retardation. Although not clinically depressed, the recovered patients had

significantly more depressive symptoms and more observable motor retardation than the controls.

Voxel-based analysis

The three-group comparison of increases and decreases in each of the three tissue compartments yielded 18 SPMs. Only the TRD group had changes in all three tissue compartments in comparison with the other two groups. Because the areas of differences were virtually identical when comparing the TRD group with controls and recovered patients, and because there was no significant tissue difference between the recovered group and the controls, the TRD group was compared against the pooled recovered and control groups.

Limbic and striatal changes in compartmental densities in TRD

The TRD group had reduced tissue density in the right putamen and a corresponding increase in right lateral ventricular CSF overlying the right striatum, not reaching statistical significance because of the small volumes involved but complementing the volumetric analysis. In addition, a pattern of reciprocal grey matter reductions with overlapping apparent white matter increases was found in bilateral hippocampal and parahippocampal areas, particularly anteriorly, and more markedly on the left

(Fig. 1), upon VBA but not volumetric analysis. Reciprocal changes in grey and white matter, with no increase in CSF, suggest that volumetric change in these areas will not be detected easily.

Cortical change (Fig. 1)

The TRD group had reduced grey matter density in the right superior frontal gyrus, with large reductions in white matter density in the right medial and superior frontal gyri. There were corresponding large CSF increases over the right medial and supero-frontal cortex (see Table 2). These changes predict right prefrontal atrophy in volumetric analysis. The large grey matter density reductions in the left superior and medial temporal gyri did not have associated CSF changes, suggesting that this change would not be detected by volumetry. Finally, an unpredicted finding upon VBA was increased grey matter density in the left cuneus, precuneus and lingual gyrus in the TRD group, with a lesser increase in bilateral cerebellar grey density (see Shah *et al*, 1998).

Volumetric object mapping

The TRD patients had less right prefrontal lobe tissue than controls (65.18 cm³ *v.* 71.17 cm³, $t = -2.34$, $P = 0.012$, effect size = 0.74) and less right caudate tissue than both controls (3.51 *v.* 3.77 cm³,

Table 1 Group comparisons, with standard deviation (s.d.) in parentheses ($n = 20$)

Parameter	Treatment-resistant depression group	Recovered group	Controls	$F_{(2,57)}$ (probability) or t -test (probability for two-group comparisons ¹)	Post-hoc t -test
Mean age	48.9 (9.8)	47.7 (9.9)	49.3 (11.8)	0.89	
Male:female ratio	13:7	13:7	13:7		
Handedness score	13 (16)	16 (13)	19 (5)	0.27	
Years of education	11.7 (2.9)	13.4 (3.4)	13.5 (2.9)	0.12	
NART IQ	107 (12.7)	113 (10.2)	115 (8.7)	0.06	TRD = RD TRD < C
HRSD score	20.6 (5.3)	2.6 (1.7)	0.2 (0.7)	< 0.0001	TRD > RD > C
Widlöcher score	26.1 (8.6)	2.2 (3.6)	0.3 (0.7)	< 0.0001	TRD > RD > C
Total years smoking	20 (13.6)	12 (13.7)	17 (3.7)	0.14	
Age of onset of first episode	38.9 (13.5)	38.2 (10.1)		0.89	
Age of onset of last episode	45.8 (10.1)	44.8 (9.8)		0.76	
Total number of episodes	2.2 (1.4)	2.5 (1.9)		0.52	
Longest duration of episode (weeks)	197 (125)	46 (36)		< 0.001	
Lifetime total illness duration (weeks)	263 (133)	76 (58)		< 0.001	
Total number of hospitalisations	3.8 (5.3)	1.3 (1.2)		0.05	

NART, National Adult Reading Test; HRSD, Hamilton Rating Scale for Depression.

1. The two patient groups are compared where no data were available for controls (last six parameters).

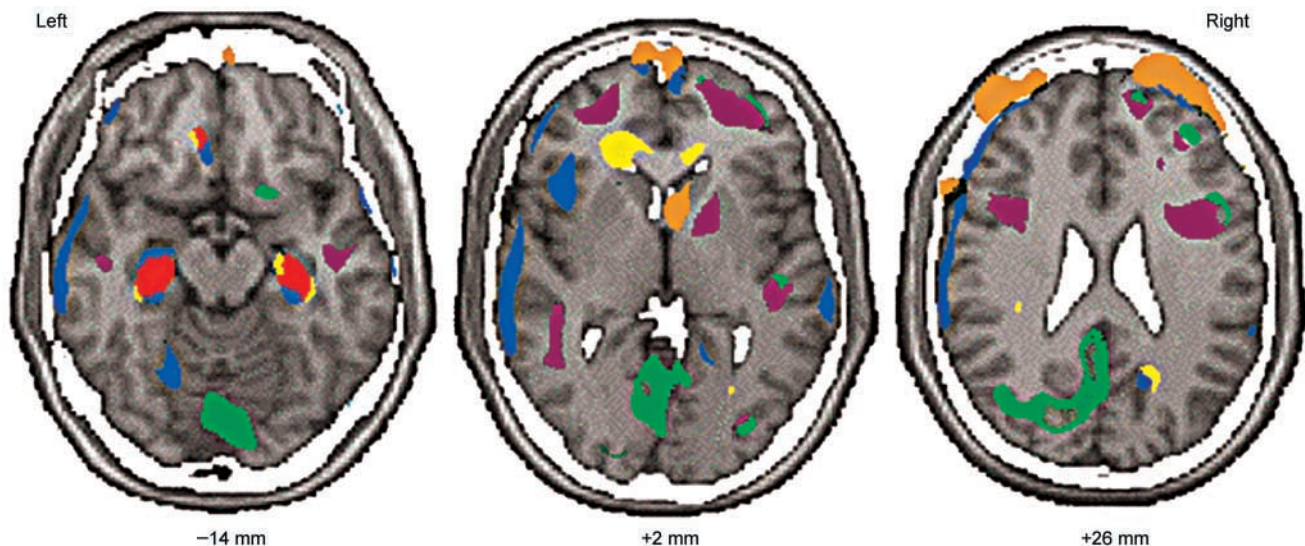


Fig. 1 The Z-maps of tissue changes ($Z > 2.33$, $P < 0.01$) in the treatment-resistant depression group have been colour-coded and then superimposed onto the appropriate transverse section to facilitate interpretation. The labels indicate the distance above or below the transverse plane formed by a line passing from the anterior to the posterior commissures. Blue, reductions in grey matter density; purple, reductions in white matter density; green, increases in grey matter density; yellow, increases in white matter density; orange, increases in CSF; red, blue+yellow.

$t = -1.7$, $P = 0.048$, effect size = 0.54) and recovered patients (3.51 v. 3.80 cm³, $t = -1.77$, $P = 0.04$, effect size = 0.56). Interrater reliability of volumetric object mapping varied from 0.85 (right anterior hippocampus) to 0.99 (posterior frontal tissue), and intrarater reliability from 0.76 (left anterior hippocampus) to 0.98 (posterior frontal tissue).

Correlation of grey matter density in TRD with selected clinical variables

Severity of illness over time was thought to be represented best by the total number of ECT treatments administered, the total duration of hospitalisation and the total number of admissions. Data reduction with the number of ECT treatments in both patient groups, duration of hospitalisation, number of admissions and treatment resistance entered as (dummy) variables in a principal-components analysis with subsequent varimax rotation, resulted in two rotated factors: one represented the two patient groups and accounted for 35% of the overall variance and loading on duration of hospitalisation (0.86) and treatment resistance (-0.83); and the other accounted for the majority of the variance (53%) and loaded on number of ECT treatments (0.96) and number of hospital admissions (0.98). Electroconvulsive therapy at the

Royal Edinburgh Hospital is usually reserved for severely depressed patients requiring admission and for those unresponsive to conventional pharmacotherapy. Although variability in its use between consultants cannot be neglected, the variations observed within the hospital are probably less than those observed nationwide. Nevertheless, the use of ECT as a measure of illness severity clearly has its limitations. As the total number of ECT treatments, total duration of hospitalisation and total number of admissions were highly inter-correlated, we elected to use the total number of ECT treatments as the measure of cumulative illness severity, aware that a significant association of ECT with cortical tissue reductions may have alternative interpretations.

Increasing cumulative ECT correlated extensively with reduced bilateral superior frontal gyri, bilateral superior frontal and inferior parietal gyri, bilateral medial and superior temporal gyri and bilateral caudate grey matter density in the TRD group (Fig. 2) upon VBA. The reduced grey matter density correlations with ECT were unaffected, even after accounting for the current severity of depression (using the HRSD score as a covariate). Thus, neocortical and striatal grey matter reductions appeared to be proportional to the cumulative severity of depression. We repeated the group comparison of grey matter

density between the TRD and recovered groups, controlling for age and the number of ECT treatments administered, and found that only reductions in grey density in the left hippocampus remained. Thus, reduced hippocampal grey matter density in TRD seemed to be unrelated to the cumulative severity (or cumulative ECT received) or duration of illness. Additionally, the estimated total duration of illness did not correlate with neocortical grey density reductions.

DISCUSSION

This study confirms our prediction that patients with TRD exhibit right superior, medio-frontal and striatal atrophy. The degree of atrophy was proportional to a proxy of illness severity over time. It also confirmed that only patients with TRD have hippocampal and rostral anterior cingulate changes, possibly reflecting an altered focal biochemical environment or tissue composition reflected in altered T1 values. No difference was found between controls and patients recovered from depression. The findings of atrophy in right fronto-striatal structures were replicated using the 'gold standard' of conventional volumetry, thus providing validity for the use of SPM'96, a voxel-based approach to analysing high-resolution structural magnetic resonance images.

Table 2 Significant compartmental changes and reciprocal changes in adjacent compartments in patients with treatment-resistant depression compared with the combined control and recovered groups

Compartment density changes	Size of cluster, all $Z > 2.33$ (uncorrected P , corrected at cluster level)	Coordinates of peak voxels within cluster (uncorrected P)
Left hippocampal grey matter decrease	7.0 cm ³ ($P=0.001$) Corrected $P=0.04$	-29, -27, -12 (<0.001) -30, -18, -18 (<0.001) -36, -15, -26 (<0.001)
Reciprocal white matter increase	2.9 cm ³ ($P=0.03$) Corrected $P=NS$	-29, -24, -14 (<0.001) -38, -22, -18 (<0.001) -37, -10, -28 (<0.001)
Left superior temporal and precentral grey matter decrease	23.8 cm ³ ($P<0.001$) Corrected $P=0.001$	-64, -23, 8 (<0.001) -56, 1, 32 (<0.001) -59, -17, 36 (<0.001)
Right superior and medial frontal white matter decrease	10.7 cm ³ ($P<0.001$) Corrected $P=0.01$	31, 50, 4 (<0.001) 36, 41, 10 (<0.001) 18, 50, 24 (<0.001)
Right superior frontal grey matter decrease	2.1 cm ³ ($P=0.04$) Corrected $P=NS$	22, 41, 48 (<0.001) 34, 26, 52 (<0.001) 26, 52, 32 (<0.001)
Reciprocal right frontal cerebrospinal fluid increase	1.8 cm ³ ($P<0.001$) Corrected $P=0.007$	28, 53, 32 (<0.001) 41, 48, 24 (<0.001) 19, 42, 44 (<0.001)
Increased left frontal cerebrospinal fluid	11.4 cm ³ ($P=0.002$) Corrected $P=0.02$	-39, 53, 14 (<0.001) -38, 53, 14 (<0.001) -41, 19, 54 (0.002)
Reciprocal left medial and superior frontal white matter decrease	3 cm ³ ($P=0.03$) Corrected $P=NS$	-24, 46, 6 (<0.001) -26, 35, 18 (0.005)

Methods of analysis

Conventional volumetry has a number of limitations. It involves manual segmentation of brain regions, reducing spatial precision and reliability. It assumes functional and structural homogeneity and, because regions are constrained by *a priori* hypotheses, only examines parts of the data set (or image). Only volumetric aspects of the data are examined, making the assumption that MRI reflects structure. Because T1-weighted images are cross-sectional measurements of water distribution and chemistry, they are influenced by tissue characteristics (e.g. fat content), regional metabolism and blood flow. Thus, they may reflect both state-dependent and anatomical differences.

In contrast, VBA detected a range of MRI changes. With atrophy, CSF replaces grey and white matter. Thus, atrophy is represented by reductions in grey and/or white matter together with a corresponding

increase in CSF. If, however, water density decreased without cell loss, then the voxel signals may be brighter. In areas where grey and white matter are in close proximity, brighter voxels have a higher probability of being assigned to the white matter compartment instead of grey, producing reduced grey matter density but an overlapping apparent increased white matter density. Thus, the reciprocal grey and white matter changes seen in the anterior hippocampus, rostral anterior cingulate (Brodmann area 24) and posterior cingulate/precuneus are not likely to be frank atrophy but, rather, indicative of a change in tissue composition.

Fronto-striatal atrophy

Our findings of fronto-striatal atrophy are consistent with previous studies (Husain *et al*, 1991; Coffey *et al*, 1993; Dupont *et al*, 1995). Reduced metabolism in the

rostral anterior cingulate in treatment non-responsive patients has also been shown (Mayberg *et al*, 1997). However, findings of temporal lobe changes have been more equivocal (Coffey *et al*, 1993).

At present, there is no clear hypothesis as to which neuronal systems are involved with the atrophy. However, a brain morphometric study (Rajkowska *et al*, 1999) of patients with major depression found cell atrophy in cortical layers of the rostral orbito-frontal cortex (Brodmann areas 10–47) associated with serotonergic neurons, and in layers associated with dopaminergic and glutaminergic neurons in dorso-lateral prefrontal cortex (Brodmann area 9), extensively connected with striatum. We also found right frontal atrophy in these Brodmann areas. Interestingly, *in vivo* studies have found reduced striatal dopamine release in depression, proportional to the severity of motor slowing (Ebert *et al*, 1994; Shah *et al*, 1997) and that the mood-activating properties of psychostimulants are particularly linked to dopamine (Swerdlow & Koob, 1987). The characteristics of possibly irreversible cognitive deficits in depression also support fronto-striatal involvement, raising the possibility of a 'fronto-striatal dementia' (reviewed in Robbins *et al*, 1992). Thus, it could be speculated that treatment resistance in depression may be related to a loss of dopamine neurons or their function.

Fronto-striatal atrophy, however, is not diagnosis-specific; similar fronto-striatal changes are found in schizophrenia, and may be related to the 'poverty syndrome' characterised by poverty of affect, movement and initiation. At a speculative level, such atrophy may be the final common pathway for severe melancholia, also characterised by poverty of affect, movement and initiation, and for chronic schizophrenia.

Tissue changes in hippocampal and rostral anterior cingulate

Much attention has been paid to hippocampal changes in depression owing to the notion that stress may produce cellular damage. We did not find volumetric change, in contrast to other studies (e.g. Sheline *et al*, 1999), but rather evidence of change in tissue composition, which appeared to be unrelated to illness severity (or to ECT). Our rostral anterior cingulate

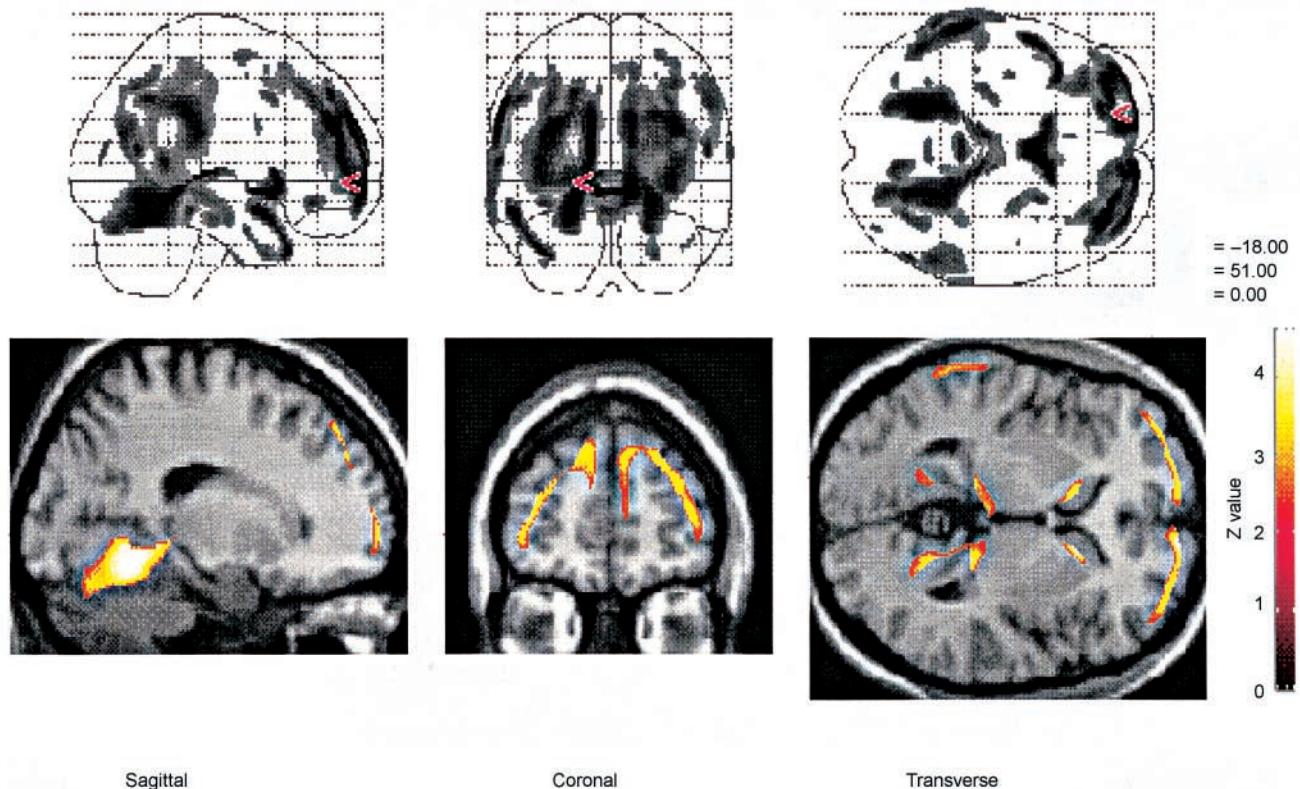


Fig. 2 Negative correlations between grey density and total number of electroconvulsive therapy treatments in patients with treatment-resistant depression ($Z > 2.33$, $P < 0.01$). The upper series represents areas of significant negative correlation viewed in maximum intensity projection (MIP). The lower series illustrates the correlations with grey matter superimposed on three sections taken at the point marked on the (MIP) view.

changes (Brodmann area 24) also agree with Mayberg's (1997) notion of specific metabolic changes in this area in treatment-resistant patients. Our results suggest that this may represent metabolic rather than structural change.

Limitations

Although it could be argued that the differences were the effects of ECT, there is little current evidence that ECT can produce permanent hippocampal or other structural brain changes (Devanand *et al*, 1994). Because of this, and because the total number of ECT treatments, total duration of in-patient stay and total number of hospitalisations were closely inter-correlated, it seemed reasonable to regard the total number of ECT treatments administered as being an index of cumulative severity. However, the possibility that the findings are ECT-related cannot be discounted. Similarly, all the patients with TRD were medicated,

as were about half of the recovered patients. It was not possible to withdraw medication on these subjects.

Because the study is cross-sectional in design, it is not possible to distinguish between state-dependent, acquired and permanent changes, especially as apparent atrophy on MRI has been found to be partially reversible with illness resolution in conditions such as anorexia nervosa and alcohol dependence. Patients with depression often lose weight, which could produce a general effect. However, it is difficult to see how this would produce specific focal brain changes. The exact time course of these changes in relation to the illness needs to be determined. One possibility is that these brain differences are present prior to illness and confer vulnerability to treatment resistance. However, given that the TRD group had no clinical evidence of premorbid impairment and that the atrophy was more severe in those with the most severe illness, it is more likely that these differences were acquired.

ACKNOWLEDGEMENTS

We would like to acknowledge the financial support of the Royal College of Physicians (Edinburgh) Sim Fellowship for P.J.S., Margaret van Beck and Catherine Murray for their help with data handling, John Bennie for cortisol measurements, Ewan Rimmington for help with scan acquisition and correlation for magnetic field inhomogeneities and Norma Brearley for her careful preparation of the manuscript. Core funding was received from the Medical Research Council Brain Metabolism Unit.

REFERENCES

- American Psychiatric Association (1994)** *Diagnostic and Statistical Manual of Mental Disorders* (4th edn) (DSM-IV). Washington, DC: APA.
- Annett, M. (1970)** A classification of hand preference by association analysis. *British Journal of Psychology*, **61**, 303–321.
- Carney, M. W. P., Roth, M. & Garside, R. F. (1965)** The diagnosis of depressive syndromes and the prediction of ECT response. *British Journal of Psychiatry*, **111**, 659–674.
- Coffey, C. E., Wilkinson, W. E., Weiner, R. D., et al (1993)** Quantitative cerebral anatomy in depression: a controlled magnetic resonance imaging study. *Archives of General Psychiatry*, **50**, 7–16.

Devanand, D. P., Dwork, A. J., Hutchinson, E. R., et al (1994) Does ECT alter brain structure? *American Journal of Psychiatry*, **151**, 957–970.

Dupont, R. M., Jernigan, T. L., Heindel, W., et al (1995) Magnetic resonance imaging and mood disorders – localization of white matter and other subcortical abnormalities. *Archives of General Psychiatry*, **52**, 747–755.

Ebert, D., Feistel, H., Kaschka, W., et al (1994) Single photon emission computerized tomography assessment of cerebral dopamine D2 receptor blockade in depression before and after sleep deprivation – preliminary results. *Biological Psychiatry*, **35**, 880–885.

Endicott, J. & Spitzer, R. L. (1978) A diagnostic interview – the schedule for affective disorders and schizophrenia. *Archives of General Psychiatry*, **35**, 837–844.

Hamilton, M. (1960) A rating scale for depression. *Journal of Neurology, Neurosurgery and Psychiatry*, **23**, 56–62.

Husain, M. M., McDonald, W. M., Doraiswamy, P. M., et al (1991) A magnetic resonance imaging study of putamen nuclei in major depression. *Psychiatry Research – Neuroimaging*, **40**, 95–99.

Keller, M. B., Shapiro, R. W., Lavori, P. W., et al (1982) Recovery in major depressive disorder: analysis with the life table and regression models. *Archives of General Psychiatry*, **39**, 905–910.

—, **Klerman, G. L., Lavori, P. W., et al (1984)** Long-term outcome of episodes of major depression: clinical and public health significance. *Journal of the American Medical Association*, **252**, 788–792.

Mayberg, H. S. (1997) Limbic–cortical dysregulation: a proposed model of depression. *Journal of Neuropsychiatry and Clinical Neuroscience*, **9**, 471–481.

—, **Brannan, S. K., Mahurin, R. K., et al (1997)** Cingulate function in depression: a potential predictor of treatment response. *Neuroreport*, **8**, 1057–1061.

Nelson, H. & Willison, J. (1991) *National Adult Reading Test* (2nd edn). Windsor: NFER–Nelson.

Rajkowska, G., Miguel-Hidalgo, J. J., Wei, J., et al (1999) Morphometric evidence for neuronal and glial prefrontal cell pathology in major depression. *Biological Psychiatry*, **45**, 1085–1098.

Robbins, T. W., Joyce, E. M. & Sahakian, B. J. (1992) Neuropsychology and neuroimaging of affective disorders. In *Handbook of Affective Disorders* (ed. E. S. Paykel), pp. 289–310. London: Churchill Livingstone.

Scott, J. (1988) Chronic depression. *British Journal of Psychiatry*, **153**, 287–297.

Shah, P. J., Ogilvie, A. D., Goodwin, G. M., et al (1997) Clinical and psychometric correlates of dopamine D-2 binding in depression. *Psychological Medicine*, **27**, 1247–1256.

—, **Ebmeier, K. P., Glabus, M. F., et al (1998)** Cortical grey matter reductions associated with treatment-resistant chronic unipolar depression. Controlled

CLINICAL IMPLICATIONS

- Patients with treatment-resistant depression had right fronto-striatal atrophy detected with voxel-based and volumetric methods.
- There were also tissue changes, only detected with voxel-based analysis, in the left temporal lobe, left hippocampus, rostral anterior cingulate and posterior cingulate/precuneus.
- The severity of atrophy was greater in those with a longer, more severe illness.

LIMITATIONS

- In this cross-sectional study, we cannot determine whether changes are the causes or consequences of treatment resistance, aggressive treatments such as electroconvulsive therapy or the illness process *per se*.
- Our treatment-resistant patients were also chronically ill, so the effect of treatment resistance *per se* may have been confounded by chronicity.
- As in all relatively small studies in this field, independent replication is essential.

P. J. SHAH, MRCPsych, Department of Psychiatry, University of Edinburgh, UK; M. F. GLABUS, PhD, Unit on Integrative Neuroimaging, Clinical Brain Disorders Branch, National Institute of Mental Health, Bethesda, Maryland, USA; G. M. GOODWIN, FRCPsych, University Department of Psychiatry, Warneford Hospital, Oxford; K. P. EBMEIER, MD, Department of Psychiatry, University of Edinburgh, UK

Correspondence: Professor K. P. Ebmeier, Department of Psychiatry, University of Edinburgh, Royal Edinburgh Hospital, Morningside Park, Edinburgh EH10 5HF, UK. Tel/Fax: 0131 5376505; e-mail: k.ebmeier@ed.ac.uk

(First received 22 March 2001, final revision 2 January 2002, accepted 14 January 2002)

magnetic resonance imaging study. *British Journal of Psychiatry*, **172**, 527–532.

Sheline, Y. I., Sanghavi, M., Mintun, M. A., et al (1999) Depression duration but not age predicts hippocampal volume loss in medically healthy women with recurrent major depression. *Journal of Neuroscience*, **19**, 5034–5043.

Shenton, M. E., Kikinis, R., Jolesz, F. A., et al (1992) Abnormalities of the left temporal lobe and thought disorder in schizophrenia. A quantitative magnetic resonance imaging study. *New England Journal of Medicine*, **327**, 604–612.

Soares, J. C. & Mann, J. J. (1997) The anatomy of mood disorders – review of structural neuroimaging studies. *Biological Psychiatry*, **41**, 86–106.

Suddath, R. L., Christison, G. W., Torrey, E. F., et al (1990) Anatomical abnormalities in the brains of monozygotic twins discordant for schizophrenia. *New England Journal of Medicine*, **322**, 789–794.

Swerdlow, N. R. & Koob, G. F. (1987) Dopamine, schizophrenia, mania, and depression: toward a unified hypothesis of cortico-striato-pallido-thalamic function. *Behavioural and Brain Sciences*, **10**, 197–245.

Widlöcher, D. J. (1983) Psychomotor retardation: clinical, theoretical, and psychometric aspects. *Psychiatric Clinics of North America*, **6**, 27–40.