

Delayed Unilateral Coronal Synostosis Following Metopic Synostosis Repair

Amit R.L. Persad, Ravi Bhargava, Gorman Louie, Vivek Mehta

Keywords: Neurosurgery, Neurosurgery - Pediatric

doi:10.1017/cjn.2015.315

Can J Neurol Sci. 2016; 43: 322-325

Craniosynostosis is the premature fusion of one or more cranial sutures, estimated to occur in approximately 1/2500 live births.¹ Rarely, secondary craniosynostosis may occur in a previously open suture following the primary repair of the pathological suture.²⁻⁷

A 6-month-old male presented with trigonocephaly (Figure 1A). A preoperative computed tomography scan was obtained, which demonstrated closure of the metopic suture (Figure 1B-D) and bilateral open coronal sutures. The decision was made to concentrate surgically on the frontal contour of the skull. The child underwent a metopic strip craniectomy and bifrontal rotational craniotomy. No surgical correction of the supraorbital bar was attempted. The frontal craniotomies were barrel staved and contoured to improve the trigonocephaly with an absorbable plating system. The pterion were released bilaterally. There was no laceration of the dura or any dissection of the coronal suture and dural interface.

The patient was seen again 9 months postoperatively. His head circumference was normal, but abnormal bone formation was noted over the frontal bone and a suboptimal surgical result was present (Figure 2A). Interval fusion of the left coronal suture was noted via computed tomography scan, confirming the presence of left coronal synostosis (Figure 2B). No intracranial abnormality was observed (Figure 2C). The patient was admitted for cranial vault reconstruction. A repeat two-piece bifrontal craniotomy was lifted followed by removal of the supraorbital bar. The orbital bar and bifrontal bone flap were then contoured and replaced using an absorbable plating system.

On genetic testing, the child did not meet the criteria for any syndrome, and *FGFR3* testing was negative. The patient has since recovered and no other deformities have been noted as of a 2-year follow-up (Figure 3).

Metopic craniosynostosis is classically the third most common craniosynostosis, although its incidence has increased.⁸ Secondary synostosis following surgical repair of a primary craniosynostosis is a recognized but rare clinical entity.²⁻⁷ We report the first known case of unicoronal synostosis secondary to a surgical repair of metopic synostosis.

There are several theories pertaining to the pathogenesis of craniosynostosis.^{1,6,9} Some implicate metabolic or genetic primary bone pathologies. Mutations to *FGFR* genes as well as to *EFNB1*, *TWIST1*, *POR*, and *FBNI* have been linked to syndromic and nonsyndromic multisutural craniosynostosis¹⁰⁻¹² with *FGFR* and *EFNB1* accounting for ~25%.¹² Although the child did not exhibit findings of syndromic craniosynostosis (Crouzon, Apert, Pfeiffer, and Muenke syndromes), genetic factors may promote delayed sutural fusion. The progressive nature of this case might alternatively suggest that an osseous

pathology, perhaps from the stress of surgery or a genetic predisposition, may be responsible for this patient's phenotype. Arnaud et al. postulated that surgery might abrogate signaling between the dura and the calvarial sutures, which normally maintains sutural patency,⁴ but the dura was not damaged during surgery.

Although secondary craniosynostosis is uncommon, it is an entity that surgeons must be aware of after suboptimal cosmetic results following craniosynostosis surgery.

DISCLOSURES

GL has served as a speaker and received honoraria from AO North America. All other others have nothing to disclose.

REFERENCES

1. Johnson D, Wilkie AOM. Craniosynostosis. *Eur J Hum Genet.* 2011;19:369-76.
2. Yarbrough CK, Smyth MD, Holekamp TF, Ranalli NJ, Huang AH, Patel KB, et al. Delayed synostoses of uninvolved sutures after surgical treatment of nonsyndromic craniosynostosis. *J Craniofac Surg.* 2014;25:119-23.
3. Foster KA, Frim DM, McKinnon M. Recurrence of synostosis following surgical repair of craniosynostosis. *Plast Reconstruct Surg.* 2008;12:70e-6e.
4. Arnaud E, Capon-Degardin N, Michienzi J, Di Rocco F, Renier D. Scaphocephaly part II: secondary coronal synostosis after scaphocephalic surgical correction. *J Craniofac Surg.* 2009; 20(Suppl 2):1843-50.
5. Rangel-Castilla L, Hwang SW, Jea A, Whitehead WE, Curry DJ, Luerssen TG, et al. Development of secondary unilateral coronal suture synostosis with a sagittal suture synostosis in a nonsyndromic patient. *J Neurosurg Pediatr.* 2012;9:116-8.
6. Esmali A, Nejat F, Habibi Z, El Khashab M. 2014. Secondary bicoronal synostosis after metopic craniosynostosis surgical reconstruction. *J Pediatr Neurosci.* 2014;9:242-5.
7. Agrawal D, Steinbok P, Cochrane D. Recurrence of synostosis following surgery for isolated sagittal craniosynostosis. *Can J Neurol Sci.* 2005;32(suppl. 1):s9.
8. Kolar JC. An epidemiological study of nonsyndromal craniosynostoses. *J Craniofac Surg.* 2011;22:47-9.

From the Faculty of Medicine and Dentistry, University of Alberta, Edmonton, Alberta (ARLP); Department of Radiology and Diagnostic Imaging, University of Alberta, Edmonton, Alberta (RB); Division of Plastic Surgery, Department of Surgery, University of Alberta, Edmonton, Alberta (GL); Division of Neurosurgery, Department of Surgery, University of Alberta, Edmonton, Alberta (VM)

RECEIVED APRIL 22, 2015. FINAL REVISIONS SUBMITTED JUNE 23, 2015.

Correspondence to: Vivek Mehta, Division of Neurosurgery, Department of Surgery, University of Alberta, Stollery Children's Hospital, 8215 112 Street Northwest, Edmonton, AB. Email: vivek.mehta@albertahealthservices.ca.

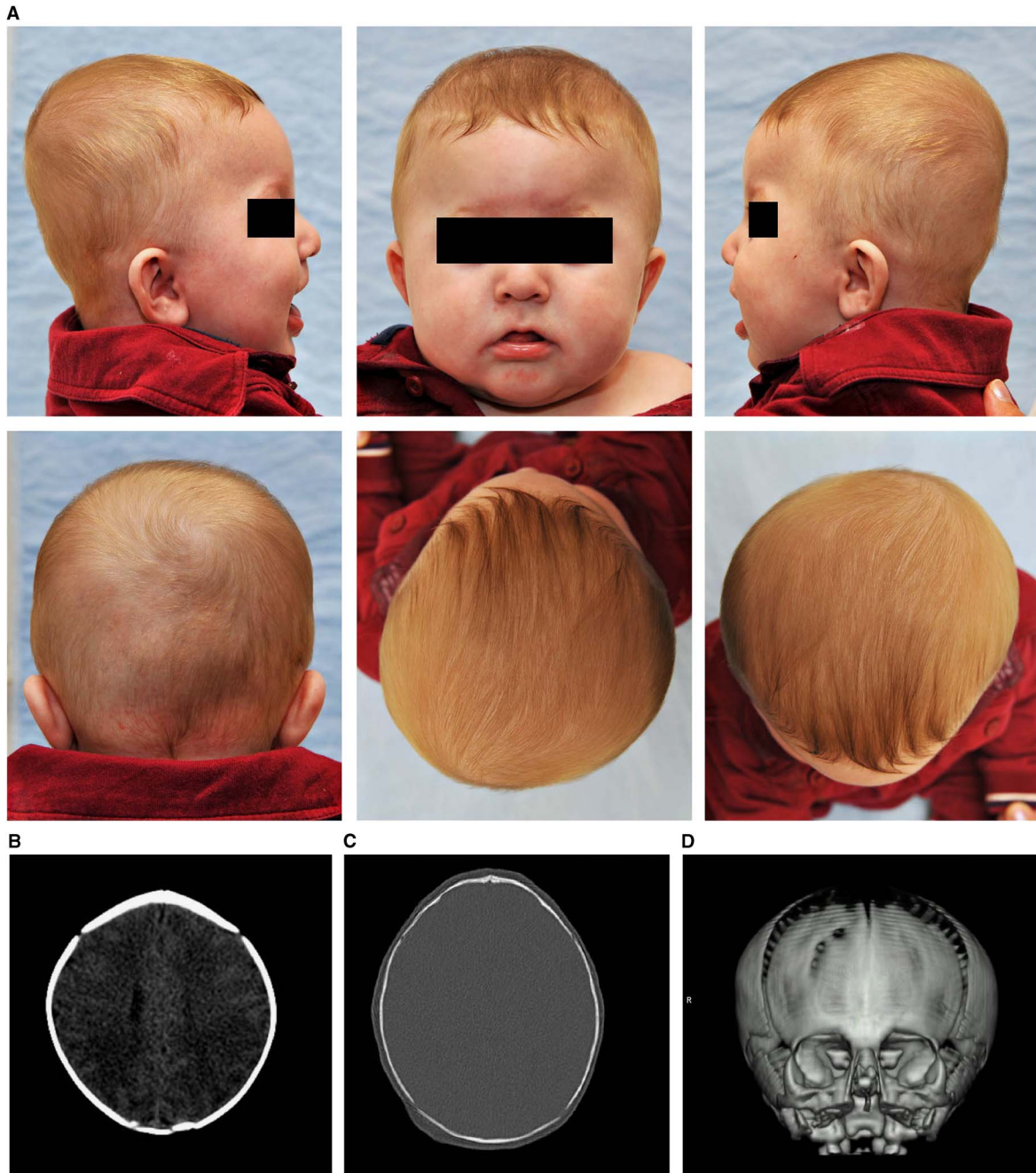


Figure 1: A Photograph of 6-month-old patient with trigonocephaly resulting from metopic craniosynostosis, (B) computed tomography (CT) scan of the brain, (C) CT scan of the bone windows, and (D) three-dimensional CT scan demonstrate fusion of the metopic suture and patency of the coronal, lamboid, and sagittal sutures.

9. Karabagil P. Pathology in metopic synostosis. *Childs Nerv Syst.* 2013;29:2165-70.
10. Greene AK, Mulliken JB, Proctor MR, Meara JG, Rogers GF. Phenotypically unusual combined craniosynostoses: presentation and management. *Plast Reconstr Surg.* 2008;122:853-62.
11. Connolly JP, Gruss J, Seto ML, Whelan MF, Ellenbogen R, Weiss A, et al. Progressive postnatal craniosynostosis and increased intracranial pressure. *Plast Reconstr Surg.* 2004;113:1313-23.
12. Panigrahi I. Craniosynostosis genetics: the mystery unfolds. *Indian J Hum Genet.* 2011;17:48-53.

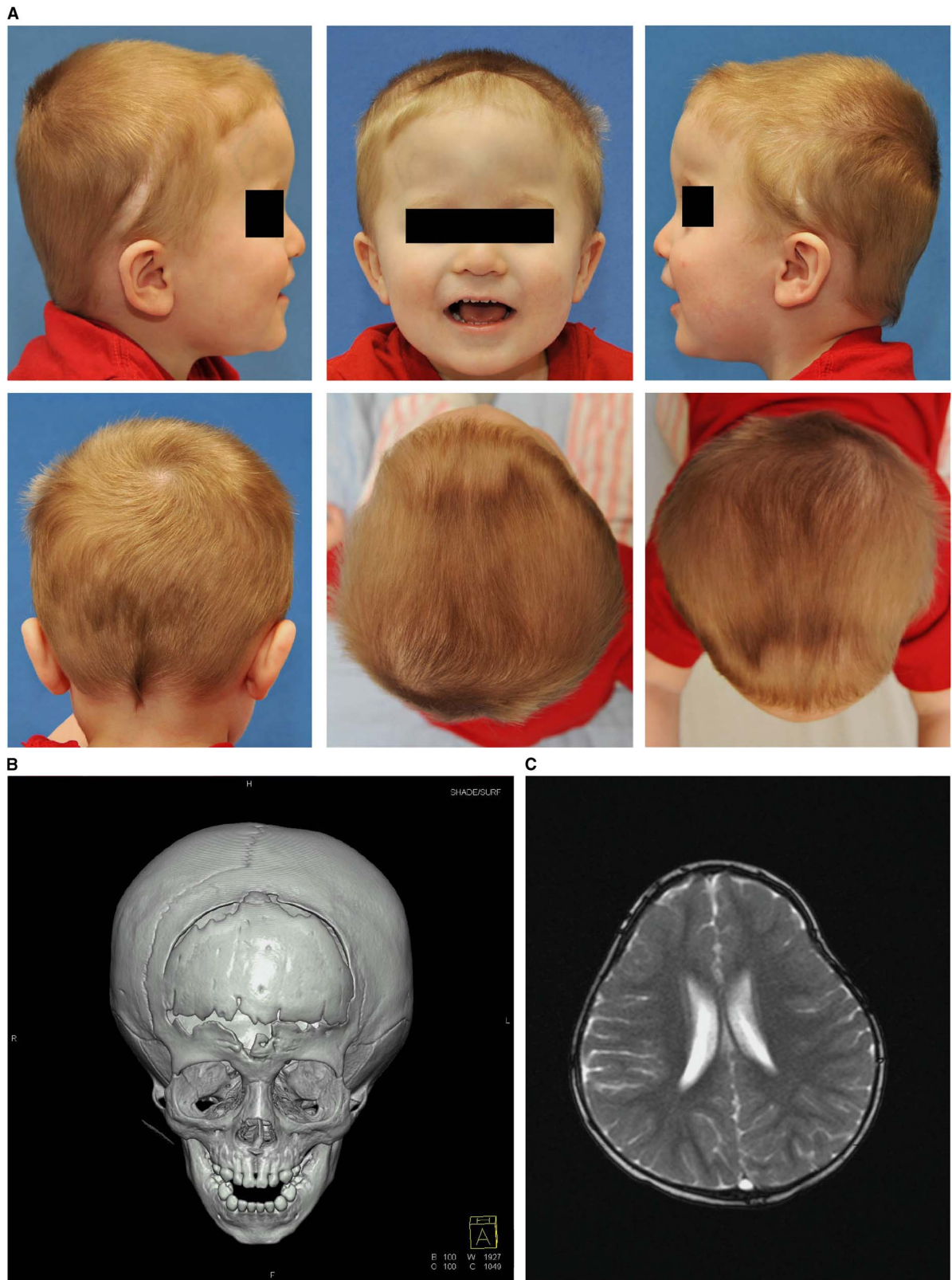


Figure 2: (A) Photograph of the 15-month-old patient with suboptimal cosmetic result caused by left secondary coronal synostosis. (B) Three-dimensional computed tomography scan of the skull demonstrating a new left unilateral coronal synostosis. (C) fast imaging with steady-state free precession (FISP) magnetic resonance imaging of the brain.

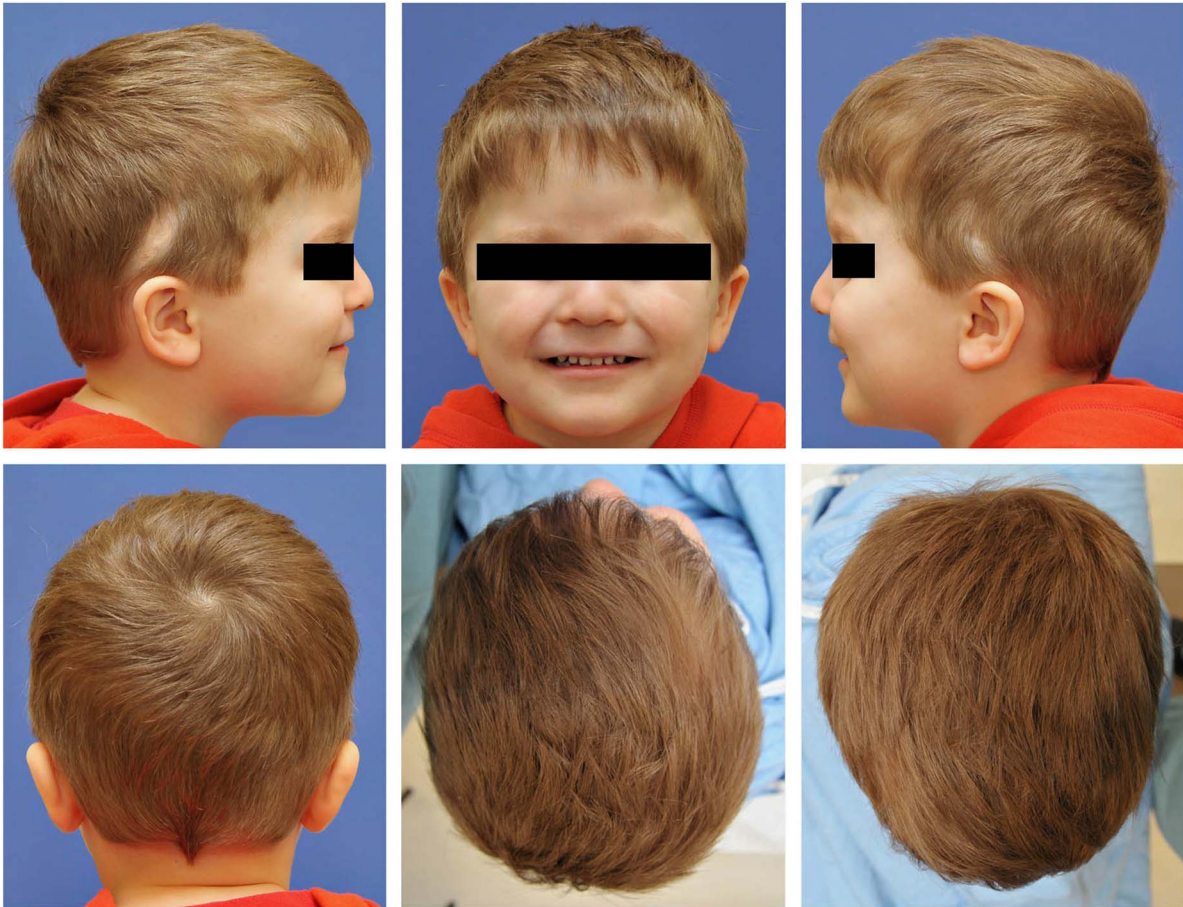


Figure 3: Photograph of the 3-year-old patient at 2-year follow-up after secondary synostosis repair.