

Prevalence of Nonlesional Focal Epilepsy in an Adult Epilepsy Clinic

Dang Khoa Nguyen, Manuela Temgoua Mbacfou, Dong Bach Nguyen, Maryse Lassonde

ABSTRACT: Purpose: To evaluate the prevalence of nonlesional focal epilepsy in an adult epilepsy clinic and its refractoriness to antiepileptic drug therapy. **Background:** Focal epilepsy is frequently, but not always, associated with structural epileptogenic lesions identifiable on magnetic resonance imaging (MRI). **Methods:** We analyzed the data from all patients evaluated at an adult epilepsy clinic from January 2002 to December 2011. Clinical and paraclinical findings were used to diagnose focal epilepsy. Magnetic resonance imaging were reviewed and classified as normal, with an epileptogenic lesion, or with a lesion of unclear epileptogenicity. Epileptogenic lesions were further categorized as tumours, vascular malformations, gliosis (including hippocampal atrophy/sclerosis), and malformations of cortical development. Our study group included patients with no lesions on MRI. Pharmacoresistance of patients with nonlesional focal epilepsy was assessed using the ILAE and Perucca's criterias. **Results:** Out of 1521 patients evaluated (mean age 44 years; range 14-93 years), 843 had focal epilepsy. Magnetic resonance imaging data, available for 806 (96%) subjects, showed epileptogenic lesions in 65%, no obvious epileptogenic lesions in 31% and lesions of unclear epileptogenicity in 4%. Magnetic resonance imaging-identified lesions included gliosis due to an acquired insult (52% including 17% of hippocampal atrophy or sclerosis), tumours (29%), vascular malformations (16%) and malformations of cortical development (10%). Fifty-two percent of nonlesional focal epileptic patients were drug-refractory. **Conclusion:** In a tertiary epilepsy clinic, close to a third of patients with focal epilepsy were found to be nonlesional, half of which were drug-resistant.

RÉSUMÉ: Prévalence de l'épilepsie focale non reliée à une lésion dans une clinique d'épilepsie pour adultes. Objectif : Le but de l'étude était d'évaluer la prévalence de l'épilepsie focale non-lésionnelle dans une clinique d'épilepsie pour adultes et sa résistance au traitement par la médication antiepileptique. **Contexte :** L'épilepsie focale est souvent, mais pas toujours, associée à des lésions épiléptogènes structurales identifiables à l'imagerie par résonance magnétique (IRM). **Méthode :** Nous avons analysé les données des dossiers de tous les patients évalués à une clinique d'épilepsie pour adultes de janvier 2002 à décembre 2011. Les observations cliniques et paracliniques ont été utilisées pour poser un diagnostic d'épilepsie focale. Nous avons révisé les observations d'IRM et nous les avons classifiées comme étant normales, mettant en évidence une lésion épiléptogène ou démontrant une lésion dont l'épiléptogénicité n'était pas claire. Les lésions épiléptogènes étaient ensuite catégorisées comme étant des tumeurs, des malformations vasculaires, de la gliose (incluant l'atrophie ou la sclérose de l'hippocampe) et des malformations du développement cortical. Notre échantillon de patients comprenait des patients sans lésion à l'IRM. La pharmacorésistance des patients atteints d'une épilepsie focale sans lésion a été évaluée au moyen des critères de l'ILAE et de Perucca. **Résultats :** Parmi les 1 521 patients évalués, qui étaient âgés de 14 à 93 ans et dont l'âge moyen était de 44 ans, 843 avaient une épilepsie focale. Les données d'IRM, qui étaient disponibles pour 806 patients (96%), avaient démontré des lésions épiléptogènes chez 65%, pas de lésion épiléptogène évidente chez 31% et des lésions dont l'épiléptogénicité était douteuse chez 4%. Les lésions identifiées à l'IRM étaient de la gliose due à une lésion acquise (52%, dont 17% d'atrophie ou de sclérose hippocampique), des tumeurs (29%), des malformations vasculaires (16%) et des malformations du développement cortical (10%). Cinquante-deux pour cent des patients atteints d'une épilepsie focale non reliée à une lésion étaient résistants au traitement pharmacologique. **Conclusion :** Dans une clinique de soins tertiaires de l'épilepsie, l'épilepsie n'était pas reliée à une lésion chez près du tiers des patients atteints d'une épilepsie focale et la moitié d'entre eux étaient pharmacorésistants.

Can J Neurol Sci. 2013; 40: 198-202

Epilepsy is a chronic condition characterized by recurrent seizures resulting from abnormal and excessive neuronal discharges¹. It is the most common neurological disorder after stroke with a prevalence of 5-6 per 1,000 in Canada². Each year an average of 15,500 Canadians learn that they have epilepsy. The major form of treatment is long-term drug therapy to which approximately 30% of patients are unfortunately refractory³. For these patients, other treatment alternatives include epilepsy surgery or neuromodulation.

Seizures can be focal (activation of only part of one cerebral hemisphere) or generalized (more than minimal involvement of both cerebral hemispheres)⁴. Partial or focal epilepsy is the most common form of epilepsy in adults and is frequently associated

with an epileptogenic lesion⁵. Magnetic resonance imaging (MRI) is very useful in detecting structural abnormalities related to seizures such as tumours, gliosis/hippocampal sclerosis, malformations of cortical development or vascular

From the Service de Neurologie (DKN, DBN), Hôpital Notre-Dame du CHUM, Département de Sciences Biologiques (MTM), Centre de Recherche de Neuropsychologie et Cognition (ML), Université de Montréal, Montréal, QC, Canada.
RECEIVED JUNE 11, 2012. FINAL REVISIONS SUBMITTED SEPTEMBER 12, 2012.
Correspondence to: Dang K. Nguyen, Service de Neurologie, Hôpital Notre-Dame du CHUM, 1560 rue Sherbrooke Est, Montréal, Québec, H2L 4M1, Canada.
Email: d.nguyen@umontreal.ca.

malformations. It is not uncommon, however, that brain MRI fails to uncover such epileptogenic lesions.

The prevalence of nonlesional epilepsy has been evaluated in some surgical series or during the presurgical evaluation phase but the prevalence of nonlesional focal epilepsy in the setting of an epilepsy clinic is unclear. In this study, we sought to determine the proportion of patients with nonlesional focal epilepsy in our adult epilepsy clinic. A secondary objective was to determine the degree of pharmacoresistance in patients with nonlesional focal epilepsy.

PATIENTS AND METHODS

Patients

Charts from all patients evaluated by a single epileptologist at an adult tertiary center epilepsy clinic between January 2002 and December 2011 were reviewed. The diagnosis of partial epilepsy was established based on review of all available clinical and paraclinical findings at the time of the study (clinical notes, electroencephalogram (EEG) and neuroimaging findings). The presence of focal spikes on standard EEG for the diagnosis of focal epilepsy as clinical evaluation (ictal semiology, neurological examination, age of onset etc.) and neuroimaging (type of lesion, location of lesion etc.) provided enough evidence to establish the diagnosis of focal epilepsy. Video-electroencephalography was performed only in some subjects if clinically indicated (diagnostic dilemma or presurgical evaluation). Patients with an unclear epilepsy diagnosis, a single seizure with normal EEG and neuroimaging, acute symptomatic seizures and idiopathic generalized epilepsy were excluded. Epileptic encephalopathies, a heterogeneous group of epilepsy syndromes associated with severe cognitive, behavioral and epileptic disturbances in infancy or early childhood (e.g. Lennox-Gastaut syndrome), were excluded as well, even they could present focal seizures. These patients were generally investigated and diagnosed in a pediatric setting before being transferred to our adult epilepsy clinic for continued care. Magnetic resonance imaging was not generally performed or repeated due to lack of cooperation or clinical necessity.

Magnetic Resonance Imaging

Magnetic resonance imaging reports from all patients with focal epilepsy were reviewed. The MRIs were obtained using a 1.5T Avanto scanner (Siemens, Germany) or an Achieva Dual 3T system (Philips Medical Systems, Netherlands). All studies included (a) a 3-D T1-weighted gradient-echo acquisition of the whole brain; (b) an axial T2-weighted and fluid-attenuated inversion recovery (FLAIR) acquisitions of the whole brain; (c) coronal T2-weighted and FLAIR acquisitions perpendicular to the longitudinal axis of the hippocampus. Intravenous contrast agents were given only if a mass lesion was demonstrated. In our institution, all brain MRIs are reviewed by a group of four neuroradiologists experienced in interpreting epilepsy studies. Some clinical information was available on the MRI request form. Upon review of MRI interpretation, reported potentially epileptogenic lesions were classified into five categories: tumours (e.g. gliomas, gangliogliomas, dysembryoplastic neuroectodermal tumors), vascular malformations (e.g. cavernomas, arteriovenous malformations), gliosis from an

acquired insult (including hippocampal atrophy and sclerosis), malformations of cortical development (e.g. cortical dysplasia, heterotopias, polymicrogyria) and others. Patients were considered to have nonlesional focal epilepsy if the MRI failed to disclose an epileptogenic lesion. Patients with MRI lesions not expected to give epilepsy (Chiari type 1, pineal cyst, septum pellucidum etc.) were included in this group. Diffuse cerebral or cerebellar atrophy, non-specific white matter changes, leukoaraiosis and arachnoid cysts were classified as lesions of unclear relationship to the patient's epileptic condition.

Pharmacoresistance

Response to medical treatment was assessed for all patients with nonlesional focal epilepsy. Patients were considered to be drug-resistant if they continued to have seizures despite two adequate antiepileptic drug (AED) trials whether used in monotherapy or in combination⁶. We also graded the degree of drug-resistance using the classification proposed by Perucca⁷.

This study was approved by our institutional ethics committee.

RESULTS

MRI of focal epilepsy patients

Out of 1521 patients (mean age 44 years; range 14-93) evaluated at the epilepsy clinic between January 2002 and December 2011, 1051 (69%) had epilepsy. Among these patients, 843 (80%) were diagnosed with focal epilepsy, 130 (12%) with idiopathic generalized epilepsy, 61 (6%) with an epileptic encephalopathy and 17 (2%) with an unclear epileptic syndrome. While 37 subjects did not or could not undergo an MRI study, the majority of patients with focal epilepsy (806/843; 96%) did. In these 806 remaining patients with focal epilepsy, MRI disclosed a clear epileptogenic lesion in 520 (65%), no obvious epileptogenic lesion in 251 (31%), and lesions of unclear epileptogenicity in 35 (4%) (Figure).

Among the 520 patients with an epileptogenic lesion, 153 (29%) had a tumour, 82 (16%) had a vascular malformation, 54 (10%) had a malformation of cortical development and 219 (42%) had gliosis due to an acquired insult. Included in this latter group were 86 (17%) patients with hippocampal atrophy/sclerosis.

Pharmacoresistance

Out of 251 patients with nonlesional epilepsy, 131 (52%) were medically intractable according to the International League Against Epilepsy (ILAE) classification. Using Perucca's classification, 176 were drug-resistant: 45 (26%) patients were refractory to one AED (grade I), 30 (17%) to two (grade II) and 101 (57%) to 3 or more (grade III).

DISCUSSION

Our study showed that, in nearly one third of patients with focal epilepsy in an adult epilepsy clinic, no clear epileptogenic lesions on MRI are seen. Many patients have some difficulty grasping the notion that focal epilepsy can occur without a structural lesion identifiable on MRI. One possible explanation for the lack of an apparent epileptogenic lesion is that an

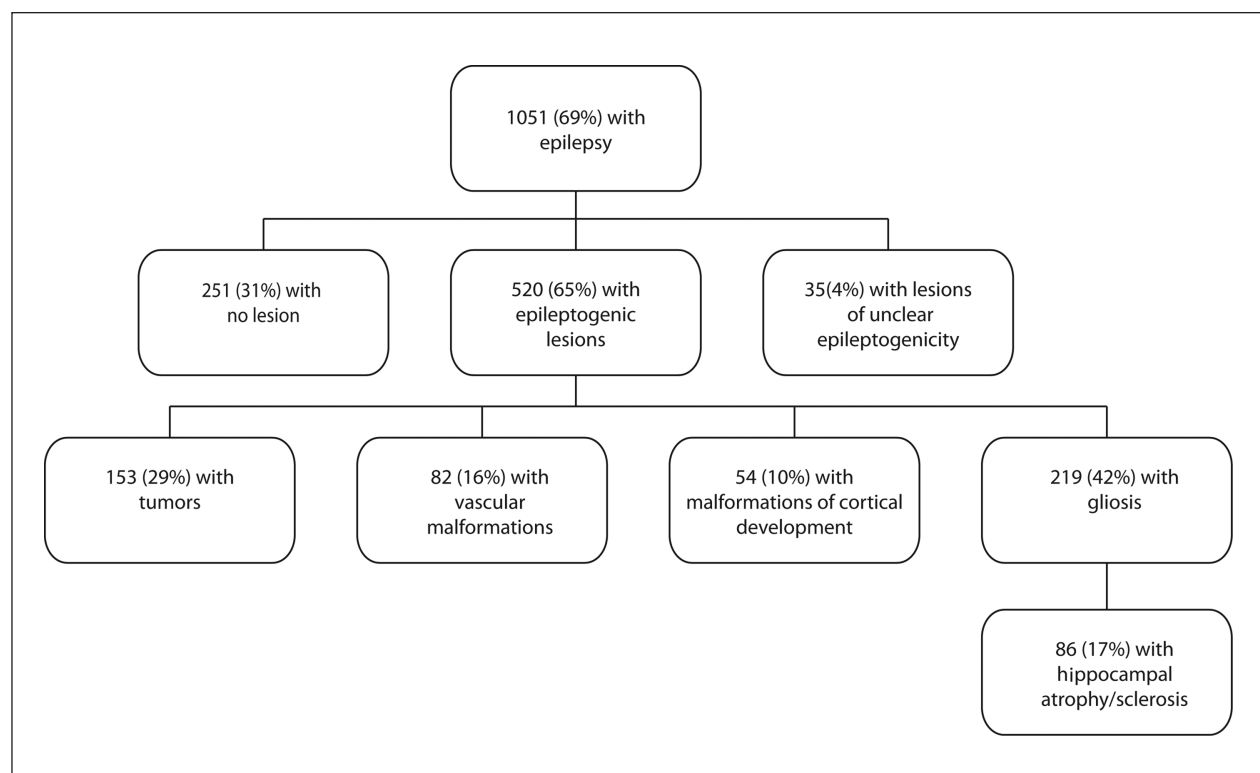


Figure: MRI findings in patients with focal epilepsy.

underlying lesion is present but is so subtle that it is undetected by standard MRI. This is supported by histopathological studies of resected epileptogenic tissue in patients with normal standard MRIs which have revealed subtle cortical dysplasias or gliosis or hippocampal sclerosis⁸⁻¹⁸. Another potential explanation is that focal seizures are related to a genetic defect. This is supported by recent findings indicating that some partial epilepsies have a significant genetic component¹⁹⁻²⁴.

The prevalence of nonlesional focal epilepsy found in our epilepsy clinic is relatively in line with prior studies found in the literature. Prior series, using mostly standard field MRIs, have mainly been dealt with three other slightly different subsets of populations: a) patients with refractory focal epilepsy being investigated for epilepsy surgery (presurgical investigation series); b) patients with refractory epilepsy who were operated (surgical series); and c) patients with refractory focal epilepsy who underwent an intracranial EEG study (invasive EEG series). In presurgical investigation series, the rate of nonlesional cases was lower (range from 15-23%) which is to be expected as not all focal epilepsy patients are drug-refractory and require further investigation for epilepsy surgery. For example, Scott et al (1999) reported that 40/222 (18%) of drug-resistant patients undergoing video-EEG for epilepsy surgery investigation had a normal MRI²⁵. In another study by Berg et al (2003), 130/565 (23%) candidates for epilepsy surgery had normal MRI findings²⁶. In Bien et al (2009), 190/1192 (16%) patients undergoing comprehensive presurgical assessment for

intractable epilepsy had a negative MRI¹⁴. These nonlesional rates in presurgical investigation series are close to those reported in surgical series. Hence, in temporal lobe epilepsy surgery series, Berkovic et al (1995) reported that 24/135 (18%) patients undergoing an anterior temporal lobectomy had a normal MRI²⁷. In a controlled randomized trial of surgery for temporal lobe epilepsy, Wiebe et al (2001) had 13/80 (16%) patients with normal MRI²⁸. In Bell et al (2009), 44/272 (16%) patients with medically refractory temporal lobe epilepsy who had undergone an anterior temporal lobectomy were nonlesional¹¹. Finally, in a study by Alarcon et al (2006), 21/136 (15%) operated patients had nonlesional epilepsy²⁹. As for extratemporal lobe epilepsy series, an outcome meta-analysis of adult patients operated for nonlesional extratemporal lobe epilepsy found that 25/61 (19%) MRIs were normal¹⁶. These relatively comparable rates are, however, contrasted by the data collected by Berg et al (2003) in a multicenter study of epilepsy surgery in which 58/396 (45%) patients undergoing resective surgery had normal MRI findings²⁶. Possible explanations include its prospective design, the academic setting (epilepsy surgery centers of reference) and earlier study years (1996-2001). Finally, when looking at invasive EEG series, one can observe with no surprise a very high rate of nonlesional focal epilepsy as implantation of intracranial electrodes are more often required in nonlesional than in lesional epilepsies. For example, Cukiert et al (2001) reported that 10/16 (62.5%) patients with refractory extratemporal epilepsy investigated with subdural

electrodes had normal MRI³⁰. In a larger series of 100 patients undergoing stereoencephalography, 43 (43%) also had a normal MRI³¹.

A normal MRI is not synonymous with self-limited or pharmacosensitive epilepsy. In our series, 52% of patients were drug-resistant according to the recent ILAE criteria, including 57% refractory to three or more antiepileptic drugs.

The limitations of our study are inherent to any retrospective design. Because MRI scans were not standardized in terms of magnet strength, one could argue that our rate of nonlesional focal epilepsy would have been lower had all patients benefited from a 3T MRI since high-field MR scanners provide an improved signal-to-noise ratio which can theoretically allow the detection of subtle lesions missed on standard 1.5T MRIs³². In a previous study however, we showed that re-imaging at 3T patients with refractory epilepsy and negative 1.5T MRIs only allowed the detection of 5.6% more lesions³³. Of course, we also have to take into account the issue of radiologist intra and interater variability. Recent development of quantitative MRI postprocessing methods applied to digital data image may improve the detection of occult lesions not readily recognizable by visual analysis alone, in addition to reducing intra and interrater variability³⁴. Finally, selecting patients from a specialized epilepsy clinic in a tertiary academic center may have biased the study into finding a higher rate of surgically challenging cases of nonlesional focal epilepsy cases or of lesions associated with intractable epilepsy. Hence, our numbers cannot necessarily be generalized outside the adult epilepsy clinic setting that typically deals with more complex and difficult to treat epilepsies than in general Neurology practices. Despite limitations mentioned above, our data helps to give a certain idea of the number of nonlesional cases encountered in the epilepsy clinic, not only for neurology and radiology colleagues or residents but, more importantly, for the patients themselves. Knowing that approximately a third of patients in the clinic are in the same situation is somewhat reassuring for them. In the near future, it may be interesting to test patients identified in this series for all mutations known to be associated with epilepsy and use advanced quantitative MRI postprocessing techniques to assess how many occult lesions might have been missed.

CONCLUSIONS

In an adult epilepsy clinic setting, close to a third of patients with focal epilepsy have no obvious epileptogenic lesion on MRI, and more than half of these are drug-resistant.

REFERENCES

1. Dichter MA. Overview: the neurobiology of epilepsy. In: Engel J, Pedley TA, editors. *Epilepsy: a comprehensive textbook*. 2nd ed. Philadelphia: Lippincott Williams and Wilkins; 2008. p. 217-19.
2. Tellez-Zenteno JF, Pondal-Sordo M, Matijevic S, Wiebe S. National and regional prevalence of self-reported epilepsy in Canada. *Epilepsia*. 2004;45(12):1623-9.
3. Kwan P, Brodie MJ. Early identification of refractory epilepsy. *N Engl J Med*. 2000;342(5):314-19.
4. Berg AT, Berkovic SF, Brodie MJ, et al. Revised terminology and concepts for organization of seizures and epilepsies: report of the ILAE Commission on Classification and Terminology, 2005-2009. *Epilepsia*. 2010;51(4):676-85.
5. Woermann FG, Vollmar C. Clinical MRI in children and adults with focal epilepsy: a critical review. *Epilepsy Behav*. 2009;15(1):40-9.
6. Kwan P, Arzimanoglou A, Berg AT, et al. Definition of drug resistant epilepsy: consensus proposal by the ad hoc Task Force of the ILAE Commission on Therapeutic Strategies. *Epilepsia*. 2010;51(6):1069-77.
7. Perucca E. The management of refractory idiopathic epilepsies. *Epilepsia*. 2001;42(3):31-5.
8. Sylaja PN, Radhakrishnan K, Kesavadas C, Sarma PS. Seizure outcome after anterior temporal lobectomy and its predictors in patients with apparent temporal lobe epilepsy and normal MRI. *Epilepsia*. 2004;45(7):803-8.
9. Chapman K, Wyllie E, Najm I, et al. Seizure outcome after epilepsy surgery in patients with normal preoperative MRI. *J Neurol Neurosurg Psychiatry*. 2005;76(5):710-13.
10. Cohen-Gadol AA, Wilhelm BG, Collignon F, et al. Long-term outcome of epilepsy surgery among 399 patients with nonlesional seizure foci including mesial temporal lobe sclerosis. *J Neurosurg*. 2006;104(4):513-24.
11. Bell ML, Rao S, So EL, et al. Epilepsy surgery outcomes in temporal lobe epilepsy with a normal MRI. *Epilepsia*. 2009;50(9):2053-60.
12. Ramachandran Nair R, Otsubo H, Shroff MM, et al. MEG predicts outcome following surgery for intractable epilepsy in children with normal or nonfocal MRI findings. *Epilepsia*. 2007;48(1):149-57.
13. Jayakar P, Dunoyer C, Dean P, et al. Epilepsy surgery in patients with normal or nonfocal MRI scans: integrative strategies offer long-term seizure relief. *Epilepsia*. 2008;49(5):758-64.
14. Bien CG, Szinay M, Wagner J, Clusmann H, Becker AJ, Urbach H. Characteristics and surgical outcomes of patients with refractory magnetic resonance imaging-negative epilepsies. *Arch Neurol*. 2009;66(12):1491-9.
15. Wetjen NM, Marsh WR, Meyer FB, et al. Intracranial electroencephalography seizure onset patterns and surgical outcomes in nonlesional extratemporal epilepsy. *J Neurosurg*. 2009;110(6):1147-52.
16. Ansari SF, Tubbs RS, Terry CL, Cohen-Gadol AA. Surgery for extratemporal nonlesional epilepsy in adults: an outcome meta-analysis. *Acta Neurochir*. 2010;152(8):1299-305.
17. Funke ME, Moore K, Orrison WW, Jr., Lewine JD. The role of magnetoencephalography in "nonlesional" epilepsy. *Epilepsia*. 2011;52(4):10-14.
18. Smith AP, Sani S, Kanner AM, et al. Medically intractable temporal lobe epilepsy in patients with normal MRI: surgical outcome in twenty-one consecutive patients. *Seizure*. 2011;20(6):475-9.
19. Steinlein OK, Mulley JC, Propping P, et al. A missense mutation in the neuronal nicotinic acetylcholine receptor alpha 4 subunit is associated with autosomal dominant nocturnal frontal lobe epilepsy. *Nat Genet*. 1995;11(2):201-3.
20. Kalachikov S, Evgrafov O, Ross B, et al. Mutations in LGI1 cause autosomal-dominant partial epilepsy with auditory features. *Nat Genet*. 2002;30(3):335-41.
21. Scheffer IE, Phillips HA, O'Brien CE, et al. Familial partial epilepsy with variable foci: a new partial epilepsy syndrome with suggestion of linkage to chromosome 2. *Ann Neurol*. 1998;44(6):890-9.

22. Xiong L, Labuda M, Li DS, et al. Mapping of a gene determining familial partial epilepsy with variable foci to chromosome 22q11-q12. *Am J Hum Genet.* 1999;65(6):1698-710.
23. Berkovic SF, Kennerson ML, Howell RA, Scheffer IE, Hwang PA, Nicholson GA. Phenotypic expression of benign familial neonatal convulsions linked to chromosome 20. *Arch Neurol.* 1994;51(11):1125-8.
24. Cendes F, Lopes-Cendes I, Andermann E, Andermann F. Familial temporal lobe epilepsy: a clinically heterogeneous syndrome. *Neurology.* 1998;50(2):554-7.
25. Scott CA, Fish DR, Smith SJ, et al. Presurgical evaluation of patients with epilepsy and normal MRI: role of scalp video-EEG telemetry. *J Neurol Neurosurg Psychiatry.* 1999;66(1):69-71.
26. Berg AT, Vickrey BG, Langfitt JT, et al. The multicenter study of epilepsy surgery: recruitment and selection for surgery. *Epilepsia.* 2003;44(11):1425-33.
27. Berkovic SF, McIntosh AM, Kalnins RM, et al. Preoperative MRI predicts outcome of temporal lobectomy: an actuarial analysis. *Neurology.* 1995;45(7):1358-63.
28. Wiebe S, Blume WT, Girvin JP, Eliasziw M. Effectiveness, Efficiency of Surgery for Temporal Lobe Epilepsy Study G. A randomized, controlled trial of surgery for temporal-lobe epilepsy. *N Engl J Med.* 2001;345(5):311-18.
29. Alarcon G, Valentin A, Watt C, et al. Is it worth pursuing surgery for epilepsy in patients with normal neuroimaging? *J Neurol Neurosurg Psychiatry.* 2006;77(4):474-80.
30. Cukiert A, Buratini JA, Machado E, et al. Results of surgery in patients with refractory extratemporal epilepsy with normal or nonlocalizing magnetic resonance findings investigated with subdural grids. *Epilepsia.* 2001;42(7):889-94.
31. McGonigal A, Bartolomei F, Regis J, et al. Stereoelectroencephalography in presurgical assessment of MRI-negative epilepsy. *Brain.* 2007;130(Pt 12):3169-83.
32. Phal PM, Usmanov A, Nesbit GM, et al. Qualitative comparison of 3-T and 1.5-T MRI in the evaluation of epilepsy. *AJR Am J Roentgenol.* 2008;191(3):890-5.
33. Nguyen DK, Rochette E, Leroux JM, et al. Value of 3.0 T MR imaging in refractory partial epilepsy and negative 1.5 T MRI. *Seizure.* 2010;19(8):475-8.
34. Bernasconi A, Bernasconi N, Bernhardt BC, Schrader D. Advances in MRI for 'cryptogenic' epilepsies. *Nat Rev Neurol.* 2011;7(2):99-108.