


Original Article

The FAST VAN for Field Identification of Large Vessel Occlusion in Acute Stroke

Sanchea Wasyliw¹, Ruth Whelan¹, Kim Davy², Michael E. Kelly³, Brett Graham¹, Layla Gould³  and Gary Hunter¹

¹Division of Neurology, College of Medicine, University of Saskatchewan, Saskatoon, SK, Canada, ²Department of Quality Improvement, Saskatchewan Health Authority, Saskatoon, SK, Canada and ³Division of Neurosurgery, College of Medicine, University of Saskatchewan, Saskatoon, SK, Canada

ABSTRACT: Background: There is definitive evidence for effectiveness of thrombectomy for acute stroke with large vessel occlusion (LVO). A clinical tool to identify patients with LVO is therefore required for effective triage and prehospital decision making. We developed the FAST VAN tool, which follows from the Heart and Stroke Foundation FAST stroke screen, with the addition of cortical features of vision, aphasia, and neglect, to differentiate from lacunar syndromes. **Methods:** Consecutive acute stroke alerts initiated by emergency medical services (EMS) were prospectively analyzed from April 2017 to Jan 2021. FAST VAN signs were recorded by first responders who had received online education about the tool. These findings were compared to the presence or absence of LVO on CT angiography. Analysis was also performed by appropriateness for comprehensive stroke centers (CSC) transfer if no LVO was present. EMS providers were surveyed regarding ease of use in terms of learning the tool and using in real-world practice. **Results:** Data from 1080 consecutive acute strokes included 440 patients considered to have VAN signs by EMS. Fifty-four percent of VAN-positive patients showed LVO on CTA. Sensitivity, specificity, and accuracy were 86%, 75%, and 77%, respectively. In 204 false-positive cases, 143 (70%) were considered appropriate for evaluation at the CSC. EMS providers reported high satisfaction with learning and using the tool. **Discussion:** The FAST VAN tool for identification of LVO meets desired characteristics of an effective screening tool in ease of use, efficiency, and accuracy. Aphasia remains the most challenging cortical feature to identify accurately.

RÉSUMÉ : L'outil FAST-VAN pour dépister sur le terrain l'occlusion de gros vaisseaux sanguins dans le cas d'AVC en phase aiguë.

Contexte : Il existe des preuves définitives de l'efficacité de la thrombectomie dans le cas d'AVC en phase aiguë associés à l'occlusion de gros vaisseaux sanguins (OGVS). Un outil clinique permettant d'identifier les patients présentant une telle occlusion est par conséquent nécessaire dans le cadre d'un triage médical efficace et d'une prise de décision pré-hospitalisation. Nous avons mis au point l'outil FAST-VAN, qui s'inspire des signes FAST (« Face », « Arms », « Speech », « Time ») de la Fondation des maladies du cœur et de l'AVC du Canada, en y ajoutant les caractéristiques corticales de la vision, de l'aphasie et de la négligence, et ce, afin de différencier entre eux les syndromes lacunaires. **Méthodes :** Des alertes consécutives d'AVC en phase aiguë déclenchées par des services médicaux d'urgence (SMU) ont été analysées prospectivement pour le mois d'avril 2017 au mois de janvier 2021. Les signes obtenus grâce à l'outil FAST-VAN ont été consignés par les premiers intervenants qui avaient reçu une formation en ligne sur cet outil. Ces observations ont été comparées à la présence ou à l'absence d'OGVS dans le cadre d'examen d'angiographie par tomographie par ordinateur. En l'absence d'OGVS, une analyse a également été effectuée en fonction de la pertinence d'un transfert vers un centre de soins complets de l'AVC. Les fournisseurs de SMU ont par ailleurs été interrogés quant à la facilité d'apprentissage de l'outil et d'utilisation dans le monde réel. **Résultats :** Des données se rapportant à 1080 cas consécutifs d'AVC en phase aiguë comprenaient 440 patients considérés comme présentant des signes « VAN » par les SMU. En tout, ce sont 54 % des patients qui donnaient à voir des signes « VAN » qui ont présenté une OGVS dans le cadre d'examen d'angiographie. La sensibilité, la spécificité et la précision ont été respectivement de 86 %, 75 % et 77 %. Sur 204 cas faussement positifs, 143, soit 70 %, ont été considérés comme appropriés pour une évaluation dans un centre de soins complets de l'AVC. Les fournisseurs de SMU se sont par ailleurs déclarés très satisfaits de l'apprentissage et de l'utilisation de l'outil en question. **Discussion :** L'outil FAST-VAN pour l'identification d'OGVS répond aux caractéristiques souhaitées d'un outil de dépistage efficace, et ce, tant en termes de facilité d'utilisation, d'efficacité que de précision. Cela dit, l'aphasie reste la caractéristique corticale la plus difficile à identifier avec précision.

Keywords: Stroke; Large vessel occlusion; Thrombectomy; Screening tool

(Received 13 September 2021; final revisions submitted 21 January 2022; date of acceptance 12 March 2022; First Published online 18 May 2022)

Corresponding author: Gary Hunter, Department of Medicine, Royal University Hospital, 103 Hospital Drive, Saskatoon, SK S7N 0W8, Canada. Email: grwhunter@gmail.com

Cite this article: Wasyliw S, Whelan R, Davy K, Kelly ME, Graham B, Gould L, and Hunter G. (2023) The FAST VAN for Field Identification of Large Vessel Occlusion in Acute Stroke. *The Canadian Journal of Neurological Sciences* 50: 389–392, <https://doi.org/10.1017/cjn.2022.32>

© The Author(s), 2022. Published by Cambridge University Press on behalf of Canadian Neurological Sciences Federation.

Introduction

There is overwhelming evidence for effectiveness of thrombectomy for acute stroke with large vessel occlusion (LVO),¹⁻³ including recent trials with expanded time windows.^{4,5} A clinical tool assessing for presence of cortical signs in LVO will facilitate the accurate identification and efficient transfer of patients to comprehensive stroke centers (CSC), using eligibility criteria based on recently published guidelines.⁶

Many tools have been explored, but these tools have important limitations. One of the most widely used tools has been the Los Angeles Motor Score (LAMS), which scores stroke severity between 0 and 10 based only on the degree of hemiparesis. LAMS has shown some degree of accuracy in predicting LVO by physicians⁷ and prehospital paramedics,⁸ usually with a cutoff score of ≥ 4 . Among physicians, while high sensitivity, specificity, and accuracy are reported, the actual number of patients with LAMS ≥ 4 with LVO is not reported. This foregoes calculation of positive predictive value (PPV), which is arguably the most important statistic as it will most accurately represent the impact of bypass protocols. In the paramedic study, LAMS ≥ 4 was associated with a 37% chance of finding an LVO, but again the raw numbers were not reported. Perhaps the single most important shortcoming of the LAMS score is that it does not follow basic principles of clinical localization by ignoring the significance of cortically based deficits, specifically gaze preference, aphasia, and neglect, such that lacunar strokes with significant hemiparesis will have high LAMS scores with very low likelihood of LVO.

In order to address the importance of cortical features that are commonly associated with middle cerebral artery (MCA) syndromes, other scales have been explored. Tebe et al⁹ developed the Vision Aphasia Neglect (VAN) score, correctly arguing that the presence of these features should differentiate LVO strokes from lacunar syndromes. In a small pilot study of 62 patients conducted with experienced and VAN trained stroke nurses in the emergency room, the VAN tool showed a PPV of 74%, superior to National Institutes of Health (NIH) stroke score of >6 . Limitations of this VAN tool include its length and complexity, differentiating between hemianopias, quadrantanopias, and subtypes of aphasia, which are challenging concepts to distribute to a large number of prehospital care providers, and add little to the likelihood of an LVO beyond the simple presence or absence of any type of aphasia, for example. This VAN tool has yet to be validated in the prehospital setting with large numbers.

The Safe Implementation of Thrombolysis in Stroke International Stroke Thrombolysis Registry (SITS ISTR)¹⁰ retrospectively assessed which NIH items could increase specificity for LVO in patients with a positive FAST screen and found that best gaze could potentially increase the likelihood of LVO with an odds ratio of 4.5. The study only included patients who were treated with acute revascularization, indicating a problematic selection bias when calculating specificity, since hemorrhage and stroke mimics had already been excluded, such that external validity to the prehospital setting is very limited. Finally, aphasia and neglect are not assessed, which are the two primary features of LVO in dominant and non-dominant MCA syndromes, respectively, and are disabling problems that may be present without a gaze preference.

Most recently, the Ambulance clinical triage (ACT-FAST) tool was published,¹¹ which used the presence of hemiparesis to guide next steps in assessment of aphasia (with right hemiparesis) or neglect (with left hemiparesis), followed by a screen for eligibility

Table 1: FAST VAN components

Test item	Directions
Vision	Is there a gaze preference to either side (usually away from the hemiparesis)?
Aphasia	Ask the patient to name simple objects (ie: watch, pen).
Neglect	With eyes closed, touch each arm independently and ask which side is being touched. Then touch both simultaneously. If neglect is present the patient will only report one side being touched, almost always neglecting the left side.

or stroke mimics. An elaborate validation algorithm based on retrospective chart review of NIHSS items most likely to be seen with LVO led to selection of the above- described features. The results among 60 patients who underwent assessment by paramedics using the full ACT-FAST algorithm were sensitivity of 86%, specificity of 94%, and PPV of 80% for identification of M1 occlusion on CTA. In prospective assessment with the ACT-FAST examination steps (N = 104), PPV was 56%. The ACT FAST algorithm is therefore accurate with acceptable specificity and sensitivity, although there remains a 15% false negative rate. Additional limitations include the small number of prospectively validated results, a variable exam based on initial findings, potentially inaccurate language screen with no requirement to name objects, exclusion of isolated aphasias which are disabling, and exclusion of gaze preference in patients with right hemiparesis. Finally, the eligibility criteria are extensive at eight items, and the 6-hour time window excludes patients who have been shown to benefit based on DAWN and DEFUSE-3 criteria^{4,5} and recommendations in AHA guidelines.⁶

A useful clinical tool should be rapid, easily learned, follow basic principles of localization, and avoid the requirement to calculate scores.¹² Based on these criteria and limitations of existing tools, we developed the FAST VAN tool as a brief and easily implemented modification of the original VAN screen.⁹ Currently, most acute stroke patients are screened by paramedics on scene with the existing Heart and Stroke Foundation FAST tool (Face, Arm, Speech, Time), which identifies patients likely to be suffering a stroke on the basis of hemiparesis and/or change in speech. The VAN screen is then applied to identify features associated with LVO.

Components of the VAN screen were conceived and validated based on principles of localization and designed to maintain simplicity and speed without sacrificing accuracy (Table 1). We hypothesized that any single positive VAN finding would predict LVO with high accuracy, such that there is no requirement to calculate a score. The vision assessment is simply the presence or absence of a gaze preference away from the hemiparesis. Gaze preference can be seen toward hemiparesis in the setting of thalamic or pontine strokes and therefore remains valid in the setting of posterior circulation strokes, although the primary target is MCA syndromes. Language is tested with naming objects. Since all types of aphasias share the common feature of impaired naming, this suffices as a screen for aphasia (name a pen, watch, or other available high frequency items), supported by other basic assessments during acquisition of the clinical history. Any errors in naming of high frequency words, in the absence of confounds such as delirium, represent a positive screen for aphasia. Neglect is screened with double simultaneous tactile stimulation as per usual practice.

Visual field defects are considered technically challenging to teach and execute in the field, and more often relate to PCA syndromes in the absence of other FAST VAN signs, and they were therefore excluded from the tool. Hemiparesis has already been screened as either present or absent via the FAST tool, and since degree of hemiparesis does not reliably distinguish between large and small vessel syndromes, further quantification was excluded from the VAN tool.

The FAST VAN tool was studied to determine its accuracy in identifying LVOs in real-world prehospital settings. We hypothesize that the FAST VAN tool will show high sensitivity, acceptable specificity, and PPV superior to other tools and be easily learned and implemented.

Methods

Consecutive acute strokes were analyzed between April 2017 and Jan 2021. The presence or absence of VAN signs was recorded, as determined by emergency medical services (EMS) providers who initiated acute stroke protocols. These findings were compared to the presence or absence of LVO on CT angiography (CTA) performed at the time of presentation. The presence of LVO was defined as a cervical or intracranial anterior circulation occlusion or near occlusion that would potentially be amenable to mechanical thrombectomy. Practically, this includes acute symptomatic cervical or intracranial carotid occlusion, or intracranial occlusion of MCA in either M1 or proximal M2 segments. Patients were excluded from the study if no CTA was performed, and the rest of the imaging was normal. Patients with abnormal imaging including hemorrhages, neoplasms, etc. with VAN signs were included as false positives. Patients with migrainous aphasia, delirium, or other non-stroke diagnoses were included as false positives if CTA was performed. EMS training consisted of a locally developed 10-minute video explaining the rationale and examination technique for the FAST VAN tool.

False positives were categorized as appropriate for CSC if urgent assessment by neurology or neurosurgery was ultimately required for other indications, since these would not be considered futile transfers. False positives were considered inappropriate for CSC if the final diagnosis was deemed VAN-positive stroke without LVO that would be amenable to treatment at the PSC, other relatively benign stroke mimics, or no stroke related diagnosis. Qualitative feedback was sought from EMS providers regarding time required for training, ease of use, and perceived utility.

Results

Comprehensive data from 1080 consecutive acute stroke patients were analyzed (Figure 1). Four-hundred forty patients were screened as having VAN signs or symptoms by EMS providers, among whom 236 (54%) demonstrated a symptomatic LVO that was considered potentially amenable to thrombectomy (Table 2). Sensitivity was 86% and specificity was 75%. Overall accuracy was 77%. Among 204 false-positive cases, 143 (70%) were considered appropriate for assessment at the CSC based on final diagnosis.

False positives were primarily related to intracranial hemorrhages or ischemic stroke without proximal LVO. Delirium and seizures were other common causes of false-positive FAST VAN screening by EMS (Table 3).

Among 34 patients with isolated aphasia (no hemiparesis) as their primary complaint, 10 (29%) had a symptomatic LVO

Table 2: FAST VAN results

	LVO+	LVO-		
FAST VAN+	236	204	440	PPV 0.54
FAST VAN-	40	600	640	NPV 0.94
	276	801	1080	
	Sensitivity		Specificity	
	86%	75%	Accuracy	77%

Table 3: False positives by etiology (N = 204)

Final diagnosis	Number of cases
Stroke without LVO	69
Intracranial Hemorrhage	47
Delirium/encephalopathy	30
Seizure	23
TIA	14
Other	21
Total	204

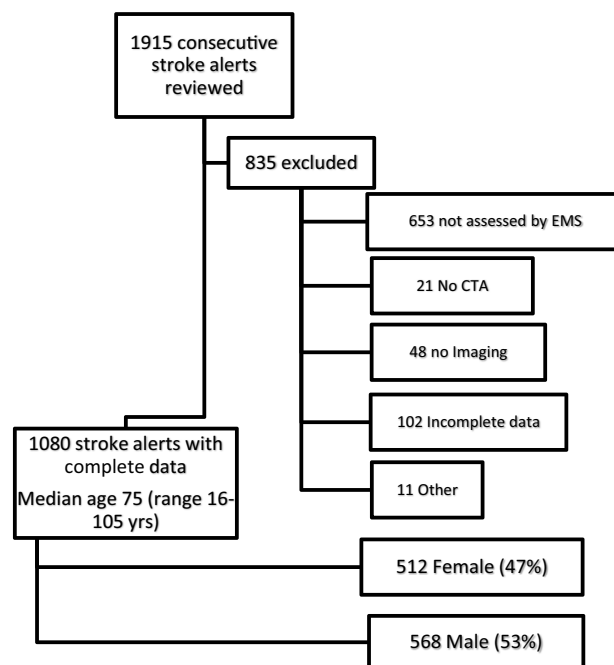


Figure 1: Diagram summarizing the data from the 1080 consecutive acute stroke patients included in the study.

considered amenable to thrombectomy. Two of these 10 patients underwent mechanical thrombectomy.

We received qualitative data from 44 EMS providers. In response to the question “how confident are you that you can perform the examination correctly? (1 = not confident, 10 = very confident)”, 73% responded between 8 and 10, with a median of 8. On a separate 10-point scale, 77% reported the ease of learning the examination between 1 and 3 (lower numbers indicating

easier) out of 10. Eighty-nine percent understood the purpose of the FAST VAN tool in the identification of LVO, and 96% of providers had used the tool in patient contact since receiving training.

Discussion

The FAST VAN tool for identification of LVO has shown high sensitivity, specificity, and accuracy in large number of patients and follows basic principles of neurologic localization. Based on our findings, this tool has been adopted for clinical practice and triage of stroke patients in Saskatchewan and British Columbia. In comparison to previously published tools, the FAST VAN offers simplicity, speed, ease of use, and exclusion of mandatory scoring, without sacrificing accuracy. Web-based training has been efficient and well-received by care providers and has facilitated interprovincial collaboration. Qualitative responses from EMS support ease of implementation and good understanding of the tool. Most false-positive cases were considered appropriate for assessment at the PSC based on final diagnosis, indicating very low overall rate of futile transfers.

Challenges in identifying posterior circulation strokes remain; fortunately, these are relatively rare diagnoses compared to anterior circulation strokes. However, a gaze preference may be seen in both thalamic and pontine strokes, although they can be toward the hemiparesis (so called “wrong-way eyes”). It seems likely that a gaze preference will still be noted by providers, and in the setting of a hemiparesis still permit appropriate escalation of care based on the FAST VAN tool.

This is the largest real-world study of LVO screening tools in the prehospital setting to our knowledge. The main limitation of this tool is the potential for false positives in the setting of isolated aphasia, which could meet criteria of both FAST and VAN with a low NIHSS score. One source of error is the finding that non-aphasic patients are occasionally called aphasic, when in fact the patient may simply be delirious, or have dysarthria, which may be seen in lacunar or large vessel syndromes. However, aphasia is considered highly disabling, and excluding isolated aphasia due to absence of hemiparesis could lead to missed opportunities for improved outcomes if there is a reasonable incidence of LVO in this population. We found that almost 30% of patients with isolated aphasia demonstrated an LVO, suggesting that this finding should be included in the target population for triggering LVO stroke protocols. Most false-positive cases in this series were considered appropriate for transfer to CSC based on final diagnosis. We recommend that all stroke systems should employ a screening tool for identifying LVO in the prehospital setting.

Acknowledgments. The author(s) received no financial support for the research, authorship, and/or publication of this article.

Disclosures. The following authors have no conflicts of interests or disclosures: Sanchea Wasyliv, Ruth Whelan, Kim Davy, Layla Gould, and Gary Hunter. Brett Graham and Mike Kelly are board members for the Heart and Stroke Provincial Board. Mike Kelly is also the Saskatchewan Clinical Stroke Research Chair and reported a consulting fee for Imperative Care for an unrelated medical device.

Statement of Authorship. SW contributed to study design and manuscript review. RW contributed to the study design, data collection, data analysis, and manuscript preparation. KD carried out the data analysis and manuscript review. MK and BG reviewed the manuscript and contributed to the draft of the manuscript. LG contributed to the manuscript review, manuscript submission, and performed the journal administration duties. GH contributed to the study design, data collection, data analysis, and manuscript preparation.

References

- Goyal M, Demchuk A, Menon B, et al. Randomized assessment of rapid endovascular treatment of ischemic stroke. *N Engl J Med.* 2015;372:1019–30.
- Campbell B, Mitchell P, Kleinig T, et al. Endovascular therapy for ischemic stroke with perfusion-imaging selection. *N Engl J Med.* 2015;372:1009–18.
- Berkhemer O, Fransen P, van den Berg L, et al. A randomized trial of intra-arterial treatment for acute ischemic stroke. *N Engl J Med.* 2015;372:11–20.
- Nogueira R, Jadhav A, Haussen D. Thrombectomy 6 to 24 hours after stroke with a mismatch between deficit and infarct. *N Engl J Med.* 2018;378:11–21.
- Albers G, Marks M, Kemp S, et al. Thrombectomy for stroke at 6 to 16 hours with selection by perfusion imaging. *N Engl J Med.* 2018;378:708–18.
- Powers W, Rabinstein A, Ackerson T, et al. Guidelines for the early management of patients with acute ischemic stroke: a guideline for healthcare professionals from the American Heart Association/American Stroke Association. *Stroke.* 2018;49:e46–99.
- Nazliel B, Starkman S, Liebeskind D, et al. A brief prehospital stroke severity scale identifies ischemic stroke patients harboring persisting large arterial occlusions. *Stroke.* 2008;39:2264–7.
- Noorian A, Sanossian N, Shkirkova K, et al. Los Angeles motor scale to identify large vessel occlusion - prehospital validation and comparison with other screens. *Stroke.* 2018;49:565–72.
- Teleb M, Ver Hage A, Carter J, et al. Stroke vision, aphasia, neglect (VAN) assessment—a novel emergent large vessel occlusion screening tool: pilot study and comparison with current clinical severity indices. *J Neurointerv Surg.* 2017;9:122–6.
- Scheitz J, Abdul-Rahim A, MacIsaac R, et al. Clinical selection strategies to identify ischemic stroke patients with large anterior vessel occlusion: results from SITS-ISTR (safe implementation of thrombolysis in stroke international stroke thrombolysis registry). *Stroke.* 2017;48:290–7.
- Zhao H, Pesavento L, Coote S, et al. Ambulance clinical triage for acute stroke treatment paramedic triage algorithm for large vessel occlusion. *Stroke.* 2018;49:945–51.
- Michel P. Prehospital scales for large vessel occlusion closing in on a moving target. *Stroke.* 2017;48:247–9.