

Molecular characterization and distribution of *Plasmodium matutinum*, a common avian malaria parasite

GEDIMINAS VALKIŪNAS*, MIKAS ILGŪNAS, DOVILĖ BUKAUSKAITĖ, VAIDAS PALINAUSKAS, RASA BERNOTIENĖ and TATJANA A. IEZHOVA

Nature Research Centre, Akademijos 2, Vilnius 2100, LT-08412, Lithuania

(Received 3 February 2017; revised 25 April 2017; accepted 26 April 2017; first published online 21 September 2017)

SUMMARY

Species of *Plasmodium* (Plasmodiidae, Haemosporida) are widespread and cause malaria, which can be severe in avian hosts. Molecular markers are essential to detect and identify parasites, but still absent for many avian malaria and related haemosporidian species. Here, we provide first molecular characterization of *Plasmodium matutinum*, a common agent of avian malaria. This parasite was isolated from a naturally infected thrush nightingale *Luscinia luscinia* (Muscicapidae). Fragments of mitochondrial, apicoplast and nuclear genomes were obtained. Domestic canaries *Serinus canaria* were susceptible after inoculation of infected blood, and the long-lasting light parasitemia developed in two exposed birds. Clinical signs of illness were not reported. Illustrations of blood stages of *P. matutinum* (pLINN1) are given, and phylogenetic analysis identified the closely related avian *Plasmodium* species. The phylogeny based on partial cytochrome *b* (cyt *b*) sequences suggests that this parasite is most closely related to *Plasmodium tejerai* (cyt *b* lineage pSPMAG01), a common malaria parasite of American birds. Both these parasites belong to subgenus *Haemamoeba*, and their blood stages are similar morphologically, particularly due to marked vacuolization of the cytoplasm in growing erythrocytic meronts. Molecular data show that transmission of *P. matutinum* (pLINN1) occurs broadly in the Holarctic, and the parasite likely is of cosmopolitan distribution. Passeriform birds and *Culex* mosquitoes are common hosts. This study provides first molecular markers for detection of *P. matutinum*.

Key words: Avian malaria, *Plasmodium matutinum*, molecular characterization, distribution, vectors, birds.

INTRODUCTION

Avian malaria is caused by over 50 described species of *Plasmodium* (Plasmodiidae, Haemosporida), which are of global distribution (Bennett *et al.* 1982; Atkinson *et al.* 2008; Marzal, 2012; Perkins, 2014). Diversity of these parasites is greatest in tropics, but some *Plasmodium* species are actively transmitted in temperate climates and have been recently reported even in high arctic tundra (Valkiūnas, 2005; Oakgrove *et al.* 2014). Birds suffer of malaria all over the world, but this disease is absent from Antarctica, most likely because of the absence of suitable vectors and insufficient air temperature for completing of sporogonic development.

Avian malaria is often more severe disease than mammal malaria (Garnham, 1966; Gabaldon and Ulloa, 1980; Ilgūnas *et al.* 2016). In birds, species of *Plasmodium* and related haemosporidian parasites cause not only blood pathology due to high parasitaemia, which is the main reason of pathology during malaria in mammals (Sherman, 1998), but also due to damage of various organs by exoerythrocytic meronts, which develop in reticular-endothelial cells and can be present all over the body in susceptible avian hosts (Garnham, 1966; Valkiūnas, 2005;

Vanstreels *et al.* 2015; Ilgūnas *et al.* 2016). Detection and identification of haemosporidian tissue stages are difficult, and the majority of recent wildlife studies deal only with the relatively easy to access blood stages of these parasites (Bensch *et al.* 2009; Clark *et al.* 2014; Perkins, 2014). However, the application of histological and chromogenic *in situ* hybridization methods provided evidence that common *Plasmodium* parasite lineages cause disease and even mortality in birds due to damage of organs by the exoerythrocytic stages (Dinhopl *et al.* 2015; Ilgūnas *et al.* 2016; Palinauskas *et al.* 2016). It is important to note that mortality due to internal organ pathology may occur before development of parasitemia, and such haemosporidian infections are particularly difficult to diagnose using microscopic tools (Donovan *et al.* 2008; Valkiūnas *et al.* 2014; Valkiūnas and Iezhova, 2017). If tissue stages are reported by microscopic examination in dead birds, it is often difficult or even impossible to identify species, subgenera and sometimes even families of reported haemosporidian parasites when solely morphological characters are available (Garnham, 1966; Walker and Garnham, 1972; Valkiūnas *et al.* 2014). The exoerythrocytic development remains insufficiently investigated in the majority of avian haemosporidian species because of the difficulties to access and identify reported parasites in organs, particularly in wild animals. Molecular markers are essential for rapid and precise diagnostic of avian malaria, but

* Corresponding author: Nature Research Centre, Akademijos 2, LT-08412 Vilnius, Lithuania. E-mail: gedvalk@ekoi.lt

remain unknown for the majority of described *Plasmodium* and other related haemosporidian species (Bensch *et al.* 2009; Clark *et al.* 2014). That is an obstacle for detection of malaria and other wild-life haemosporidian infections. The same parasite diagnostic problems remain during examination of sporogonic stages of haemosporidians in wild-caught vectors (Valkiūnas *et al.* 2013a,b). Haemosporidian molecular markers are needed for the veterinary parasitology research (Dinhopl *et al.* 2015), and they are essential for evolutionary biology studies as well during determining cryptic speciation in these parasites (Outlaw and Ricklefs, 2014; Palinauskas *et al.* 2015; Bensch *et al.* 2016; Nilsson *et al.* 2016).

During an on-going research on evolutionary biology, ecology and virulence of avian blood parasites (Dimitrov *et al.* 2016; Ilgūnas *et al.* 2016; Palinauskas *et al.* 2016; Valkiūnas *et al.* 2016), *Plasmodium matutinum* was found in the thrush nightingale *Luscinia luscinia* (Muscicapidae) during spring migration in Lithuania. According to the former microscopic studies (Garnham, 1966; Valkiūnas, 2005), this parasite was reported in the Holarctic birds, but its molecular characterization is absent. The aims of this study were (1) to develop molecular characterization of *P. matutinum*, (2) to determine its phylogenetic relationships with other avian *Plasmodium* spp. and (3) to specify the host range and distribution of this parasite lineage.

MATERIAL AND METHODS

Collection of blood samples

In all, 11 thrush nightingales *L. luscinia* (Muscicapidae) were caught with mist nets and large stationary traps at the Ventės Ragas Ornithological Station, Lithuania between 11 and 27 May, 2016. About 30 µL of whole blood was taken in heparinized microcapillaries and stored in SET buffer (Hellgren *et al.* 2004) for molecular analysis. Three blood films were prepared, air-dried, fixed in absolute methanol and stained with Giemsa (Valkiūnas, 2005).

One blood film from each bird was rapidly stained and examined microscopically, as described by Valkiūnas *et al.* (2016). One nightingale infected with an unidentified lineage of *P. matutinum* was determined and used for the strain isolation during this study. Infected blood was collected in heparinized microcapillaries and used to expose two uninfected domestic canaries by subinoculation of about 250 µL of freshly prepared mixture, containing the infected blood and anticoagulant in the pectoral muscle, as described by Iezhova *et al.* (2005). Blood samples from donor nightingale were also cryopreserved for future research, as described by Garnham (1966). The donor nightingale was released.

Both recipient canaries were proven to be uninfected with haemosporidian parasites by microscopic

examination of blood films and polymerase chain reaction (PCR)-based testing in the laboratory (see below). These birds were kept indoors in a vector-free room for a 4-month period postexposure. Blood was taken for microscopic examination and PCR-based testing as described above 5 days postexposure (dpe) for the first time, then once per 3 or 4 days during the first 2 months postexposure and once per month during the remaining experiment time. Parasitemia developed in both exposed canaries.

DNA extraction, PCR and sequencing

Total DNA was extracted from whole blood using the ammonium-acetate protocol (Sambrook *et al.* 1989). Quantification of the DNA was performed by using a NanoDrop spectrophotometer (Implen NanoPhotometer P330). Four established PCR assays were used for detection of *P. matutinum* infection from the blood of experimentally exposed canaries. Presence of parasites was confirmed by microscopic examination in the corresponding blood films. Two of these PCR assays used primer sets, which amplify DNA fragments of mitochondrial genome, one of apicoplast genome and one of nuclear genome. The following partial sequences of mitochondrial genome were obtained: cytochrome *b* (cyt *b*) gene (primer set HaemNFI/NR3 and HAEMF/R2, Bensch *et al.* 2000; Hellgren *et al.* 2004) and cytochrome oxidase subunit I (COI) gene (primer set COIF/R and COIF2/R2, Martinsen *et al.* 2008). Apicoplast gene (*clpc*) sequences were obtained using the primer set ClpcF/R and ClpcF2/R2 (Martinsen *et al.* 2008). Nuclear DNA apical membrane antigen-1 (AMA1) gene fragment sequences were obtained using primer set Pg_AMA1F1/R1 and Pg_AMA1F2/R2 (Lauron *et al.* 2014). All reactions were performed in 25 µL total volumes, including 50 ng of a total genomic DNA template (2 µL), 12.5 µL of DreamTaq Master Mix (Thermo Fisher Scientific, Lithuania), 8.5 µL nuclease-free water and 1 µL of each primer. One negative control (nuclease-free water) and one positive control (extracted parasite DNA from a blood sample, which was confirmed positive by microscopic examination of blood films) were used to control for false amplifications. Temperature profiles in all PCRs were the same as in the original protocol descriptions. The amplification success was evaluated after running of 2 µL of PCR product on 2% agarose gels. PCR products (21 µL) were purified by adding 11 µL of 8 M NH₄Ac, 37 µL of 96% and 150 µL of 70% ethanol. After centrifugation, air-dried DNA pellets were dissolved in 16 µL of ddH₂O. Positive amplifications were sequenced using Big Dye Terminator V3.1 Cycle Sequencing Kit and then loaded on an ABI PRISM™ 3100 capillary sequencing robot (Applied Biosystems, Foster City, California). The

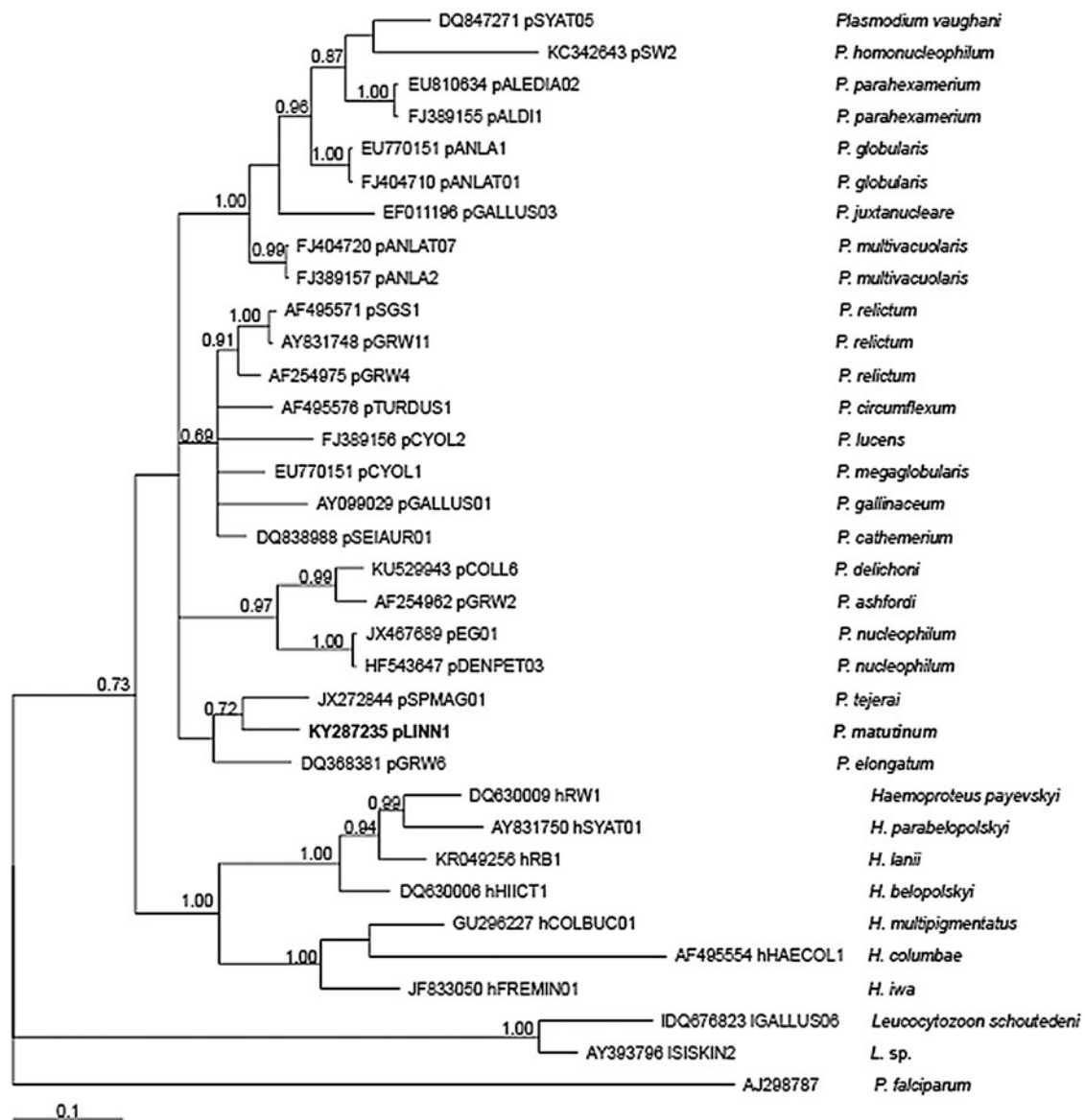


Fig. 1. Bayesian phylogeny of 24 mitochondrial cytochrome *b* lineages of *Plasmodium* species, seven lineages of *Haemoproteus* spp. and two lineages of *Leucocytozoon* spp. One lineage of *Plasmodium falciparum* is used as outgroup. GenBank accession numbers of lineages are given, followed with codes of the lineages (according to MalAvi database, <http://mbio-serv2.mbioekol.lu.se/Malavi>) and parasite names. Posterior probabilities >0.69 are indicated near the nodes. The branch lengths are drawn proportionally to the amount of change (scale bar is shown). Bold font indicates *Plasmodium matutinum*.

sequences were edited and aligned using BioEdit software (Hall, 1999). The BLAST algorithm (<http://blast.ncbi.nlm.nih.gov/Blast.cgi>) was used to compare detected sequences with those deposited in GenBank. All detected sequences were deposited in GenBank (see parasite description).

Phylogenetic analysis

The phylogenetic relationship of the lineage pLINN1 of *P. matutinum* and other avian malaria parasites was inferred using 24 mitochondrial *cyt b* gene sequences of avian *Plasmodium* species, seven of *Haemoproteus* spp. and two of *Leucocytozoon* spp. The sequences were selected from GenBank and

MalAvi database (Bensch *et al.* 2009). *Plasmodium falciparum* was used as outgroup. The GenBank accession numbers of the used sequences and codes of the lineages are given in Fig. 1.

The phylogenetic tree was constructed using Bayesian phylogenetic analysis as implemented in mrBayes version 3.1 (Ronquist and Huelsenbeck, 2003). The General Time Reversible Model including invariable sites and variation among sites (GTR + I + G) was used as suggested by the software MrModeltest 2.2 (<http://www.abc.se/~nylander/mrmodeltest2/MrModelblock>). Two independent runs were performed. Each analysis was run for a total of 5 million generations with a sampling frequency of every 100 generations. Before constructing

a majority consensus tree, 25% of the initial trees in each run were discarded as ‘burn in’ periods. The tree was visualized using the software Tree View 1.6.6. (<http://evolution.genetics.washington.edu/phylog/phylog.html>).

The sequence divergence between different lineages was calculated according to the Jukes–Cantor model of substitution; the programme MEGA 6.0 was used (Tamura *et al.* 2013). Presence of possible co-infections of malaria parasites in samples from exposed canaries was ruled out due to the absence of double-base calling in sequence electropherograms (Pérez-Tris and Bensch, 2005).

Microscopic examination of blood films and voucher material

An Olympus BX61 light microscope equipped with imaging software AnalySIS FIVE were used in morphological analysis (for details see Valkiūnas *et al.* 2016). Intensity of parasitemia was calculated as a percentage by actual counting of the number of parasites per 10 000 red blood cells. The analyses were carried out using the ‘Statistica 7’ package. Voucher preparations of blood stages of *P. matutinum* (pLINN1) from nightingale as well as the whole blood samples fixed in SET buffer and the cryopreserved infected blood were deposited in Nature Research Centre, Vilnius, Lithuania (see description of the parasite).

Ethical statement

Experimental procedures were approved by the Lithuanian State Food and Veterinary Office (permit 2015-05-07, no. G2-27) and Environmental Protection Agency, Vilnius (permit 2016-05-05, no. 23).

RESULTS

Single malaria infection of *P. matutinum* was identified in the donor thrush nightingale; other *Plasmodium* species were not reported neither by microscopic examination of blood films, nor PCR-based tools. However, a *Haemoproteus balmorali* (Haemosporida, Haemoproteidae) co-infection was present. Both exposed canaries were susceptible and developed single infection of the same malaria parasite, as determined both by microscopic examination of blood films and PCR-based testing. Canaries were resistant to *Haemoproteus* infection, which was absent from the both exposed birds, providing opportunities to deal with single *P. matutinum* (pLINN1) infection during parasite morphological and molecular characterization. The lineage pLINN1 of *P. matutinum* was identified; it clustered with other lineages of malaria parasites and was well distinguishable in the phylogenetic tree (Fig. 1).

Description of parasite

Plasmodium (Haemamoeba) matutinum Huff, 1937 (Fig. 2A–L).

DNA sequences: Mitochondrial cyt *b* lineage pLINN1 (479 bp, GenBank accession no. KY287235). Additional sequences: COI gene (881 bp), *clpc* (495 bp) and nuclear AMA1 (455 bp), with GenBank accession numbers KY471295, KY471294 and KY471296, respectively.

Avian hosts and distribution: The lineage pLINN1 has been reported in North America, Europe, Asia and New Zealand. It was found in 20 species of birds belonging to 14 families and five orders (Table 1).

Vectors: Remain unidentified. The lineage pLINN1 was found in *Culex pipiens* mosquitoes in Iberian Peninsula and the USA (Table 1). This mosquito is a probable vector of this parasite lineage both in Europe and America.

Site of infection: Red blood cells; no other data.

Representative blood films: Voucher specimens (accession numbers 48772–48775 NS, *L. luscinia*, May 2016, collected by D. Bukauskaitė) were deposited in Nature Research Centre, Vilnius, Lithuania.

Additional material: Representative blood samples from the thrush nightingale *L. luscinia* were fixed in SET buffer (accessions numbers 9/16R, 101/16v–103/16v) and also cryopreserved (accessions biobank numbers Cv458/16v–Cv460/16v); this material was deposited in Nature Research Centre, Vilnius.

Prevalence: The overall prevalence was 1 of 11 (9.1%) in thrush nightingales at the study site.

Parasitemia and virulence: All blood stages were reported in the peripheral circulation in the exposed canaries. Prepatent period was about 5 dpe. Light parasitemia developed, with maximum intensity of 0.01% in both exposed birds 10 dpe. The parasitemia remained light or even declined into latency within 1 month postexposure, with a few parasites appearing in the circulation occasionally during entire observation time. The exposed canaries survived to the end of this study; they looked healthy. The clinical signs of disease were not observed during this study.

Morphology of blood stages was the same in the thrush nightingale and the experimentally exposed canaries. The parasite description is based on preparations with parasitemia of 2% in thrush nightingale (Fig. 2).

Trophozoites (Fig. 2A and B) develop in polychromatic and mature erythrocytes. Multiple infection of red blood cells is common (Fig. 2A). Earliest trophozoites are variable in form, often irregular or amoeboid in outline (Fig. 2A); they do not displace or only slightly displace nuclei of infected erythrocytes laterally. Growing and advanced trophozoites possess prominent nuclei, and a vacuole was often seen in the cytoplasm of the largest parasites (Fig. 2B).

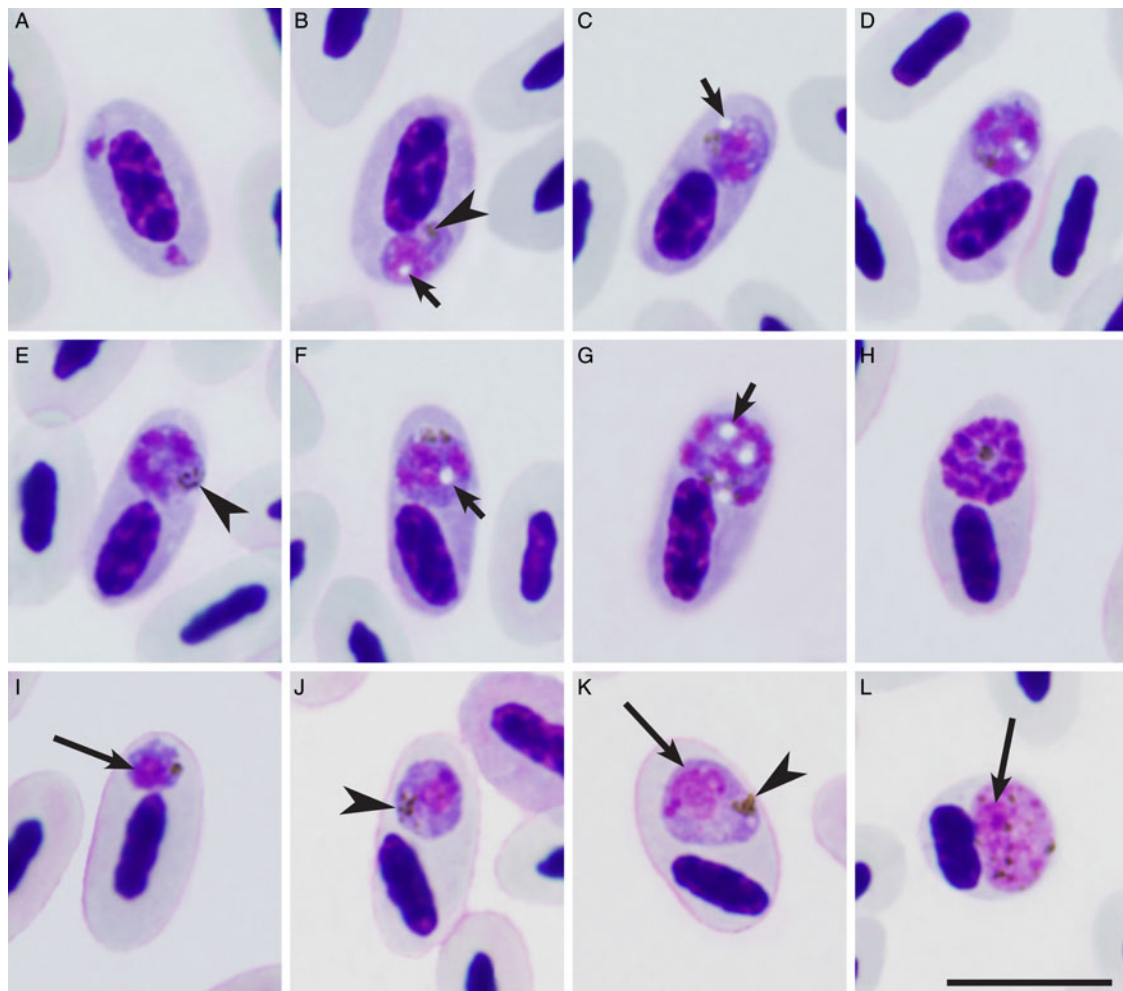


Fig. 2. *Plasmodium (Haemamoeba) matutinum* (cytochrome *b* lineage pLINN1) from the blood of thrush nightingale *Luscinia luscinia*: a and b, trophozoites; c–h, erythrocytic meronts; i–k, macrogametocytes; l, microgametocyte. Long arrows, nuclei of parasites; short arrows, vacuoles, arrow heads, pigment granules. Note presence of large circular vacuoles in the majority of growing erythrocytic meronts (c, d, f and g), and their absence in mature meront (h). Giemsa-stained thin blood films. Bar = 10 μm .

Pigment granules are small ($<0.5 \mu\text{m}$), few, dark-brown and usually grouped (Fig. 2B). Largest trophozoites slightly displace nuclei of host cells (Fig. 2B).

Erythrocytic meronts (Fig. 2C–H) develop in polychromatic and mature erythrocytes. Growing meronts possess the plentiful cytoplasm and large nuclei, which size markedly decreases as the parasites mature (compare Fig. 2D with Fig. 2H). Clearly visible circular vacuoles, which may be up to $1.5 \mu\text{m}$ in largest diameter are present in many maturing meronts (Fig. 2C, D, F and G), and that is the most readily distinguishable character of this parasite species. Up to five such vacuoles may occur in large maturing meronts. Vacuoles gradually disappear in mature meronts (Fig. 2H). Pigment granules are small ($<0.5 \mu\text{m}$), dark-brown or black, usually clumped and are difficult to calculate (Fig. 2E); they do not gather around vacuoles, a characteristic feature of this parasite species. Numerous mature meronts were reported in the morning,

indicating a 24-h merogony cycle. Number of merozoites in mature meronts is 14–28 (on average 18.2 ± 4.4); the majority of meronts produce 16–18 merozoites, which are arranged haphazardly (Fig. 2H). Growing and mature meronts markedly displace nuclei of infected erythrocytes (Fig. 2C–H) and sometimes even enucleate the host cells.

Macrogametocytes (Fig. 2I–K) develop mainly in mature erythrocytes, but occasionally were also seen in polychromatic erythrocytes. Growing and mature gametocytes are of roundish form, possess prominent nuclei; small vacuoles were seen occasionally. Pigment granules are small ($<0.5 \mu\text{m}$), black or dark-brown, roundish, scattered in the cytoplasm or sometimes grouped (Fig. 2I–K). Gametocytes markedly deform infected red blood cells and displace their nuclei toward one of poles of the host cells; they can enucleate the infected cells. Fully-grown gametocytes are relatively small; they do not exceed $10 \mu\text{m}$ in their largest diameter, a characteristic feature of this *Haemamoeba* species.

Table 1. Hosts and locations where the pLINN1 lineage of *Plasmodium matutum* has been reported

Order and family	Species	Location	Reference
Diptera			
Culicidae	<i>Culex pipiens</i>	Italy, USA	Kimura <i>et al.</i> (2010); Martínez-de la Puente <i>et al.</i> (2015)
Apterygiformes			
Apterygidae	<i>Apteryx haastii</i> <i>Apteryx mantelli</i>	New Zealand	Howe <i>et al.</i> (2012); Sijbranda <i>et al.</i> (2016)
Gruiformes			
Rallidae	<i>Fulica cristata</i>	Spain	Ferraguti <i>et al.</i> (2013)
Passeriformes			
Callaeidae	<i>Philesturnus carunculatus</i>	New Zealand	Castro <i>et al.</i> (2011)
Carduelidae	<i>Carduelis cannabina</i>	Sweden	Hellgren <i>et al.</i> (2007); Nilsson <i>et al.</i> (2016)
Corvidae	<i>Corvus cornix cornix</i>	Italy	GenBank (unpublished)
Meliphagidae	<i>Anthornis melanura</i>	New Zealand	Ewen <i>et al.</i> (2012)
Muscicapidae	<i>Erithacus rubecula</i>	North-western Iberia (NWI), WGC, Germany	Drovetski <i>et al.</i> (2014); Mata <i>et al.</i> (2015); Santiago-Alarcon <i>et al.</i> (2016)
	<i>Luscinia luscinia</i> ^a	Lithuania	This study
	<i>Luscinia svecica</i>	Czech Republic	Svoboda <i>et al.</i> (2015)
Paridae	<i>Baeolophus bicolor</i> <i>Cyanistes caeruleus</i>	USA UK, WGC	Fast <i>et al.</i> (2016) Wood <i>et al.</i> (2007); Cosgrove <i>et al.</i> (2008); Szöllősi <i>et al.</i> (2011); Drovetski <i>et al.</i> (2014); Mata <i>et al.</i> (2015)
Passeridae	<i>Passer montanus</i>	Italy ^b	Martínez-de la Puente <i>et al.</i> (2015)
Petroicidae	<i>Petroica longipes</i>	New Zealand	Sijbranda <i>et al.</i> (2016)
Turdidae	<i>Turdus merula</i>	Portugal, New Zealand, NWI, WGC, Italy ^b , Germany, Russia ^c	Hellgren <i>et al.</i> (2011); Howe <i>et al.</i> (2012); Ewen <i>et al.</i> (2012); Drovetski <i>et al.</i> (2014); Mata <i>et al.</i> (2015); Martínez-de la Puente <i>et al.</i> (2015); Santiago-Alarcon <i>et al.</i> (2016); Sijbranda <i>et al.</i> (2016)
	<i>Turdus philomelos</i>	New Zealand, NWI, South Caucasus	Ewen <i>et al.</i> (2012); Drovetski <i>et al.</i> (2014); Mata <i>et al.</i> (2015); Sijbranda <i>et al.</i> (2016)
Zosteropidae	<i>Zosterops lateralis</i>	New Zealand	Sijbranda <i>et al.</i> (2016)
Sphenisciformes			
Spheniscidae	<i>Spheniscus humboldti</i> <i>Eudyptula minor</i>	Japan, New Zealand	Sijbranda (2015); GenBank (unpublished)
Strigiformes			
Strigidae	<i>Athene noctua</i>	Italy ^b	Martínez-de la Puente <i>et al.</i> (2015)

WGC, Western Greater Caucasus.

^a Reports supported by microscopic examination of blood films. Records from other hosts were based solely on PCR-based diagnostic; it remains unclear if life cycle completes and invasive stages develop in these hosts.

^b Reports from mosquito blood meals. Bird species were identified using PCR-based diagnostic, which identified DNA of corresponding avian hosts in tested mosquitoes.

^c Report from the Biological Station Rybachy, Kaliningrad District, Russia (unpublished data).

Microgametocytes (Fig. 2L). General configuration and other features are as for macrogametocytes, with usual haemosporidian sexual dimorphic characters, which are the pale staining of the cytoplasm and the diffuse large nuclei.

Morphometric features of blood stages of *P. matutinum* (pLINN1) were similar to those described formerly in this species (Valkiūnas, 2005).

Remarks

Plasmodium matutinum can be readily distinguished from the majority of species of subgenus *Haemamoeba* due to presence of large circular vacuoles in its growing erythrocytic meronts (Fig. 2G). Large vacuoles were also described in the erythrocytic meronts of *Plasmodium griffithsi* (Garnham, 1966), *Plasmodium tejeraei* (Gabaldon and Ulloa, 1977) and *Plasmodium giovannolai* (Corradetti *et al.* 1963). In *P. griffithsi*, erythrocytic meronts contain residual bodies, and elongate gametocytes develop. Both these characters are not features of *P. matutinum* (Fig. 2). In *P. tejeraei*, the vacuoles often exceed 2 µm in diameter, and pigment granules gather around the vacuoles; that are not characters of *P. matutinum*. *Plasmodium giovannolai* is most similar to *P. matutinum* (Valkiūnas, 2005). The latter parasite can be distinguished due to the smaller size of pigment granules in its gametocytes and the presence of vacuoles in growing trophozoites (Fig. 2B). Molecular characterization of *P. giovannolai* is absent.

Phylogenetic relationships of parasites

Partial DNA sequences of *cyt b* gene are available for two species of subgenus *Haemamoeba* with readily distinguishable vacuoles in erythrocytic meronts, i.e. *P. matutinum* and *P. tejeraei*. Genetic difference in *cyt b* gene between them is large (4.1%), indicating that these species are valid. Both parasites clustered together in our phylogenetic analysis (Fig. 1), suggesting that the feature of vacuolization of erythrocytic meronts may be informative phylogenetically. Investigation of other *Plasmodium* species containing large vacuoles in erythrocytic meronts is needed to test this observation.

DISCUSSION

The key result of this study is the development of molecular markers to detect, identify and examine phylogenetic relationships of *P. matutinum*. Partial sequences of mitochondrial, apicoplast and nuclear genomes were identified. Currently, the *cyt b* gene sequences are particularly useful because they have been identified in many avian haemosporidian species and can be used in comparative parasitology research (Perkins, 2014; Bensch *et al.* 2016; Mantilla *et al.* 2016; Ricklefs *et al.* 2017). The obtained COI,

clpc and *AMA1* gene sequences extend information about molecular characterization of *P. matutinum*, providing opportunities to use these data in multi-gene analysis of phylogenetic status of malaria parasites (Martinsen *et al.* 2008). The available information about nuclear genome genes of avian malaria parasites remain scarce (Lauron *et al.* 2014), but is needed in research aiming studies of mechanisms of speciation and diversity maintenance in *Plasmodium* spp. and related haemosporidian parasites (Valkiūnas *et al.* 2013a, b). Additionally, information about *clpc* gene sequences is helpful in taxonomic research. For example, the genetic distance in *cyt b* gene between closely related lineages of *Haemoproteus jenniae* and *Haemoproteus iwa* is only 0.6% or 1 bp, but 18 nucleotide differences or 4% sequence divergence between these parasites was recorded in a segment of *clpc* gene, indicating existence of different parasite species and the validity of both species names (Levin *et al.* 2012).

The former microscopic studies showed that *P. matutinum* is present in the USA and Europe and probably is cosmopolitan in countries with warm climates (Garnham, 1966; Bennett *et al.* 1982; Valkiūnas, 2005). It was particularly often reported in thrushes (Turdidae) and columbiform birds by microscopic examination of blood samples. The recent molecular data support these conclusions and also add species of Muscicapidae to the list of relatively common hosts (Table 1). Available data indicate that birds of the Turdidae, Muscicapidae and Columbidae are often infected. Additionally, the endemic Great spotted kiwi (*Apteryx haastii*), Brown kiwi (*Apteryx mantelli*) and several other rare bird species (Table 1) are affected by this infection in New Zealand (Castro *et al.* 2011; Howe *et al.* 2012; Sijbranda, 2015; Sijbranda *et al.* 2016). It is noteworthy that reports of *P. matutinum* (pLINN1) in non-migrating birds and/or mosquitoes in USA, Italy, Spain, Japan and New Zealand certainly indicate the local transmissions and the global distribution. However, the range of competent avian host, in which this parasite completes life cycle and produces invasive stages (gametocytes), remains unclear because the presence of the gametocytes in the circulation of PCR-positive birds was reported only during this study (Table 1). It is difficult to rule out that some positive PCR-based diagnostic results might be due to the amplification of DNA from sporozoites, which might be unable to initiate development in birds, or due to templates, which may come from abortive development of tissue stages in non-competent avian hosts (Valkiūnas *et al.* 2014; Moens *et al.* 2016; Palinauskas *et al.* 2016; Valkiūnas and Iezhova, 2017). Further studies combining PCR-based and microscopic approaches are needed to determine the certain range of competent avian hosts of this malaria infection.

The close phylogenetic relationships between *P. matutinum* and *P. tejerai* (Fig. 1) likely indicate American origin of these infections because both the parasites are present in American birds, but *P. tejerai* is absent from European birds. In other words, *P. matutinum* might be of secondary origin in Europe. Interestingly, both these parasites are quite different in *cyt b* gene from other common species of subgenus *Haemamoeba*: *Plasmodium relictum*, *Plasmodium cathemerium*, *Plasmodium gallinaceum*, which appeared in the different clade (Fig. 1). For example, the genetic difference of *P. matutinum* (pLINN1) and *P. tejerai* (pSPMAG01) from the widespread lineages pSGS1, pGRW4, pGRW11 of *P. relictum* ranges between 5.7 and 6.1% and between 5.9 and 6.8%, respectively. That suggests possible independent evolution of *P. matutinum* (pLINN1) and *P. tejerai* (pSPMAG01) in regard to *P. relictum* and probably other *Haemamoeba* parasites.

It is interesting to mention that *P. matutinum* and *P. tejerai* possess large circular vacuoles in their growing erythrocytic meronts (Fig. 2G). That is not a case in *P. relictum*, *P. cathemerium* and *P. gallinaceum* (Garnham, 1966; Valkiūnas, 2005). Because *P. matutinum* and *P. tejerai* are closely phylogenetically related (Fig. 1), it might be that such vacuolization is a morphological character, which indicates evolutionary relationships between malaria parasites of subgenus *Haemamoeba*. Large vacuoles are also present in erythrocytic meronts of *P. giovannolai* and *P. griffithsi*. Molecular characterization of the latter two parasites is needed to test this assumption. It is worth mentioning that similar large vacuoles have been described in blood stages of several *Haemoproteus* parasites, which is a sister group to *Plasmodium* (Valkiūnas, 2005; Bensch *et al.* 2016), but the origin and metabolic function of such vacuoles in blood stages of haemosporidian parasites remains unclear. It is noteworthy that sporogonic stages of avian haemosporidian parasites, particularly often zygotes, ookinetes and early oocysts, contain cytoplasmic inclusions, which are the gatherings of amorphous dense material called a crystalloid material (Valkiūnas, 2005; Atkinson *et al.* 2008). The crystalloid material is washed out during fixation with alcohols and looks like an empty space, which is usually described as a 'vacuole' in stained preparations under a light microscope. The crystalloid likely performs energy functions and takes part in the metabolism of lipids (Desser and Bennett, 1993; Valkiūnas, 2005; Atkinson *et al.* 2008). Vacuoles in the cytoplasm of *P. matutinum* and *P. tejerai* are similar in appearance to the vacuoles reported in sporogonic stages of haemosporidians, and may be homologous to them. Histochemical and electron microscopy studies of growing erythrocytic meronts of *P. matutinum* and related parasites are needed to answer this question.

Former experimental studies showed that virulence of different *P. matutinum* strains varies markedly. Italian strain caused lethal malaria in avian hosts, but American strain was less virulent, with no mortality reported in experimentally exposed birds (Corradetti *et al.* 1960; Garnham, 1966; Valkiūnas, 2005). Field observations indicate that this infection is associated with diseases and even mortality in native and endemic birds in New Zealand (Castro *et al.* 2011; Howe *et al.* 2012; Sijbranda *et al.* 2016). This study shows that the lineage pLINN1 of *P. matutinum* was relatively benign in canaries during first 4 months after inoculation of infected blood. However, the sample size was limited only to two individual birds, and this observation should be treated with a caution. It is important to note that the genetically similar parasite has been recently found in dead blackbirds *Turdus merula* in Austria (Dinhopl *et al.* 2015), suggesting that some virulent lineages of *P. matutinum* might be present in Europe, as has been formerly reported by Corradetti *et al.* (1960) in Italy. Further studies of genetic diversity of *P. matutinum* are needed for better understanding the virulence of this infection and its role in natural bird populations.

Former studies showed that *P. matutinum* completed sporogony in *Culex pipiens*, *Culex tarsalis* and *Culex stigmatosoma* mosquitoes, but susceptibility of different isolates was markedly different in same mosquito species. For example, the American strain failed to develop or developed only in few individual *C. pipiens* mosquitoes, while the Italian strain readily developed and completed sporogony in this mosquito species (Corradetti *et al.* 1962; Garnham, 1966). Vectors of the lineage pLINN1 of *P. matutinum* remain unknown. PCR-based reports of this parasite in *C. pipiens* in the USA and Italy (Table 1) are in accordance with former experimental parasitology studies, suggesting possible involvement of this ornithophilic mosquito in transmission of *P. matutinum* (pLINN1). Detection of infective sporozoites in mosquitoes is needed to prove this observation.

ACKNOWLEDGEMENTS

This paper benefited from comments of two anonymous reviewers. We thank V. Jusys and V. Eigirdas (Ventės Ragas Ornithological Station, Lithuania) for support during field work.

FINANCIAL SUPPORT

This study was funded by the Research Council of Lithuania (no. MIP-045/2015).

REFERENCES

- Atkinson, C.T., Thomas, N.J. and Hunter, D.B. (2008). *Parasitic Diseases of Wild Birds*. Wiley-Blackwell, Oxford, UK.

- Bennett, G. F., Whiteway, M. and Woodworth-Lynas, C. (1982). A host-parasite catalogue of the avian haematozoa. *Memorial University of Newfoundland Occasional Papers in Biology* 5, 1–243.
- Bensch, S., Stjerner, M., Hasselquist, D., Östman, Ö., Hansson, B., Westerdahl, H. and Pinheiro, R. T. (2000). Host specificity in avian blood parasites: a study of *Plasmodium* and *Haemoproteus* mitochondrial DNA amplified from birds. *Proceedings of the Royal Society London B* 276, 1583–1589.
- Bensch, S., Hellgren, O. and Pérez-Tris, J. (2009). MalAvi: a public database of malaria parasites and related haemosporidians in avian hosts based on mitochondrial cytochrome *b* lineages. *Molecular Ecology Resources* 9, 1353–1358.
- Bensch, S., Canbäck, B., DeBarry, J. D., Johansson, T., Hellgren, O., Kissinger, J. C., Palinauskas, V., Videvall, E. and Valkiūnas, G. (2016). The genome of *Haemoproteus tartakovskyi* and its relationship to human malaria parasites. *Genome Biology and Evolution* 8, 1361–1373.
- Castro, I., Howe, L., Tompkins, D. M., Barracough, R. K. and Slaney, D. (2011). Presence and seasonal prevalence of *Plasmodium* spp. in a rare endemic New Zealand passerine (tieke or Saddleback, *Philesturnus carunculatus*). *Journal of Wildlife Diseases* 47, 860–867.
- Clark, N. J., Clegg, S. M., and Lima, M. R. (2014). A review of global diversity in avian haemosporidians (*Plasmodium* and *Haemoproteus*: Haemosporida): New insights from molecular data. *International Journal of Parasitology* 44, 329–338.
- Corradetti, A., Neri, I. and Scanga, M. (1960). Segnalazione in Italia di *Plasmodium praecox* var. *matutinum* in *Turdus iliacus*, e separazione di questo plasmodio da *Plasmodium praecox* come specie distinta: *Plasmodium matutinum* Huff, 1937. *Parassitologia* 2, 333–343.
- Corradetti, A., Morcos, W. M. and Neri, I. (1962). Sulle produzioni di forme endostiocitarie nei canarini infettati con il ceppo italiano di *Plasmodium matutinum* derivato da *Turdus iliacus*. *Parassitologia* 4, 105–108.
- Corradetti, A., Verolini, F. and Neri, I. (1963). *Plasmodium* (*Haemamoeba*) *giovannolai* n. sp. parassita di *Turdus merula*. *Parassitologia* 5, 11–18.
- Cosgrove, C. L., Wood, M. J., Day, K. P. and Sheldon, B. C. (2008). Seasonal variation in *Plasmodium* prevalence in a population of blue tits *Cyanistes caeruleus*. *Journal of Animal Ecology* 77, 540–548.
- Desser, S. S. and Bennett, G. F. (1993). The genera *Leucocytozoon*, *Haemoproteus* and *Hepatocystis*. In *Parasitic Protozoa* (ed. Kreier, J. P. and Baker, J. R.), pp. 273–307. Academic, New York, USA.
- Dimitrov, D., Iezhova, T. A., Zehindjiev, P., Bobeva, A., Ilieva, M., Kirilova, M., Bedev, K., Sjöholm, C. and Valkiūnas, G. (2016). Molecular characterisation of three avian haemoproteids (Haemosporida, Haemoproteidae), with the description of *Haemoproteus (Parahaemoproteus) palloris* n. sp. *Systematic Parasitology* 93, 431–449.
- Dinhopl, N., Nedorost, N., Mostegl, M. M., Weissenbacher-Lang, C. and Weissenböck, H. (2015). In situ hybridization and sequence analysis reveal an association of *Plasmodium* spp. with mortalities in wild passerine birds in Austria. *Parasitology Research* 114, 1455–1462.
- Donovan, T. A., Schrenzel, M., Tucker, T. A., Pessier, A. P. and Stalis, I. H. (2008). Hepatic hemorrhage, hemocoelom, and sudden death due to *Haemoproteus* infection in passerine birds: eleven cases. *Journal of Veterinary Diagnostic Investigation* 20, 304–313.
- Drovetski, S. V., Aghayan, S. A., Mata, V. A., Lopes, R. J., Mode, N. A., Harvey, J. A. and Voelker, G. (2014). Does the niche breadth or trade-off hypothesis explain the abundance–occupancy relationship in avian Haemosporidia? *Molecular Ecology* 23, 3322–3329.
- Even, J. G., Bensch, S., Blackburn, T. M., Bonneaud, C., Brown, R., Cassey, P., Clarke, R. H. and Pérez-Tris, J. (2012). Establishment of exotic parasites: the origins and characteristics of an avian malaria community in an isolated island avifauna. *Ecology Letters* 15, 1112–1119.
- Fast, K. M., Walstrom, V. W. and Outlaw, D. C. (2016). Haemosporidian prevalence and parasitemia in the Tufted titmouse (*Baeolophus bicolor*). *Journal of Parasitology* 102, 636–642.
- Ferraguti, M., Martínez-de la Puente, J., Ruiz, S., Soriguer, R. and Figuerola, J. (2013). On the study of the transmission networks of blood parasites from SW Spain: diversity of avian haemosporidians in the biting midge *Culicoides circumscriptus* and wild birds. *Parasites and Vectors* 6, 208.
- Gabaldon, A. and Ulloa, G. (1977). *Plasmodium* (*Haemamoeba*) *tejeraei* sp. n. del pavo doméstico (*Meleagris gallopavo*) de Venezuela. *Boletín de Malariología y Salud Ambiental* 17, 255–273.
- Gabaldon, A. and Ulloa, G. (1980). Holoendemicity of malaria: an avian model. *Transactions of the Royal Society of Tropical Medicine and Hygiene* 74, 501–507.
- Garnham, P. C. C. (1966). *Malaria parasites and other Haemosporidia*. Blackwell Scientific Publications, Oxford, UK.
- Hall, T. A. (1999) BioEdit: a user – friendly biological sequence alignment editor and analysis program for Windows 95/98/NT. *Nucleic Acid Symposium Series* 41, 95–98.
- Hellgren, O., Križanauskienė, A., Hasselquist, D. and Bensch, S. (2011). Low haemosporidian diversity and one key-host species in a bird malaria community on a mid-Atlantic island (São Miguel, Azores). *Journal of Wildlife Diseases* 47, 849–859.
- Hellgren, O., Waldenström, J. and Bensch, S. (2004). A new PCR assay for simultaneous studies of *Leucocytozoon*, *Plasmodium* and *Haemoproteus* from avian blood. *Journal of Parasitology* 90, 797–802.
- Hellgren, O., Waldenström, J., Pérez-Tris, J., Szöllösi, E., Hasselquist, D., Križanauskienė, A., Ottosson, U. and Bensch, S. (2007). Detecting shifts of transmission areas in avian blood parasites — a phylogenetic approach. *Molecular Ecology* 16, 1281–1290.
- Howe, L., Castro, I. C., Schoener, E. R., Hunter, S., Barracough, R. K. and Alley, M. R. (2012). Malaria parasites (*Plasmodium* spp.) infecting introduced, native and endemic New Zealand birds. *Parasitology Research* 110, 913–923.
- Iezhova, T. A., Valkiūnas, G. and Bairlein, F. (2005). Vertebrate host specificity of two avian malaria parasites of the subgenus *Noxyella*: *Plasmodium nucleophilum* and *Plasmodium vaughani*. *Journal of Parasitology* 91, 472–474.
- Ilgūnas, M., Bukauskaitė, D., Palinauskas, V., Iezhova, T. A., Dinhol, N., Nedorost, N., Weissenbacher-Lang, C., Weissenböck, H. and Valkiūnas, G. (2016). Mortality and pathology in birds due to *Plasmodium* (*Giovannolaia*) *homocircumflexum* infection, with emphasis on the exoerythrocytic development of avian malaria parasites. *Malaria Journal* 15, 256.
- Kimura, M., Darbro, J. M. and Harrington, L. C. (2010). Avian malaria parasites share congeneric mosquito vectors. *Journal of Parasitology* 96, 144–151.
- Lauren, E. J., Oakgrove, K. S., Tell, L. A., Biskar, K., Roy, S. W. and Sehgal, R. N. M. (2014). Transcriptome sequencing and analysis of *Plasmodium gallinaceum* reveals polymorphisms and selection on the apical membrane antigen-1. *Malaria Journal* 13, 382.
- Levin, I. I., Valkiūnas, G., Iezhova, T. A., O'Brien, S. L. and Parker, P. G. (2012). Novel *Haemoproteus* species (Haemosporida: Haemoproteidae) from the swallow-tailed gull (Lariidae), with remarks on the host range of hippoboscids-transmitted avian hemoproteids. *Journal of Parasitology* 98, 847–854.
- Mantilla, J. S., Gonzalez, A. D., Lotta, I. A., Moens, M., Pacheco, M. A., Escalante, A. A., Valkiūnas, G., Moncada, L. I., Pérez-Tris, J. and Matta, N. E. (2016). *Haemoproteus erythrogravidus* n. sp. (Haemosporida, Haemoproteidae): description and molecular characterization of a widespread blood parasite of birds in South America. *Acta Tropica* 159, 83–94.
- Martínez-de la Puente, J., Muñoz, J., Capelli, G., Montarsi, F., Soriguer, R., Arnoldi, D., Rizzoli, A. and Figuerola, J. (2015). Avian malaria parasites in the last supper: identifying encounters between parasites and the invasive Asian mosquito tiger and native mosquito species in Italy. *Malaria Journal* 14, 32.
- Martinsen, E. S., Perkins, S. L. and Schall, J. J. (2008). A three-genome phylogeny of malaria parasites (*Plasmodium* and closely related genera): evolution of life-history traits and host switches. *Molecular Phylogenetics and Evolution* 47, 261–273.
- Marzal, A. (2012). Recent advances in studies on avian malaria parasites. In: *Malaria Parasites* (ed. Okwa, O.), pp. 135–158. InTech Company, Rijeka, Croatia.
- Mata, V. A., da Silva, L. P., Lopes, R. J. and Drovetski, S. V. (2015). The Strait of Gibraltar poses an effective barrier to host-specialised but not to host-generalised lineages of avian Haemosporidia. *International Journal of Parasitology* 45, 711–719.
- Moens, M. A., Valkiūnas, G., Paca, A., Bonaccorso, E., Aguirre, N. and Pérez-Tris, J. (2016). Parasite specialization in a unique habitat: hummingbirds as reservoirs of generalist blood parasites of Andean birds. *Journal of Animal Ecology* 85, 1234–1245.
- Nilsson, E., Taubert, H., Hellgren, O., Huang, X., Palinauskas, V., Markovets, M. Y., Valkiūnas, G. and Bensch, S. (2016). Multiple cryptic species of sympatric generalists within the avian blood parasite *Haemoproteus majoris*. *Journal of Evolutionary Biology* 29, 1649–1878.
- Oakgrove, K. S., Harrigan, R. J., Loiseau, C., Guers, S., Seppi, B. and Sehgal, R. N. (2014). Distribution, diversity and drivers of blood-borne parasite co-infections in Alaskan bird populations. *International Journal of Parasitology* 44, 717–727.
- Outlaw, D. C. and Ricklefs, R. E. (2014). Species limits in avian malaria parasites (Haemosporida): how to move forward in the molecular era. *Parasitology* 141, 1223–1232.
- Palinauskas, V., Žiegytė, R., Ilgūnas, M., Iezhova, T. A., Bernotienė, R., Bolshakov, C. and Valkiūnas, G. (2015). Description of the first cryptic avian malaria parasite, *Plasmodium homocircumflexum* n. sp., with experimental data on its virulence and development in avian hosts and mosquitoes. *International Journal of Parasitology* 45, 51–62.

- Palinauskas, V., Žiegytė, R., Iezhova, T. A., Ilgūnas, M., Bernotienė, R. and Valkiūnas, G. (2016). Description, molecular characterisation, diagnostics and life cycle of *Plasmodium elongatum* (lineage pERIRUB01), the virulent avian malaria parasite. *International Journal of Parasitology* **46**, 697–707.
- Pérez-Tris, J. and Bensch, S. (2005). Diagnosing genetically diverse avian malarial infections using mixed-sequence analysis and TA-cloning. *Parasitology* **131**(Pt 1), 15–23.
- Perkins, S. L. (2014). Malaria's many mates: past, present and future of the systematics of the order Haemosporida. *Journal of Parasitology* **100**, 11–25.
- Ricklefs, R. E., Medeiros, M., Ellis, V. A., Svensson-Coelho, M., Blake, J. G., Loiselle, B. A., Soares, L., Fecchio, A., Outlaw, D., Marra, P. P., Latta, S. V., Valkiūnas, G., Hellgren, O., Bensch, S. (2017). Avian migration and the distribution of malaria parasites in New World passerine birds. *Journal of Biogeography* **44**, 1113–1123.
- Ronquist, F. and Huelsenbeck, J. P. (2003). MRBAYES 3: Bayesian phylogenetic inference under mixed models. *Bioinformatics* **19**, 1572–1574.
- Sambrook, J., Fritsch, E. F. and Maniatis, T. (1989). *Molecular Cloning: A Laboratory Manual*. Cold Spring Harbour Laboratory Press, New York, USA.
- Santiago-Alarcon, D., MacGregor-Fors, I., Kühnert, K., Segelbacher, G. and Schaefer, H. M. (2016). Avian haemosporidian parasites in an urban forest and their relationship to bird size and abundance. *Urban Ecosystems* **19**, 331.
- Sherman, I. W. (ed.) (1998). *Malaria: Parasite Biology, Pathogenesis, and Protection*. American Society for Microbiology, Washington, USA.
- Sijbrand, D. C. (2015) Host-parasite interactions between *Plasmodium* species and New Zealand birds: prevalence, parasite load and pathology. A thesis presented in partial fulfilment of the requirements for the degree of Master of Veterinary Science in Wildlife Health at Massey University, Palmerston North, New Zealand.
- Sijbrand, D. C., Campbell, J., Gartrell, B. D. and Howe, L. (2016). Avian malaria in introduced, native and endemic New Zealand bird species in a mixed ecosystem. *New Zealand Journal of Ecology* **40**, 72–79.
- Svoboda, A., Marthinsen, G., Pavel, V., Chutný, B., Turčoková, L., Lifjeld, J. T. and Johnsen, A. (2015). Blood parasite prevalence in the Bluethroat is associated with subspecies and breeding habitat. *Journal of Ornithology* **156**, 371–380.
- Szöllősi, E., Cichoń, M., Eens, M., Hasselquist, D., Kempenaers, B., Merino, S., Nilsson, J. Å., Rosvall, B., Rytönen, S., Török, J., Wood, M. J. and Garamszegi, L. Z. (2011). Determinants of distribution and prevalence of avian malaria in blue tit populations across Europe: separating host and parasite effects. *Journal of Evolutionary Biology* **24**, 2014–2024.
- Tamura, K., Stecher, G., Peterson, D., Filipski, A. and Kumar, S. (2013). MEGA6: molecular evolutionary genetics analysis version 6.0. *Molecular Biology and Evolution* **30**, 2725–2729.
- Valkiūnas, G. (2005). *Avian Malaria Parasites and Other Haemosporidia*. CRC Press, Boca Raton, FL, USA.
- Valkiūnas, G. and Iezhova, T. A. (2017). Exo-erythrocytic development of avian malaria and related haemosporidian parasites. *Malaria Journal* **16**, 101.
- Valkiūnas, G., Kazlauskienė, R., Bernotienė, R., Palinauskas, V. and Iezhova, T. A. (2013a). Abortive long-lasting sporogony of two *Haemoproteus* species (Haemosporida, Haemoproteidae) in the mosquito *Ochlerotatus cantans*, with perspectives on haemosporidian vector research. *Parasitology Research* **112**, 2159–2169.
- Valkiūnas, G., Palinauskas, V., Križanauskienė, A., Bernotienė, R., Kazlauskienė, R. and Iezhova, T. A. (2013b). Further observations on in vitro hybridization of haemosporidian parasites: patterns of ookinete development in *Haemoproteus* spp. *Journal of Parasitology* **99**, 124–136.
- Valkiūnas, G., Palinauskas, V., Ilgūnas, M., Bukauskaitė, D., Dimitrov, D., Bernotienė, R., Zehntindjev, P., Ilieva, M. and Iezhova, T. A. (2014). Molecular characterization of five widespread avian haemosporidian parasites (Haemosporida), with perspectives on the PCR-based detection of haemosporidians in wildlife. *Parasitology Research* **113**, 2251–2263.
- Valkiūnas, G., Ilgūnas, M., Bukauskaitė, D., Žiegytė, R., Bernotienė, R., Jusys, V., Eigirdas, V., Fragner, K., Weissenböck, H. and Iezhova, T. A. (2016). *Plasmodium delichon* n. sp.: description, molecular characterisation and remarks on the exoerythrocytic merogony, persistence, vectors and transmission. *Parasitology Research* **115**, 2625–2636.
- Vanstreels, R. E., da Silva-Filho, R. P., Kolesnikovas, C. K., Bhering, R. C., Ruoppolo, V., Epiphany, S., Amaku, M., Ferreira Junior, F. C., Braga, É. M. and Catão-Dias, J. L. (2015). Epidemiology and pathology of avian malaria in penguins undergoing rehabilitation in Brazil. *Veterinary Research* **46**, 30.
- Walker, D. and Garnham, P. C. (1972). Aberrant *Leucocytozoon* infection in parakeets. *Veterinary Record* **91**, 70–72.
- Wood, M. J., Cosgrove, C. L., Wilkin, T. A., Knowles, S. C. L., Day, K. P. and Sheldon, B. C. (2007). Within-population variation in prevalence and lineage distribution of avian malaria in blue tits, *Cyanistes caeruleus*. *Molecular Ecology* **16**, 3263–3273.