

43. Acute viral hepatitis

Kalyan Ram Bhamidimarri and Paul Martin

Acute viral hepatitis is a systemic infection with predominant hepatic involvement and remains a significant cause of morbidity and mortality in the United States despite the availability of effective vaccines against the two major causes of acute viral hepatitis, namely A and B. There are five major hepatotropic viruses (A, B, C, D, and E) that cause acute hepatitis with acute hepatic inflammation and necrosis. Acute viral hepatitis typically runs its course in 6 months or less, in contrast to chronic hepatitis, which persists for longer. However, with modern serologic and molecular diagnostic testing, the time course is less important in distinguishing acute from chronic viral hepatitis. The clinical illness produced by these viruses can range from asymptomatic or clinically inapparent to a fulminant and fatal acute infection. A major distinction between hepatitis A and hepatitis B, C, D, and E is that the former causes acute hepatitis only, in contrast to the latter four which cause acute and chronic hepatitis. Other viral infections, such as herpes simplex, Epstein–Barr virus (EBV), cytomegalovirus (CMV), and parvovirus B19, can present with prominent hepatic dysfunction, although they are usually multisystem disorders. Hepatitis G, human herpesviruses, adenovirus, coronavirus, and TT virus (TTV) have also been implicated in causing hepatic dysfunction, but their clinical significance remains dubious.

HEPATITIS A VIRUS

The hepatitis A virus (HAV) is an RNA virus, identified in 1973, transmitted via the fecal–oral route and is a common cause of acute viral hepatitis in North America. Community outbreaks due to contaminated water or food are well recognized. Inhabitants in low-socioeconomic areas, international travelers, intravenous drug users, and homosexual men are at particular risk of HAV infection. In the United States, the incidence has decreased remarkably since the introduction

(1995) of HAV vaccination and its administration to all children as part of the universal childhood vaccination policy since 2006. In underdeveloped countries, HAV infection typically occurs in childhood and is subclinical (age ≤ 6 years, 70% are asymptomatic), with most of the population infected before adulthood acquiring life-long immunity. HAV infection occurring in older children and adults is more likely to be symptomatic, with increased morbidity and even mortality (Figure 43.1).

The average incubation period of HAV infection is 28 days (range 15 to 50 days), with peak fecal viral shedding and infectivity occurring before the onset of clinical symptoms, which may include anorexia, fever, malaise, fatigue, nausea, vomiting, diarrhea, and right upper quadrant discomfort. In acute HAV infection, these symptoms tend to occur 1 to 2 weeks before the onset of jaundice. Replication of HAV occurs exclusively within the cytoplasm of the hepatocyte, where the virus causes a noncytopathic infection. Hepatocellular damage is due to the host's immune response as the infected hepatocytes are cleared and is clinically observed by marked reduction of HAV RNA. Acute liver failure is rare and occurs in about 0.5% of infected individuals, more frequently in adults than in children. The overall case-fatality rate of acute HAV is 0.3% to 0.6% but reaches 1.8% among adults >50 years. Prompt referral of acute liver failure cases to a transplant center should be performed at the earliest. Patients with chronic liver disease who contract HAV are at particular risk of hepatic decompensation, which has led to the recommendation that HAV-naïve patients with chronic liver disease should be vaccinated against HAV. Most infected individuals recover uneventfully although the illness can occasionally be bimodal or relapsing. Chronic infection with HAV does not occur but a protracted cholestatic phase may be present with persistent jaundice and pruritus before the eventual recovery.

Clinical Infectious Disease, Second Edition ed. David Schlossberg. Published by Cambridge University Press.
© Cambridge University Press 2015.

Extrahepatic manifestations of HAV include acute pancreatitis, acalculous cholecystitis, autoimmune hemolytic anemia, aplastic anemia, reactive arthritis, effusions, mononeuritis multiplex, and Guillain-Barré syndrome. HAV-related acute kidney injury has been reported in cases from Asia, possibly mediated by immune complexes or interstitial nephritis.

Routine diagnosis of acute HAV infection is made by detection of IgM anti-HAV antibody in serum (Table 43.1), which becomes detectable 5 to 10 days before the onset of symptoms and persists

for 3 to 12 months after infection. IgG anti-HAV antibody develops early in infection and persists indefinitely. The presence of IgG anti-HAV in the absence of IgM anti-HAV reflects immunity either from prior infection or from vaccination.

Therapy

Acute HAV infection is self-limited without chronic sequelae. About 85% of acute HAV cases have clinical and biochemical recovery within 3 months and nearly all have complete recovery by 6 months from the time of infection. Treatment is largely supportive and includes adequate nutrition, hydration, avoidance of hepatotoxic medications, steroids, and abstinence from alcohol (Table 43.2). Because acute HAV is more likely to lead to hepatocellular failure in adults, especially in those with underlying chronic liver disease, these patients require close follow-up until symptoms resolve.

Universal precautions to prevent transmission among close contacts, good personal hygienes and immunization are recommended. Passive prophylaxis with intramuscular polyclonal immunoglobulin before and after exposure is safe and efficacious. Pre-exposure prophylaxis with immunoglobulin should be reserved for nonimmune patients at risk for HAV who are allergic to HAV vaccine. Postexposure prophylaxis with immune globulin is recommended for the following high-risk groups in whom protective antibody titers should be generated quickly: (1) close household and sexual contacts of an index patient with documented acute HAV, (2) staff and patients of institutions for the developmentally disabled with outbreaks of HAV, (3) children and staff of day-care centers with an index case

Table 43.1 Diagnostic testing for viral hepatitis

| Type | Diagnostic tests | Comments |
|-------------------------|-------------------------|--|
| Hepatitis A virus (HAV) | IgM anti-HAV | Acute infection |
| | IgG anti-HAV | Resolved infection, immunity |
| Hepatitis B virus (HBV) | HBsAg | Indicates infection |
| | IgM anti-HBc | Acute infection |
| | HBeAg, HBV DNA | Indicates replication |
| | Anti-HBs | Indicates immunity |
| | IgG anti-HBc | Current or prior infection |
| Hepatitis C virus (HCV) | Anti-HCV | Indicates infection |
| | HCV RNA | Indicates infection/viremia |
| Hepatitis D virus (HDV) | IgM anti-HDV | IgM anti-HBc positive indicates coinfection |
| | Anti-HDV | IgG anti-HBc positive indicates superinfection |
| | | Indicates infection |
| | HDV RNA and HDV antigen | Research tools at present |
| Hepatitis E virus (HEV) | IgM anti-HEV | Acute infection |
| | IgG anti-HEV | Resolved infection |
| EBV | EBV IgM and PCR | Indicates infection |
| CMV | CMV IgM and PCR | Indicates infection |

Abbreviations: EBV = Epstein-Barr virus; CMV = cytomegalovirus.

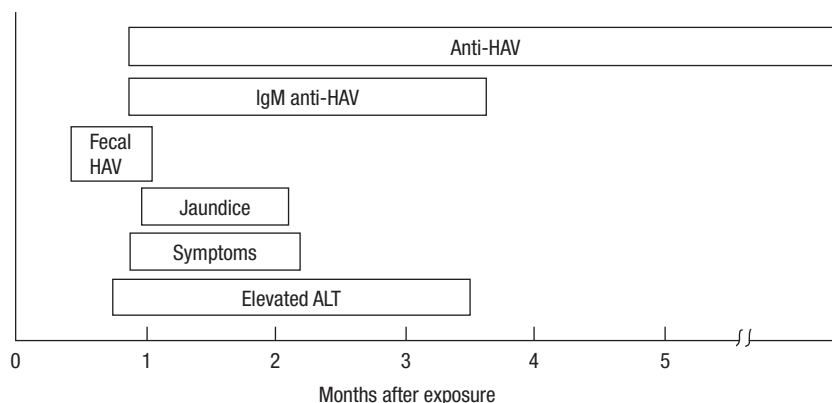


Figure 43.1 Course of acute hepatitis A. HAV = hepatitis A virus; ALT = alanine aminotransferase; anti-HAV = antibody to hepatitis A virus. (Adapted from Martin P, Friedman LS, Dienstag JL. Diagnostic approach to viral hepatitis. In: Thomas HC, Zuckerman AJ, eds. *Viral Hepatitis*. Edinburgh: Churchill Livingstone; 1993:393-409.)

Table 43.2 Therapy of acute viral hepatitis

| Type | Major focus | Comments |
|-------------|---|--|
| Hepatitis A | Symptomatic therapy | Recognition of ALF and promptly refer to transplant center |
| Hepatitis B | Symptomatic therapy. Oral agents for acute severe HBV | Observe for ALF |
| Hepatitis C | Pegylated interferon +/- ribavirin | Treatment efficacious in acute HCV |
| Hepatitis D | Consider anti-HBV agents in severe cases Prevention: HBV vaccine | Clinically more severe than HBV alone |
| Hepatitis E | Ribavirin monotherapy is effective | FHF common in pregnant women. Transmission can be enteric or zoonotic. Can become chronic in immunocompromised |
| EBV | Symptomatic therapy | Risk factor for PTLD |
| CMV | Immunocompetent: monitor Immunocompromised: ganciclovir, foscarnet, or cidofovir | |

Abbreviations: EBV = Epstein-Barr virus; CMV = cytomegalovirus; FHF = fulminant hepatic failure; PTLD = post-transplantation lymphoproliferative disease.

of HAV, (4) those exposed to protracted community outbreaks, and (5) travelers and military personnel who plan to visit countries endemic for HAV. Active immunization with an inactivated HAV vaccine has been available in the United States since 1995. Recent literature suggests that the efficacy and effectiveness of HAV vaccine is superior to passive immunization even for post-exposure prophylaxis.

HEPATITIS B VIRUS

Hepatitis B virus (HBV) is the most common cause of chronic viral hepatitis worldwide and is also a major cause of acute viral hepatitis, especially in developing nations. There are an estimated 400 million people chronically infected with HBV worldwide. In the Far East and sub-Saharan Africa, up to 20% of the population has serologic evidence of current or prior HBV infection. In the United States, although HBV infection is less frequent, the prevalence of chronic HBV is much higher in certain immigrant communities, including Asian Americans. After acute HBV

infection, the risk of chronic infection varies inversely with age. Thus, children younger than the age of 5 have a high risk of chronicity after acute HBV infection, whereas an immunocompetent adult has $\leq 5\%$ likelihood.

HBV is a DNA virus transmitted predominantly by a parenteral route or intimate contact with an infected subject. In Asia and other hyperendemic areas, vertical transmission is an important transmission route, whereas sexual and percutaneous transmission predominates in the Western world. The incubation period is 45 to 160 days. The typical course of a patient with acute HBV infection is illustrated in Figure 43.2. Typically, elevated alanine aminotransferase (ALT) levels and clinical symptoms appear earlier than jaundice. However, not all patients with acute HBV infection develop jaundice. About 70% of patients with acute HBV infection develop subclinical or anicteric hepatitis and only 30% develop icteric hepatitis. Paradoxically, the patient with anicteric and clinically less severe acute HBV infection is more likely to become chronically infected than the individual with more symptomatic acute infection because a brisk immune response causes more hepatic dysfunction but also a greater likelihood of ultimate clearance of HBV infection. The symptomatic patient should be reassured that full recovery is likely but should be warned to report back if symptoms such as deepening jaundice, severe nausea, or somnolence develop because these symptoms may herald acute hepatic failure. Acute liver failure occurs in approximately 0.1% to 0.5% of acute HBV cases. Like acute HAV, acute infection may be more severe in patients with underlying chronic liver disease.

The diagnosis of acute HBV hepatitis is made by detection of hepatitis B surface antigen (HBsAg) and IgM anti-hepatitis B core antibody (anti-HBc IgM) in the serum (Table 43.3). Resolution of HBV infection is characterized by loss of HBsAg. Development of the corresponding neutralizing antibody to HBsAg, anti-HBs, indicates resolution of infection. IgM anti-HBc declines and becomes undetectable whereas IgG ("total") anti-hepatitis B core antibody (anti-HBc IgG) persists after resolution of infection. Detection of IgG anti-HBc distinguishes immunity-acquired from prior infection rather than vaccination in a patient with detectable anti-HBs.

Individuals who are immunocompromised or have another chronic condition such as renal failure are more likely to develop chronic infection. Children younger than 5 years and the

elderly also have a greater likelihood of becoming chronically infected. The absence of a brisk immune response during acute HBV infection, implied by a relative absence of symptoms, with modest aminotransferase elevation in an anicteric patient, indicates that infection is more likely to become chronic. Chronic HBV infection is suggested by HBsAg positivity for longer than 6 months with absence of IgM anti-HBc. However, in severe reactivation of chronic HBV infection (spontaneous or iatrogenic due to administration of corticosteroids or chemotherapy to an infected patient), IgM anti-HBc may reappear in serum although usually in low titer. The presence of HBeAg and HBV DNA in the serum suggests ongoing active viral (wild type) replication or "high replicative state" in patients with chronic infection. The absence of these markers of active replication in a chronically infected patient with no clinical evidence of liver disease is referred to as the nonreplicative or inactive carrier state.

Table 43.3 Initial serologic workup of suspected acute hepatitis

| |
|--|
| IgM anti-HAV |
| HBsAg (if positive, then IgM anti-HBc, HBV DNA, HBeAg) |
| Anti-HCV antibody (if positive, then HCV RNA) |
| Consider testing for HEV, HSV, CMV and EBV if A, B, and C tests are negative. Testing for other viruses is at clinician's discretion |

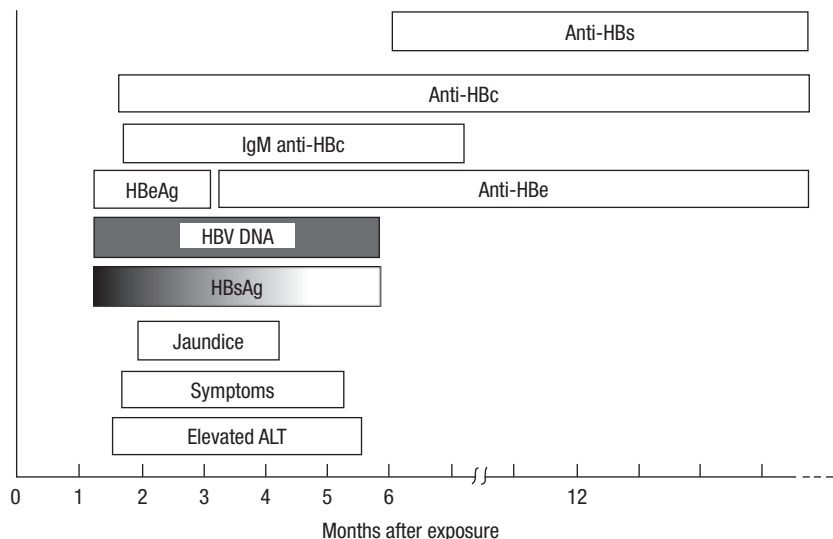


Figure 43.2 Typical course of acute hepatitis B. HBsAg = hepatitis B surface antigen; ALT = alanine aminotransferase; HBV DNA = hepatitis B virus DNA; HBeAg = hepatitis B e antigen; Anti-HBc = antibody to hepatitis B core antigen; Anti-HBe = antibody to hepatitis B e antigen; Anti-HBs = antibody to hepatitis B surface antigen. (Adapted from Martin P, Friedman LS, Dienstag JL. Diagnostic approach to viral hepatitis. In: Thomas HC, Zuckerman AJ, eds. *Viral Hepatitis*. Edinburgh: Churchill Livingstone; 1993:393–409.)

Therapy

Interferon- α , pegylated interferon- α 2a, lamivudine, adefovir dipivoxil, entecavir, telbivudine, and tenofovir are currently approved therapies in the United States for the treatment of chronic HBV infection. Interferon, entecavir, and tenofovir are the currently recommended first-line agents in the treatment of chronic HBV infection. Interferon's side effects have limited its use with the introduction of well-tolerated oral agents. Given the high rate of spontaneous resolution of acute HBV in otherwise healthy adults, antiviral therapy is generally not recommended. Treatment with oral agents should be initiated in acute severe cases of HBV or in those who are immunosuppressed. Early referral to a transplant center is highly recommended as some patients can progress to acute liver failure manifested by hepatic encephalopathy, worsening coagulopathy, or ascites. Post-transplant outcomes for HBV have been favorable. There has been a very low rate of recurrence of viral infection with current immunoprophylaxis regimens by using an oral antiviral agent with high-dose hepatitis B immunoglobulin (HBIG). However, indefinite HBIG therapy is both cumbersome and expensive. Accordingly, transplant programs are evaluating the use of alternative schedules of HBIG administration and combinations of antiviral agents to prevent allograft reinfection. Therapy for chronic HBV infection is discussed in Chapter 44, Chronic hepatitis.

The highly effective recombinant HBV vaccine is recommended for newborns, infants, adolescents, healthcare workers, hemodialysis patients, household contacts, and sexual partners of HBV-infected individuals, international travelers to endemic areas, injection drug users, men who have sex with men or heterosexuals with multiple sexual partners, patients with chronic liver disease, and those who are potential organ transplant recipients. Postexposure prophylaxis should consist of a combination of HBV vaccination and passive protection with HBIG.

HEPATITIS C VIRUS

The hepatitis C virus (HCV) is a single-stranded RNA virus. It is estimated that about 170 million people in the world are chronically infected with HCV. Acute HCV is typically subclinical, with fewer than 25% of patients developing jaundice, and thus acute illness usually escapes medical attention. If symptomatic, acute HCV is less likely to lead to chronicity. HCV infection is usually transmitted parenterally. In the past, this was often by contaminated blood products. Now, most HCV infection is contracted by sharing contaminated needles among intravenous drug abusers or by other percutaneous or high-risk practices such as tattooing or possibly intranasal cocaine use, although the latter is controversial. Sexual and maternal–neonatal transmission can occur but are generally less efficient routes of transmission although maternal human immunodeficiency virus (HIV) coinfection appears to increase the risk of perinatal transmission. Sexual transmission of HCV is also recognized in men who have sex with men. Acute HCV infection results in a high rate of chronicity, up to 85% in some series.

Figure 43.3 illustrates the course of a patient with acute HCV infection progressing to chronicity. The incubation period is 14 to 180 days, after which elevation of ALT levels occurs and symptoms may appear, although, as noted, the acute illness is frequently subclinical. Fulminant hepatic failure due to acute HCV infection is very rare but may be more common in patients with underlying chronic HBV infection.

Routine diagnosis is made by detection of antibodies in serum to HCV (anti-HCV) by enzyme-linked immunosorbent assay (ELISA) testing. The recombinant immunoblot assay (RIBA) test was formerly used to enhance specificity as a supplemental test in ELISA-positive individuals. However, it has generally been supplanted by polymerase chain reaction (PCR) testing to confirm viremia. Fluctuating ALT levels are characteristic of chronic HCV infection. Perhaps a fifth of chronically infected patients have ALT levels regarded as within the normal range, although this reflects a lack of sensitivity of aminotransferases in detecting lesser degrees of necroinflammatory activity in the liver rather than an absence of liver injury. PCR techniques vary in their sensitivity in detecting HCV RNA. The more sensitive transcription-mediated amplification (TMA) technique can detect even minute quantities of HCV RNA (0.9–5.2 copies/mL).

Therapy

Acute HCV infection is most typically recognized in a healthcare worker after a needle-stick injury or rarely in someone who develops a hepatitis flare. A small subset of patients, especially those with favorable IL28B genotype (C/C), can have

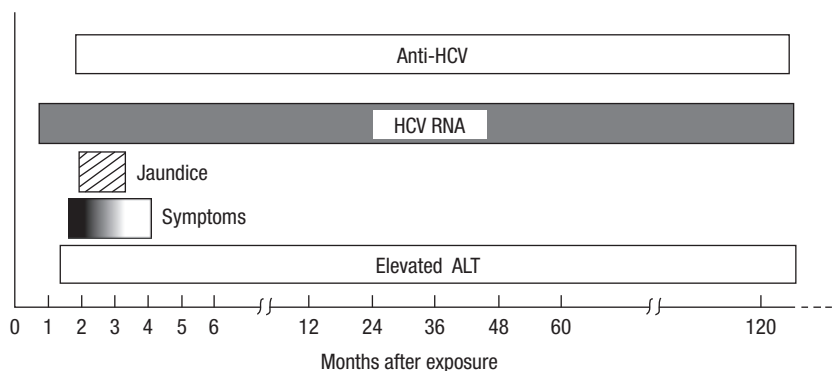


Figure 43.3 Typical course of acute hepatitis C progressing to chronic hepatitis C. HCV = hepatitis C virus; anti-HCV = antibody to the hepatitis C virus. (Adapted from Martin P, Friedman LS, Dienstag JL. Diagnostic approach to viral hepatitis. In: Thomas HC, Zuckerman AJ, eds. *Viral Hepatitis*. Edinburgh: Churchill Livingstone, 1993:393–409.)

spontaneous clearance of the virus. Therefore acute hepatitis C patients should be closely monitored and those with persistent viremia beyond 12 weeks should be offered treatment. It is important to note that treatment of HCV during the acute phase is highly effective and results in a sustained virologic response in up to 85% of treated patients. Although ribavirin is usually not required in the treatment of acute HCV, it should be added in patients who do not respond to 3 months of interferon monotherapy. It has been reported that delaying antiviral therapy for 2 to 4 months after acute HCV infection does not compromise efficacy. This delay allows spontaneous resolution of HCV without embarking on unnecessary treatment with interferon. Therapy of chronic HCV infection is discussed in more detail in Chapter 44, Chronic hepatitis.

An HCV vaccine is not yet available because of the virus' heterogeneity and the lack of seroprotective capability of HCV antibodies, and until recently, lack of a cell culture system. There is no benefit from gamma globulin administration following a needle-stick exposure to HCV. In the healthcare setting, universal precautions are mandatory because the risk of HCV transmission to healthcare workers is substantial, averaging about 3% particularly with hollow-bore needles. Routine screening by blood banks for HCV has reduced the risk of transmission by transfusion to a negligible level. Following liver transplant, HCV reinfection of the transplanted liver occurs in almost all the patients, with a subset of patients developing early severe recurrence of viral infection.

HEPATITIS D VIRUS

The hepatitis delta virus (HDV) is an incomplete RNA virus and depends on HBsAg to complete its replicative cycle. It is estimated that 5% of chronic HBV patients in the world are coinfecting with HDV. HDV is transmitted parenterally in the developed countries, whereas in other areas of high endemicity (Mediterranean basin), the transmission is through close contact. Immigration from highly endemic areas is implicated in the recent increase in prevalence in Western Europe. HDV may be transmitted simultaneously with HBV (coinfection) or acquired in chronic HBV carriers (superinfection). Most cases of coinfection are self-limited but patients are more likely to develop fulminant hepatitis than with HBV monoinfection. If HDV is acquired by superinfection, the infection tends to become chronic with higher rates of progression to cirrhosis than

with HBV alone. HBV viral load is typically suppressed by active HDV infection.

The diagnosis of HDV coinfection is made if serum IgM anti-HDV, HBsAg, and IgM anti-HBc are simultaneously present in serum. HDV superinfection is denoted by IgM anti-HDV, HBsAg, and IgG anti-HBc with absent IgM anti-HBc. During the acute infection, HDV serologies are often insensitive and repeat testing may be required in cases with high clinical suspicion (see Table 43.1). HDAg (direct immunofluorescence) or HDV RNA (reverse transcriptase assay) testing in the serum or on liver tissue can be performed but these techniques are not widely available for clinical use.

Therapy

There is no specific treatment for acute HDV infection as most patients have spontaneous resolution after the flare. Interferon is the only effective therapy against HDV but it is contraindicated during an acute flare as it can exacerbate the ALT flare, leading to acute hepatic failure. Antiviral agents against hepatitis B are generally not useful as HBV is usually suppressed but can be tried in patients who are developing fulminant liver failure. Liver transplantation is the only option for patients with acute liver failure from HDV coinfection. Liver transplant outcomes are better in patients with HDV than in those transplanted for HCV. Control of HBV with antiviral agents plus or minus HBIG prevents HDV recurrence in the graft. Vaccination against HBV prevents HDV infection.

HEPATITIS E VIRUS

The hepatitis E virus (HEV) is an RNA virus first identified in 1980 as an enterically transmitted hepatitis virus similar to HAV. Currently, there are four genotypes identified of which genotypes 1 and 2 are predominant in developing countries and have enteric transmission, whereas genotypes 3 and 4 are predominant in developed countries and have zoonotic transmission (consumption of contaminated uncooked meat, especially pork). The incubation period is 15 to 60 days with high infection rates in adults between the ages of 15 and 40. Antibodies against HEV have been found in up to 20% of the general population in developed countries and may account for 3% of cases of putative drug-induced liver injury presenting with acute liver failure.

HEV infection is usually acute and self-limited but chronic HEV progressing to cirrhosis has

been increasingly recognized especially in genotype 3 and immunocompromised subjects. A unique feature of this disease in developing nations is that fulminant hepatic failure occurs more frequently in pregnant women during the third trimester and carries a high mortality rate (15%–25%). HEV is diagnosed by IgM and IgG anti-HEV antibodies, and HEV RNA by PCR.

Therapy

Acute HEV infection is self-limited and treatment is mainly supportive. Pregnant women should not travel to endemic areas. There are no standard guidelines to treat HEV infection. Acute severe hepatitis can be treated with ribavirin monotherapy (dose 600 mg to 1000 mg/day) for 3 to 6 months, which can result in rapid clinical improvement. Ribavirin is teratogenic. Interferon is contraindicated in severe hepatitis as it can exacerbate the ALT flare, leading to fulminant hepatic failure. Chronic HEV in immunosuppressed transplant recipients can be treated with either lowering of immunosuppression, ribavirin monotherapy or pegylated interferon monotherapy or a combination of the above. Treatment decisions are usually individualized based on the patient's condition and assessment of therapeutic risks, especially in the post-transplant setting. HEV vaccines are currently in the developmental phases with promising preliminary results.

HERPES SIMPLEX VIRUS

Herpes simplex virus (HSV) is a capsulated double-stranded DNA virus and its infection can rarely lead to acute liver failure (1%–2% of all acute liver failure cases). Acute severe hepatitis is associated with high mortality rates of 75% to 90% and is commonly seen in immunocompromised patients, pregnant women (late trimester), neonates, and rarely in immunocompetent individuals.

Clinical features of HSV can vary from mild asymptomatic anicteric hepatitis to fulminant hepatic failure or severe HSV sepsis (pneumonitis, esophagitis, encephalitis) resulting in multi-organ failure. New-borns presenting with systemic infection called herpes neonatorum have high rates of brain injury and 25% mortality rate. Mucocutaneous lesions are found only in 50% of the cases and their absence often results in diagnostic delay. Most cases of acute HSV hepatitis occur as a result of acute infection rather than viral reactivation and fever, flu-like

symptoms, and leukopenia can be present. Serologies are usually nondiagnostic and thus diagnosis rests on detection of viremia by HSV PCR and/or liver biopsy. Presence of viral Cowdry type A nuclear inclusion bodies, HSV immunohistochemical stains, HSV PCR, and electron microscopy on the liver biopsy aid in confirming the diagnosis.

Early treatment with high-dose acyclovir (10 mg/kg intravenous thrice daily) is highly effective. Delay in treatment can result in lowered efficacy and thus empiric treatment is recommended in cases with typical features of HSV hepatitis. Foscarnet can be used if there is concern with acyclovir resistance. Patients with fulminant liver failure should be carefully evaluated for liver transplantation as the 1 year post-transplant survival rate is around 43%, usually due to disseminated and uncontrolled HSV infection. Indefinite antiviral therapy is usually required to prevent recurrence following spontaneous resolution or transplant.

EPSTEIN–BARR VIRUS

EBV is the causative agent for infectious mononucleosis and causes asymptomatic liver enzyme and lactate dehydrogenase elevations up to three times the upper limits of normal in 80% to 90% of cases. Clinical manifestations include fever, pharyngitis, lymphadenopathy, abdominal pain, hepatosplenomegaly, and, rarely, jaundice. The serum aminotransferases typically rise over 1 to 2 weeks, and in most patients the disease is self-limited with resolution of symptoms and normalization of enzymes over the subsequent 4 to 6 weeks. Severe hepatitis and fulminant hepatic failure are rare but have been reported.

Leukocytosis (predominance of lymphocytes and monocytes) and mild thrombocytopenia is common. EBV IgM antibodies peak early and can persist for months, after which EBV IgG develops. Although the Monospot is sensitive in detecting heterophile antibodies, it is not specific for EBV infection. EBV DNA quantification can be accomplished through PCR assays on blood or plasma. Liver biopsy is not usually indicated although *in situ* hybridization or PCR of the biopsy sample may be used to confirm the diagnosis. Treatment is largely supportive as no specific treatment exists. Acyclovir has been used without effect on symptoms or outcome. EBV may rarely cause chronic infection in immunocompetent patients. EBV infection is an important factor in the development of post-transplantation

lymphoproliferative disease (PTLD) in transplant recipients.

CYTOMEGALOVIRUS

CMV infection frequently involves the liver, most commonly as an asymptomatic elevation of serum transaminases. It can be a result of a primary infection or reactivation of a latent infection in an immunocompromised host. In immunocompetent children and adults, primary CMV infection is usually subclinical but may cause an illness that can mimic mononucleosis. The clinical course is typically mild and self-limited, but CMV has been implicated in hepatic granulomata, cholestatic hepatitis (mimicking primary sclerosing cholangitis), and even rare cases of fatal hepatic necrosis. CMV can be severe and even life-threatening in patients with impaired cellular immunity, due to disseminated infection.

Antibody testing is of low utility in immunocompromised patients and therefore CMV PCR is the most reliable and specific diagnostic test. Liver biopsy may be indicated and confirmatory in an immunocompromised patient or a transplant recipient when the characteristic multinucleated giant cells and owl eye inclusions are identified. No definite therapy is required in immunocompetent patients with mild CMV infection. In immunocompromised patients, effective therapies include ganciclovir or alternatively foscarnet or cidofovir in ganciclovir failure. Therapy should be continued until patients become aviremic and preferably maintained during the intense immunosuppressive period.

PARVOVIRUS B19

Human parvovirus B19 is a small nonenveloped single-stranded DNA virus which is a rare (probably underdiagnosed) cause of acute hepatitis and liver failure in immunocompetent individuals. It is a common infection of childhood called erythema infectiosum or fifth disease and up to 50% of adolescents develop parvovirus antibodies by age 15. The virus is transmitted via respiratory droplets, blood products, and solid organ transplantation. Adults can present with acute upper respiratory viral syndrome, arthropathy, and varying severity of bone marrow suppression and liver injury. Rare hematologic manifestations include pure red cell aplasia, pancytopenia, and hematopoietic failure which are thought to be due to viral interaction with P-antigen. Although most case reports showed a

lesser degree of elevation of transaminases (<2000), levels of ALT greater than 9000 have also been reported. The pathogenic mechanisms involved in liver injury are unclear but may be due to caspase-mediated apoptosis from direct viral invasion. Diagnostic workup includes serum parvovirus B19 IgM, IgG, DNA, and liver biopsy. Bone marrow biopsy can show characteristic red cell aplasia and giant pronormoblasts. There are no standard treatment guidelines but there are several case reports reporting the use of supportive treatment, intravenous immunoglobulin (IVIG), tacrolimus, cyclosporine, mycophenolate mofetil, azathioprine, steroids and plasmapheresis with varying outcomes. Patients with fulminant hepatic failure require liver transplantation although there are limited data on the outcomes and hematopoietic recovery post-transplant. Recurrence of pure red cell aplasia after transplantation is approximately 10% and prolonged courses of IVIG appear to be beneficial.

MISCELLANEOUS VIRUSES

Non-hepatotropic viruses such as hepatitis G (HGV), TTV, human herpesvirus (HHV-6, HHV-8), varicella zoster virus (VZV), adenovirus, and coronavirus can all cause acute hepatic inflammation resulting in mild to modest increase in transaminases. HGV, also known as GBV-C, is a single-stranded RNA virus which is mainly transmitted parenterally and has some genomic similarity to HCV. HGV is lymphotropic but not hepatotropic and thus some authors debate its nomenclature as a hepatitis virus. HGV coinfection in HIV-positive patients is associated with favorable outcomes, including lower levels of HIV viremia, higher CD4 count, better response to antiretroviral therapy, lower transmission rates, and 2.5 fold reduction in mortality compared to those who are not coinfecting with HGV. TTV is a single-stranded DNA virus first isolated in 1997 as a cause of post-transfusion hepatitis but current data suggest that TTV does not play a significant role in the genesis of acute or chronic liver disease. HHV-6 is associated with hepatic artery thrombosis, encephalitis, and sepsis and HHV-8 is associated with development of Kaposi's sarcoma especially in immunocompromised transplant recipients. Similar to HGV and TTV, other viruses such as Sanban, Yonban, and SEN viruses do not cause clinical hepatitis and their role in human pathogenesis is controversial.

SUGGESTED READING

- Bhamidimarri KR, Park J, Dieterich D. Management of hepatitis B virus coinfection: HIV, hepatitis C virus, hepatitis D virus. *Curr Hepatitis Rep.* 2011;10(4):262–268.
- Bhattarai N, Stapleton JT. GB virus C: the good boy virus? *Trends Microbiol.* 2012;20(3):124–130.
- Deterding K, Grüner N, Buggish P, *et al.* Delayed versus immediate treatment for patients with acute hepatitis C: a randomised controlled non-inferiority trial. *Lancet Infect Dis.* 2013;13(6):497–506.
- Hajarizadeh B, Grebely J, Dore GJ. Epidemiology and natural history of HCV infection. *Nat Rev Gastroenterol Hepatol.* 2013;10(9):553–562.
- Jeong SH, Lee HS. Hepatitis A: clinical manifestations and management. *Intervirology.* 2010;53(1):15–19.
- Jindal A, Kumar M, Sarin SK. Management of acute hepatitis B and reactivation of hepatitis B. *Liver Int.* 2013;33(Suppl 1):164–175.
- Jung YM, Park SJ, Kim JS, *et al.* Atypical manifestations of hepatitis A infection: a prospective, multicenter study in Korea. *J Med Virol.* 2010;82(8):1318–1326.
- Norvell JP, Blei AT, Jovanovic BD, Levitsky J. Herpes simplex virus hepatitis: an analysis of the published literature and institutional cases. *Liver Transpl.* 2007;13(10):1428–1434.
- Smedile A, Rizzetto M. HDV: thirty years later. *Dig Liver Dis.* 2011;43(Suppl 1):S15–S18.
- Young NS, Brown KE. Parvovirus B19. *N Engl J Med.* 2004;350(6):586–597.