

# Interhemispheric functional disconnection because of abnormal corpus callosum integrity in bipolar disorder type II

Fumihiko Yasuno, Takashi Kudo, Kiwamu Matsuoka, Akihide Yamamoto, Masato Takahashi, Jyoji Nakagawara, Kazuyuki Nagatsuka, Hidehiro Iida and Toshifumi Kishimoto

## Background

A significantly lower fractional anisotropy (FA) value has been shown in anterior parts of the corpus callosum in patients with bipolar disorder.

## Aims

We investigated the association between abnormal corpus callosum integrity and interhemispheric functional connectivity (IFC) in patients with bipolar disorder.

## Methods

We examined the association between FA values in the corpus callosum (CC-FA) and the IFC between homotopic regions in the anterior cortical structures of bipolar disorder ( $n=16$ ) and major depressive disorder ( $n=22$ ) patients with depressed or euthymic states.

## Results

We found a positive correlation between the CC-FA and IFC values between homotopic regions of the ventral prefrontal

cortex and insula cortex, and significantly lower IFC between these regions in bipolar disorder patients.

## Conclusions

The abnormal corpus callosum integrity in bipolar disorder patients is relevant to the IFC between homotopic regions, possibly disturbing the exchange of emotional information between the cerebral hemispheres resulting in emotional dysregulation.

## Declaration of interest

None.

## Copyright and usage

© The Royal College of Psychiatrists 2016. This is an open access article distributed under the terms of the Creative Commons Non-Commercial, No Derivatives (CC BY-NC-ND) license.

Structural magnetic resonance imaging (MRI) studies have found changes in the area, shape, and fractional anisotropy (FA) in the corpus callosum in bipolar disorder.<sup>1–6</sup> Our previous study revealed significantly lower FA values in the anterior part of the corpus callosum in patients with bipolar disorder compared with patients with major depressive disorder (MDD) and healthy individuals, independent of the patients' affective state. FA value in the frontal corpus callosum was shown to be a prospective stable biological marker for differential diagnosis between bipolar disorder and MDD.<sup>7</sup> These findings indicated a need for more detailed investigation of the ways the pathophysiological processes of bipolar disorder in the corpus callosum might differ from MDD. The corpus callosum, the largest white matter structure connecting the left and right cerebral hemispheres, plays a critical role in interhemispheric communication, particularly in the integration of emotional, cognitive, motor, and sensory information. Abnormalities in the corpus callosum may induce interhemispheric connectivity abnormalities. However, few multimodal imaging studies have examined the effect of structural abnormality of the corpus callosum on the interhemispheric functional connectivity (IFC) in patients with bipolar disorder. We hypothesised that, in bipolar disorder, the resting-state functional connectivity between geometrically corresponding interhemispheric (i.e. homotopic) regions in the anterior part of the cerebral cortical structures would be altered by abnormalities in the frontal corpus callosum. To test this hypothesis, we performed region of interest (ROI) seed-based functional connectivity analyses between ROIs in one hemisphere and their mirrored counterparts in the opposite hemisphere in patients with bipolar disorder and MDD by resting-state functional MRI (rsfMRI). We then examined the association of IFC and FA values derived from magnetic resonance-diffusion tensor imaging (MRI-DTI) of the anterior part of the corpus callosum. In homotopic regions where there was significant association between IFC and fractional anisotropy

in the corpus callosum (CC-FA), we compared IFC between two groups of patients with bipolar disorder and MDD.

## Method

### Participants

Patients with bipolar disorder and MDD were recruited from outpatients treated in the Psychiatry Department of Hospital of National Cerebral and Cardiovascular Center, Nara Medical University, and Osaka University, Japan. The study was conducted between August 2011 and July 2015. Patients with bipolar disorder ( $n=16$ , 6 women/10 men, mean age (s.d.) = 47.1 (8.6) years) and patients with MDD ( $n=23$ , 14 women/9 men, mean age (s.d.) = 44.3 (9.8) years) participating in this study fulfilled the following inclusion criteria: (1) diagnosis of bipolar disorder or MDD based on the structured clinical interview for DSM-IV axis I disorders (SCID); (2) a euthymic or depressive state, but not a manic state (Young Mania Rating Scale (YMRS) <12) on the day of the MRI scan; and (3) age between 20 and 65 years. Exclusion criteria were DSM-IV diagnoses of misuse of or dependence on illicit substances and alcohol, history of organic mental disorder, head trauma, loss of consciousness, seizure disorder, or central nervous system disease. All patients with bipolar disorder met the DSM-IV criteria for bipolar II disorder according to the diagnostic assessment by the SCID.

MRI examinations were conducted once for all patients. Diffusion-weighted MR images and T1- and T2-weighted images were acquired from all individuals. Resting-state fMRI could not be acquired from one patient with bipolar disorder because of complaints of fatigue. Differences in FA of the frontal corpus callosum in the same group of individuals have previously been reported.<sup>7</sup> All patients were subjected to a series of standardised, quantitative measurements of manic symptoms (YMRS) and depressive symptoms (Montgomery–Asberg Depression Rating

Scale (MADRS) score) on the day of the MRI scan. This study was approved by the Institutional Review Boards of all participating institutions, and all participants gave written informed consent before enrolment.

### Data acquisition of MRI

The MRI examination procedures have been described in detail previously.<sup>7,8</sup> All MRI examinations were performed with a 3T whole-body scanner (Signa Excite HD V12M4; GE Healthcare, Milwaukee, WI, USA) with an 8-channel phased-array brain coil. High-resolution three-dimensional T1- and T2-weighted images were acquired. Diffusion-weighted MR images were obtained with a locally modified single-shot echo-planar imaging (EPI) sequence by parallel acquisition at a reduction (ASSET) factor of 2, in the axial plane. Motion probing gradient (MPG) was applied in 55 directions. To reduce blurring and signal loss arising from field inhomogeneity, an automated high-order shimming method based on spiral acquisitions was used before acquiring the DTI scans. To correct for motion and distortion from eddy currents and B0 inhomogeneity, we utilised the FMRIB software (FMRIB Center, Department of Clinical Neurology, University of Oxford, Oxford, England; <http://www.fmrib.ox.ac.uk/fsl/>). B0 field mapping data were also acquired with the echo time shift (of 2.237 ms) method based on two gradient echo sequences.

The resting-state fMRI scan images were obtained by capturing 37 transverse slices of 4 mm thickness covering the entire brain with a temporal resolution of 3 s, using a T2\*-weighted gradient echo EPI pulse sequence (TR=3000 ms, TE=35 ms, flip angle 85°, time frames 88, number of images 3256; acquisition time 4 min 24 s.). For resting-state image acquisition, participants were instructed to remain still with their eyes closed and let their minds wander freely. To reduce blurring and signal loss arising from field inhomogeneity, an automated high-order shimming method based on spiral acquisitions was used before performing DTI and functional MRI scans. FMRIB software was again utilised to correct for motion and distortion derived from the eddy current and B0 inhomogeneity.

### DTI data processing and statistical analysis

DTI data processing, statistical analysis, and results have previously been described in detail.<sup>7</sup> FA maps were generated from each individual by FMRIB software.<sup>9</sup> Exploratory voxel-based analysis was performed by SPM8 software. The difference in FA values between patients with bipolar disorder and MDD was examined by analysis of covariance (ANCOVA) with age, gender, MADRS scores, and duration of illness as covariates, considering the effects of these factors on the white matter microstructure in patients with bipolar disorder or MDD as reported previously.<sup>10–12</sup> Spherical volumes of interest (VOIs; 5 mm radius) were determined from the Montreal Neurological Institute (MNI) coordinate with peak *t*-value in the corpus callosum. The regional FA values were calculated by averaging the values for all voxels within the spherical VOIs placed on regions in FA images of patients with bipolar disorder and MDD.

### Resting-state fMRI data processing and statistical analysis

Standard image pre-processing methods were conducted employing the SPM12 software (<http://www.fil.ion.ucl.ac.uk/spm/>) with the CONN toolbox (<http://www.nitrc.org/projects/conn>) for functional connectivity analysis. The functional images were corrected for slice time and motion, co-registered with a high-resolution anatomical scan, normalised into the MNI space, resampled at 2 mm<sup>3</sup> and smoothed with a Gaussian kernel of 8 mm<sup>3</sup> FWHM. In addition,

the Artifact Detection Tools (ART: [http://www.nitrc.org/projects/artifact\\_detect](http://www.nitrc.org/projects/artifact_detect)) were used to measure motion artefacts in all individuals in both groups; we controlled for any motion artefacts by realignment parameters detected with ART.

### Seed region definition

We hypothesised that the resting-state functional connectivity between geometrically corresponding interhemispheric (i.e. homotopic) regions in the anterior part of the cerebral cortical structures would be altered by abnormalities of the frontal corpus callosum in bipolar disorder. To test this hypothesis, we performed ROI seed-based functional connectivity analyses between an ROI in one hemisphere and its mirrored counterpart in the opposite hemisphere in patients with bipolar disorder and MDD.

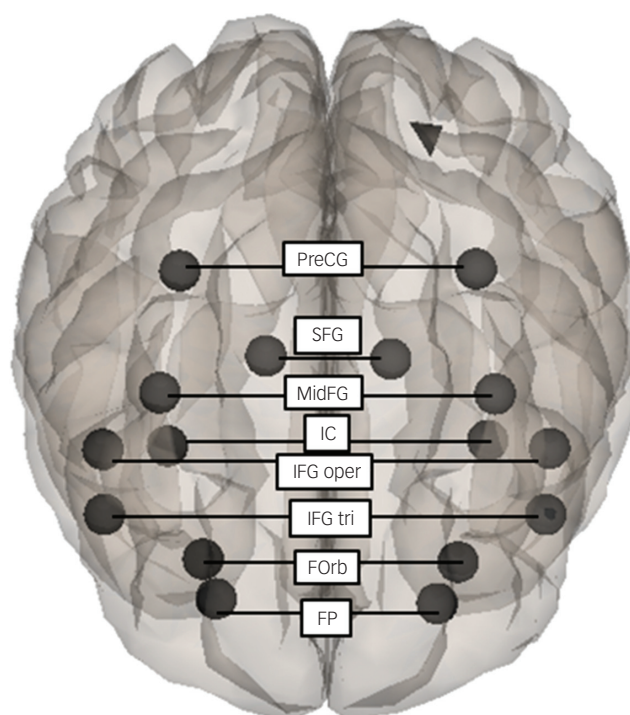
A series of ROIs were defined in the homotopic regions in the anterior part of the cerebral cortical structures including the frontal areas with the caudal limit of the central sulcus and insular cortex (IC) (Fig. 1). A mask for the following distinct subdomains of these regions was provided by the CONN toolbox: frontal pole (FP; MNI coordinates (*x*, *y*, *z*) for the areas, right and left: 26, 52, 8 and -25, 53, 8); insular cortex (IC: 37, 3, 0, and -36, 1, 0); superior frontal gyrus (SFG: 15, 18, 57, and -14, 19, 56); middle frontal gyrus (MidFG: 39, 19, 43 and -38, 18, 42); inferior frontal gyrus, pars triangularis (IFG tri: 52, 28, 8 and -50, 28, 9); inferior frontal gyrus, pars opercularis (IFG oper: 52, 15, 16 and -51, 15, 15); precentral gyrus (PreCG: 35, -11, 50 and -34, -12, 49); and frontal orbital cortex (FORb: 29, 23, -16 and -30, 24, -17).

### Functional connectivity analysis

Following the pre-processing steps outlined above, functional images were imported into the CONN toolbox in SPM12 for further data correction. The blood oxygenated level-dependent (BOLD) signal data were passed through a band pass filter (0.009–0.08 Hz). The mean BOLD signal time course was then extracted from each of the predefined ROIs. The time course for each ROI was then correlated with the time course for each of the other ROIs, allowing for the calculation of a correlation coefficient for each ROI by Pearson's product-moment calculation. We performed ROI-to-ROI seed-based functional connectivity analyses between the homotopic areas in order to examine the association of the FA values of the frontal corpus callosum and the IFC between the homotopic regions in the anterior part of the cerebral cortical regions in patients with bipolar disorder and MDD.

### Statistical analysis

Group differences in demographic characteristics between patients with bipolar disorder and MDD were examined by unpaired *t*-tests and Pearson's  $\chi^2$ -tests. We performed partial correlation analyses to examine the relationship between the FA values in the anterior part of the corpus callosum and the IFC in the homotopic regions with age, gender, MADRS scores, and duration of illness as covariates. In regions where there was a significant correlation between IFC values and the FA in the frontal corpus callosum, the group differences of mean IFC values of these regions were compared between bipolar disorder and MDD by ANCOVA using age, gender, and years of education as covariates. All statistical tests were two-tailed and reported at  $\alpha < 0.05$ . Statistical analysis of the data was performed by SPSS for Windows 22.0 (IBM Japan Inc., Tokyo, Japan).



**Fig. 1** A series of ROIs defined on the homotopic regions in the anterior part of the cerebral cortical structures. ROI-to-ROI seed-based functional connectivity analysis was performed between the homotopic regions: frontal pole (FP); frontal orbital cortex (FORb); inferior frontal gyrus, pars triangularis (IFG tri); inferior frontal gyrus, pars opercularis (IFG oper); insular cortex (IC); middle frontal gyrus (MidFG); superior frontal gyrus (SFG); precentral gyrus (PreCG).

## Results

### Demographic and clinical data

Table 1 summarises the demographic characteristics of the participants in the study. There were no significant differences in age, gender, or years of education between groups. Patients with bipolar disorder and MDD showed no significant differences in the age at onset or psychiatric scores on YMRS. Patients with bipolar disorder tended to have a longer duration of illness, and based on the MADRS score, patients with MDD tended to be

more depressed than those with bipolar disorder, although these differences were not significant. All patients with bipolar disorder were on lithium and/or other mood stabilisers during the study, whereas only three individuals with MDD were medicated with these drugs. There was no significant difference in medication with antidepressants, antipsychotics, and benzodiazepine drugs between the bipolar disorder and MDD groups.

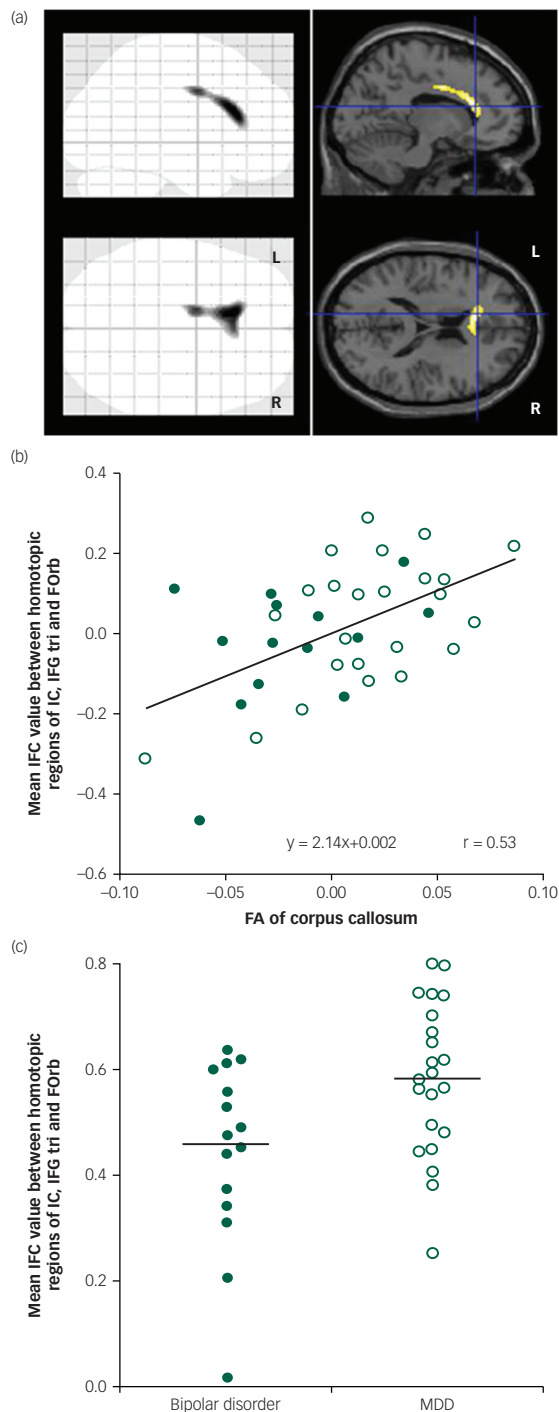
### FA changes and its correlation with IFC

As shown in the previous study, the results revealed significantly lower FA values in the anterior part of the corpus callosum in patients with bipolar disorder compared with MDD, which did not depend on the patients' affective state ( $x, y, z = -12, 28, 18$ ; 416 voxels;  $t = 5.21$ ;  $P < 0.001$ ; Fig. 2a). We found a significant positive correlation between the FA in the corpus callosum and the average of the IFC values of all measured homotopic regions in the anterior part of the cerebral cortical structures (Table 2). In consideration of the above finding, we expected significant correlations between the CC-FA and IFC in some of the individual homotopic areas. Therefore, we did not apply a multiple comparison correction for the analysis of the individual areas. As expected, we found a significant relationship between the CC-FA and IFC of the IC, IFG tri, and FORb (Table 2). Figure 2b shows the scatterplot of the significant partial correlation between the CC-FA and the average of the IFC of the IC, IFG tri, and FORb ( $r = 0.53$ ,  $P = 0.001$ ), with age, gender, MADRS scores, and duration of illness as covariates. Figure 2c shows the difference in average IFC values between patients with bipolar disorder and patients with MDD in these regions. Our results revealed significantly lower IFC of these homotopic areas in patients with bipolar disorder when compared to patients with MDD ( $F_{1,32} = 4.79$ ;  $P = 0.036$ ; adjusted IFC values with age, gender, MADRS scores, and duration of illness: bipolar disorder: 0.44 (s.d. = 0.17), MDD: 0.58 (s.d. = 0.14)).

**Table 1** The summary of the demographic characteristics in the participants of the study

Characteristic	BP	MDD	<i>t</i> or $\chi^2$	<i>P</i>
	( <i>n</i> =16)	( <i>n</i> =23)		
Age, years	47.1±8.6	44.3±9.8	<i>t</i> =0.87	0.39
Female, <i>n</i> (%)	6 (37.5%)	14 (60.9%)	$\chi^2=2.06$	0.15
Education, years	14.6±1.8	14.7±1.9	<i>t</i> =0.11	0.91
Family history, <i>n</i> (%)	4 (25.0%)	6 (26.1%)	$\chi^2=0.01$	0.62
Onset (age in years)	36.6±11.0	38.6±8.1	<i>t</i> =0.63	0.53
Duration of illness (years)	10.4±6.3	6.0±7.4	<i>t</i> =1.90	0.07
Young Mania Rating Scale (YMRS)	0.7±2.7	0.0±0.0	<i>t</i> =1.00	0.33
Montgomery Asberg Depression Rating Scale (MADRS) score	12.0±11.8	18.7±11.0	<i>t</i> =1.77	0.09
Medication, <i>n</i> (%)				
Lithium	10 (62.5%)	1 (4.3%)	$\chi^2=15.8$	<0.001 <sup>a</sup>
Other mood stabiliser	7 (43.8%)	2 (8.7%)	$\chi^2=6.53$	0.02 <sup>a</sup>
Antidepressant	7 (43.8%)	15 (65.2%)	$\chi^2=1.77$	0.18
Antipsychotic	6 (37.5%)	6 (26.1%)	$\chi^2=0.58$	0.34
Benzodiazepines	13 (81.3%)	12 (52.2%)	$\chi^2=3.47$	0.06

a.  $P < 0.05$ .  
BD, bipolar disorder; MDD, major depressive disorder.



**Fig. 2** (a) Regions with significant differences in fractional anisotropy (FA) values between patients with bipolar disorder and major depressive disorder (MDD). Sagittal and transverse brain views show voxels with significantly lower FA values in patients with bipolar disorder than patients with MDD. MNI coordinates for the crosshairs are  $x = -12$ ,  $y = 28$ ,  $z = 18$ . (b) Partial correlation between FA of corpus callosum and mean IFC value of IC, IFG tri, and FORb in all patients. There was a significant positive correlation between the FA of corpus callosum and mean IFC values when controlling for age, gender, disease duration, and MADRS score. Filled circle: bipolar disorder patients; open circle: MDD patients. (c) Scatter plots of mean IFC values of IC, IFG tri, and FORb in patients with bipolar disorder and MDD. IFC values were significantly lower in patients with bipolar disorder when compared to patients with MDD. IFC values were adjusted with the age, gender, disease duration, and MADRS score. Filled circle: bipolar disorder patients; open circle: MDD patients.

## Discussion

Consistent with previous study, patients with bipolar disorder showed significantly lower FA values in the anterior part of the corpus callosum compared with patients with MDD. The low anisotropy in the corpus callosum of patients with bipolar disorder has been reported before.<sup>7,13–15</sup> Our finding, however, is the first to highlight that structural abnormality within the frontal corpus callosum is relevant to the resting-state functional connectivity between geometrically corresponding interhemispheric regions in the anterior part of the cerebral cortical structures. Compared with MDD, significantly lower IFC values were associated with lower CC-FA values in the homotopic cortical regions in patients with bipolar disorder during depressed or euthymic states.

The corpus callosum has been generally studied in order to elucidate the pathophysiology underlying bipolar disorder. A meta-analysis has been reported of imaging studies of corpus callosum abnormalities in brain volumes<sup>16</sup> and a review of studies of white matter microstructure<sup>17</sup> among patients suffering from bipolar disorder. In our previous study,<sup>7</sup> lower CC-FA in patients with bipolar disorder was shown to be associated with higher radial diffusivity values, which could be interpreted as a disruption of myelin.<sup>18</sup> Demyelination decreases the function of the white matter tracts of the corpus callosum and might be related to the altered expression of glial and myelination genes described in patients with bipolar disorder.<sup>15</sup> Evidence from previous reports indicates that genes related to oligodendrocytes and myelin appear to be abnormally expressed in bipolar disorder.<sup>19,20</sup> Tkachev *et al*<sup>19</sup> reported a downregulation of erbB in bipolar disorder, a receptor for neuregulin1 (NRG1) that is known to be a growth factor crucial to myelination. Loss of NRG1-erbB signalling in oligodendrocytes in the adult brain has been shown to lead to reduced myelin thickness. This signalling pathway may also contribute to mental disorders through non-genetic mechanisms, as both NRG1 and erbB expression can be altered by environmental stressors such as forced locomotion.<sup>21</sup>

Because the corpus callosum is a white matter midline structure that connects the two cerebral hemispheres and allows interhemispheric communication, impairment in the white matter connectivity of the corpus callosum could disrupt functional integration and coordination. Owen *et al*<sup>22</sup> reported that patients with agenesis of the corpus callosum showed significantly reduced IFC on rfMRI. Our finding of an association between CC-FA and IFC for homotopic regions is consistent with these notions. Additionally, Shobe<sup>23</sup> presented a remarkable model concerning emotional regulation. In this model, the right hemisphere mediates the identification and comprehension of emotional stimuli, and the left hemisphere processes emotional information that has been shared within the hemispheres via the corpus callosum. Any microstructural abnormalities in the corpus callosum may degrade the exchange of emotional information between the hemispheres. The resulting emotional dysregulation could trigger affective instability in patients with bipolar disorder.

Direct structural connectivity via the corpus callosum does not appear to be the only determinant of the functional connectivity in healthy brains. Reported rfMRI studies of split-brain patients found that a normal complement of resting-state networks and intact functional coupling between bilateral hemispheres can emerge in the absence of the corpus callosum,<sup>24</sup> suggesting that IFC may thus arise from common subcortical drivers or complex network-level synchronisation. However, our finding of a direct association between CC-FA and IFC indicates that at least one function of the corpus callosum is as a strict determinant of the IFC, and its impairment could disrupt interhemispheric functional

**Table 2** Partial correlations between the CC-FA and IFC of the homotopic areas among patients with age, gender, disease duration, and MADRS score as covariates

Regions	Correlation (r)	P
Average of IFC values of all of measured homotopic regions	0.35	0.04 <sup>a</sup>
Individual homotopic regions		
FP (frontal pole right)	0.26	0.14
IC (insular cortex right)	0.40	0.02 <sup>a</sup>
SFG (superior frontal gyrus)	-0.25	0.16
MidFG (middle frontal gyrus)	-0.05	0.77
IFG tri (inferior frontal gyrus, pars triangularis)	0.40	0.02 <sup>a</sup>
IFG oper (inferior frontal gyrus, pars opercularis)	0.19	0.28
PreCG (precentral gyrus)	0.21	0.24
FOrb (frontal orbital cortex)	0.38	0.03 <sup>a</sup>

a.  $P < 0.05$ .

integration and coordination, which could be relevant to the pathophysiology of bipolar disorder.

Especially significantly lower IFC values associated with reduced CC-FA values were found in the homotopic ventral prefrontal cortex (IFG tri and FOrb) and IC in patients with bipolar disorder compared with MDD. The brain systems most likely to underlie bipolar disorder involve those that modulate emotional control, and the ventral prefrontal cortical areas and the insula cortex have consistently been associated with conscious emotional experience.<sup>25–28</sup>

The insula has been implicated in unsuccessful response inhibition<sup>29</sup> and emotion processing<sup>30,31</sup> and has extensive reciprocal connectivity with the ventral prefrontal regions.<sup>32,33</sup> Two ventral prefrontal networks appear to modulate emotional behaviour.<sup>34–37</sup> Both of these networks are organised in specific ventral prefrontal regions and map to specific striatal, pallidal, and thalamic brain areas to form iterative feedback loops that process information and modulate other limbic brain areas.<sup>34–38</sup> One network originates in the ventrolateral prefrontal cortex and is thought to modulate external emotional cues, such as in affective face tasks.<sup>38,39</sup> The other network originates in the ventromedial (orbitofrontal) cortex and is thought to modulate internal emotional stimuli (e.g. sadness in response to personal events).<sup>34,40</sup> Impairment of the interhemispheric functional integration and coordination of these emotion-regulation networks because of the abnormality of the corpus callosum is thought to serve as a likely substrate for the functional neuroanatomy of bipolar disorder.

### Study limitations

There were several limitations to the present study. First, the sample size of our study was not sufficiently large. We cannot exclude the possibility that the lack of significant differences in the imaging results and some demographic variables between groups is because of the effect of type II error. The partial correlations did not survive the Bonferroni correction between the CC-FA and IFC, which was possibly affected by the relatively small sample size of our study. Further, our study lacked a healthy control group, which made it difficult to position the results. Second, patients with bipolar disorder tended to have a longer duration of illness and a lower MADRS score than those with MDD. Although we analysed our data using duration of illness and MADRS score as covariates, this tendency should be taken into consideration. Third, the MDD and bipolar disorder groups differed regarding ongoing medications, particularly with respect to lithium. Lithium medication could thus be a potential confounder of the FA and IFC results. However, even if lithium medications exerted some effect on these results, the partial correlation analyses between the FA values in the corpus

callosum and the IFC in the homotopic regions remained unchanged even when we added lithium medications as a covariate to the analyses (all of measured homotopic regions:  $r=0.35$ ,  $P=0.05$ ; IC:  $r=0.41$ ,  $P=0.02$ ; IFG tri:  $r=0.03$ ,  $P=0.39$ ; FOrb:  $r=0.36$ ,  $P=0.04$ ). Nonetheless, studies examining patients newly diagnosed with bipolar disorder and MDD who have not been previously medicated would be useful in ruling out these effects. Fourth, our method of correlating IFC with a number of cortical areas using a single, spherical 5-mm voxel might have overlooked some of the meaningful connecting pathways that did not travel through that voxel. Fifth, we could not obtain reliable medical records of the exact number of bipolar disorder episodes because it was not uncommon for patients to consult multiple medical institutions during their relatively long disease duration. Therefore, we could not examine whether there were correlations between FA and IFC values and the number of episodes of bipolar disorder. Finally, the abnormal corpus callosum integrity and its relevant lower IFC between homotopic regions in patients with bipolar disorder were not dependent on the patients' depressive state as measured via the MADRS score. However, we did not have available FA values in the corpus callosum and its related IFC in patients with bipolar disorder during a hypomanic state. Therefore, in this study, we could not determine whether these could be regarded as a trait unrelated to the depressive and hypomanic states. Further studies with an increased number of drug-free participants including healthy controls and patients with bipolar disorder in a hypomanic state would be necessary to address these limitations.

### Implications

The present study revealed that patients with bipolar disorder had microstructural abnormalities in the anterior part of the corpus callosum during a depressed or euthymic state. Further, structural abnormalities within the frontal corpus callosum were relevant to the resting-state functional connectivity between geometrically corresponding interhemispheric regions in the anterior part of the cerebral cortical structures. Abnormalities in the corpus callosum may be related to the exchange of emotional information between the cerebral hemispheres, especially in the ventral prefrontal cortex and insula, resulting in emotional dysregulation. Further investigation with a larger number of patients with bipolar disorder is needed to clarify whether and, if so, how the low IFC affects the clinical presentation and treatment response of bipolar disorder.

**Fumihiko Yasuno**, MD, PhD, Department of Psychiatry, Nara Medical University, Kashihara, Japan; Neurology, National Cerebral and Cardiovascular Center, Suita, Japan; **Takashi Kudo**, MD, PhD, Department of Psychiatry, Osaka University Health Care Center, Toyonaka, Japan; **Kiwamu Matsuoka**, MD, Department of Psychiatry, Nara Medical University, Kashihara, Japan; **Akihide Yamamoto**, MS, Department of Investigative Radiology, National Cerebral and Cardiovascular Center, Suita, Japan; **Masato Takahashi**, MD, Department of Psychiatry, Nara Medical University, Kashihara, Japan; **Jyoji Nakagawara**, MD, PhD, Integrative Stroke Imaging Center, National Cerebral and Cardiovascular Center, Suita, Japan; **Kazuyuki Nagatsuka**, MD, PhD, National Cerebral and Cardiovascular Center, Suita, Japan; **Hidehiro Iida**, PhD, National Cerebral and Cardiovascular Center, Suita, Japan; **Toshifumi Kishimoto**, MD, PhD, Department of Psychiatry, Nara Medical University, Kashihara, Japan

**Correspondence:** Fumihiko Yasuno, Department of Psychiatry, Nara Medical University, 840 Shijocho, Kashihara, 634-8522, Japan. Email: ejm86rp@yahoo.co.jp

First received 11 Jan 2016, final revision 13 Aug 2016, accepted 20 Sep 2016

### Acknowledgements

The authors thank the staff of the MRI facility at the Department of Investigative Radiology of the National Cerebral and Cardiovascular Center in Japan for data acquisition during the MRI procedure.

## References

- 1 Marlinge E, Bellivier F, Houenou J. White matter alterations in bipolar disorder: potential for drug discovery and development. *Bipolar Disord* 2014; **16**: 97–112.
- 2 Emsell L, Leemans A, Langan C, Van Hecke W, Barker GJ, McCarthy P, et al. Limbic and callosal white matter changes in euthymic bipolar I disorder: an advanced diffusion magnetic resonance imaging tractography study. *Biol Psychiatry* 2013; **73**: 194–201.
- 3 Sarrazin S, Poupon C, Linke J, Wessa M, Phillips M, Delavest M, et al. A multicenter tractography study of deep white matter tracts in bipolar I disorder: psychotic features and interhemispheric disconnectivity. *JAMA Psychiatry* 2014; **71**: 388–96.
- 4 Wang F, Kalmar JH, Edmiston E, Chepenik LG, Bhagwagar Z, Spencer L, et al. Abnormal corpus callosum integrity in bipolar disorder: a diffusion tensor imaging study. *Biol Psychiatry* 2008; **64**: 730–3.
- 5 Lloyd AJ, Ali HE, Nesbitt D, Moore PB, Young AH, Ferrier IN. Corpus callosum changes in euthymic bipolar affective disorder. *Br J Psychiatry* 2014; **204**: 129–36.
- 6 Macritchie KAN, Lloyd AJ, Bastin ME, Vasudev K, Gallagher P, Eyre R, et al. White matter microstructural abnormalities in euthymic bipolar disorder. *Br J Psychiatry* 2010; **196**: 52–8.
- 7 Matsuoka K, Yasuno F, Kishimoto T, Yamamoto A, Kiuchi K, Kosaka J, et al. Microstructural differences in the corpus callosum in patients with bipolar disorder and major depressive disorder. *J Clin Psychiatry* 2016 (Epub ahead of print).
- 8 Yasuno F, Kazui H, Yamamoto A, Morita N, Kajimoto K, Ihara M, et al. Resting-state synchrony between the retrosplenial cortex and anterior medial cortical structures relates to memory complaints in subjective cognitive impairment. *Neurobiol Aging* 2015; **36**: 2145–52.
- 9 Matsuoka K, Yasuno F, Taguchi A, Yamamoto A, Kajimoto K, Kazui H, et al. Delayed atrophy in posterior cingulate cortex and apathy after stroke. *Int J Geriatr Psychiatry* 2015; **30**: 566–72.
- 10 Lenroot RK, Giedd JN. Sex differences in the adolescent brain. *Brain Cogn* 2010; **72**: 46–55.
- 11 Salat DH, Tuch DS, Hevelone ND, Fischl B, Corkin S, Rosas HD, et al. Age-related changes in prefrontal white matter measured by diffusion tensor imaging. *Ann N Y Acad Sci* 2005; **1064**: 37–49.
- 12 Taylor WD, Macfall JR, Boyd B, Payne ME, Sheline YI, Krishnan RR, et al. One-year change in anterior cingulate cortex white matter microstructure: relationship with late-life depression outcomes. *Am J Geriatr Psychiatry* 2011; **19**: 43–52.
- 13 Barysheva M, Jahanshad N, Foland-Ross L, Altshuler LL, Thompson PM. White matter microstructural abnormalities in bipolar disorder: a whole brain diffusion tensor imaging study. *Neuroimage Clin* 2013; **2**: 558–68.
- 14 Lagopoulos J, Hermens DF, Hatton SN, Tobias-Webb J, Griffiths K, Naismith SL, et al. Microstructural white matter changes in the corpus callosum of young people with bipolar disorder: a diffusion tensor imaging study. *PLoS One* 2013; **8**: e59108.
- 15 Mahon K, Burdick KE, Szeszko PR. A role for white matter abnormalities in the pathophysiology of bipolar disorder. *Neurosci Biobehav Rev* 2010; **34**: 533–54.
- 16 Arnone D, McIntosh AM, Chandra P, Ebmeier KP. Meta-analysis of magnetic resonance imaging studies of the corpus callosum in bipolar disorder. *Acta Psychiatr Scand* 2008; **118**: 357–62.
- 17 Bellani M, Yeh PH, Tansella M, Balestrieri M, Soares JC, Brambilla P. DTI studies of corpus callosum in bipolar disorder. *Biochem Soc Trans* 2009; **37**: 1096–8.
- 18 Alexander AL, Lee JE, Lazar M, Field AS. Diffusion tensor imaging of the brain. *Neurotherapeutics* 2007; **4**: 316–29.
- 19 Tkachev D, Mimrack ML, Ryan MM, Wayland M, Freeman T, Jones PB, et al. Oligodendrocyte dysfunction in schizophrenia and bipolar disorder. *Lancet* 2003; **362**: 798–805.
- 20 Carter CJ. eIF2B and oligodendrocyte survival: where nature and nurture meet in bipolar disorder and schizophrenia? *Schizophr Bull* 2007; **33**: 1343–53.
- 21 Roy K, Murtie JC, El-Khodori BF, Edgar N, Sardi SP, Hooks BM, et al. Loss of erbB signaling in oligodendrocytes alters myelin and dopaminergic function, a potential mechanism for neuropsychiatric disorders. *Proc Natl Acad Sci USA* 2007; **104**: 8131–6.
- 22 Owen JP, Li YO, Yang FG, Shetty C, Bukshpun P, Vora S, et al. Resting-state networks and the functional connectome of the human brain in agenesis of the corpus callosum. *Brain Connect* 2013; **3**: 547–62.
- 23 Shobe ER. Independent and collaborative contributions of the cerebral hemispheres to emotional processing. *Front Hum Neurosci* 2014; **8**: 230.
- 24 Tyszka JM, Kennedy DP, Adolphs R, Paul LK. Intact bilateral resting-state networks in the absence of the corpus callosum. *J Neurosci* 2011; **31**: 15154–62.
- 25 Bush G, Luu P, Posner MI. Cognitive and emotional influences in anterior cingulate cortex. *Trends Cogn Sci* 2000; **4**: 215–22.
- 26 Dunn LT, Everitt BJ. Double dissociations of the effects of amygdala and insular cortex lesions on conditioned taste aversion, passive avoidance, and neophobia in the rat using the excitotoxin ibotenic acid. *Behav Neurosci* 1998; **102**: 3–23.
- 27 Phillips ML, Drevets WC, Rauch SL, Lane R. Neurobiology of emotion perception I: the neural basis of normal emotion perception. *Biol Psychiatry* 2003; **54**: 504–14.
- 28 Reiman EM, Lane RD, Ahern GL, Schwartz GE, Davidson RJ, Friston KJ, et al. Neuroanatomical correlates of externally and internally generated human emotion. *Am J Psychiatry* 1997; **154**: 918–25.
- 29 Ramautar JR, Slagter HA, Kok A, Ridderinkhof KR. Probability effects in the stop-signal paradigm: the insula and the significance of failed inhibition. *Brain Res* 2006; **1105**: 143–54.
- 30 Phillips ML, Young AW, Senior C, Brammer M, Andrew C, Calder AJ, et al. A specific neural substrate for perceiving facial expressions of disgust. *Nature* 1997; **389**: 495–8.
- 31 Malhi GS, Lagopoulos J, Sachdev PS, Ivanovski B, Shnier R, Ketter T. Is a lack of disgust something to fear? A functional magnetic resonance imaging facial emotion recognition study in euthymic bipolar disorder patients. *Bipolar Disord* 2007; **9**: 345–57.
- 32 Augustine JR. Circuitry and functional aspects of the insular lobe in primates including humans. *Brain Res Brain Res Rev* 1996; **22**: 229–44.
- 33 Ongür D, Price JL. The organization of networks within the orbital and medial prefrontal cortex of rats, monkeys and humans. *Cereb Cortex* 2000; **10**: 206–19.
- 34 Yamasaki H, LaBar KS, McCarthy G. Dissociable prefrontal brain systems for attention and emotion. *Proc Natl Acad Sci USA* 2002; **99**: 11447–51.
- 35 Chen YC, Thaler D, Nixon PD, Stern CE, Passingham RE. The functions of the medial premotor cortex. II. The timing and selection of learned movements. *Exp Brain Res* 1995; **102**: 461–73.
- 36 Lane RD, Reiman EM, Axelrod B, Yun LS, Holmes A, Schwartz GE. Neural correlates of levels of emotional awareness. Evidence of an interaction between emotion and attention in the anterior cingulate cortex. *J Cogn Neurosci* 1998; **10**: 525–35.
- 37 Phan KL, Wager T, Taylor SF, Liberzon I. Functional neuroanatomy of emotion: a meta-analysis of emotion activation studies in PET and fMRI. *Neuroimage* 2002; **16**: 331–48.
- 38 Townsend J, Altshuler LL. Emotion processing and regulation in bipolar disorder: a review. *Bipolar Disord* 2012; **14**: 326–39.
- 39 Chen CH, Suckling J, Lennox BR, Ooi C, Bullmore ET. A quantitative meta-analysis of fMRI studies in bipolar disorder. *Bipolar Disord* 2011; **13**: 1–15.
- 40 Lane RD, Reiman EM, Ahern GL, Schwartz GE, Davidson RJ. Neuroanatomical correlates of happiness, sadness, and disgust. *Am J Psychiatry* 1997; **154**: 926–33.

