

LETTER TO THE EDITOR**To THE EDITOR****Horner's Syndrome and Thunderclap Headache**

Keywords: Horner's syndrome, Thunderclap headache, Reversible cerebral vasoconstriction syndrome

A 50-year-old woman presented to urgent care 2 days after an acute-onset holocephalic thunderclap headache while dining. Her past medical history was significant for ibuprofen-responsive unilateral episodic migraine headaches (4 times a month), fibromyalgia, and depression. Her medications included gabapentin and duloxetine. Her headache reached maximal intensity within seconds associated with nausea and photophobia. Neurological examination was reported as normal without meningismus. She was treated with intravenous ketorolac for presumed status migrainosus. She had symptom relief for 2 days, but the thunderclap headache returned unrelieved by ibuprofen use. She presented to the emergency room, and neurological examination was again reported as normal. Computed tomography head and neck angiogram (CTA) was reported as unremarkable with no aneurysm or subarachnoid hemorrhage. Cerebrospinal fluid profile was within normal limits. She was treated with intravenous ketorolac, diphenhydramine, and magnesium. A diagnosis of migraine was made, and she was referred to a local neurologist who prescribed sumatriptan and topiramate. She continued to suffer from recurrent thunderclap headaches with fluctuating intensity and no response to treatment.

One month after symptom onset, she was assessed at a headache clinic for a second opinion. Neurological examination demonstrated a left-sided partial ptosis and miosis worsened with decreased ambient light consistent with a left-sided Horner's syndrome, diagnosed with a positive apraclonidine test (Figure 1A, B). She denied anhidrosis. In retrospect, her husband had noted the left-sided partial ptosis 4 days after initial symptom onset. Repeat CTA (Figure 1C, D) and magnetic resonance imaging with contrast and dissection protocol demonstrated moderate-to-severe multifocal intracranial stenoses without dissection or thrombosis. Digital subtraction angiogram demonstrated similar findings. Repeat lumbar puncture was normal. Serum inflammatory and rheumatologic workup were negative. Screening for pheochromocytoma or carcinoid syndrome with urine vanillylmandelic acid and 5-hydroxyindoleacetic levels was negative.

Due to concern for reversible cerebral vasoconstriction syndrome (RCVS), she was discharged on verapamil 120 mg controlled release twice daily and advised to stop provoking agents, including duloxetine and sumatriptan. She was started on aspirin 81 mg prophylactically for possible radiographic-negative internal carotid artery (ICA) dissection. Twelve weeks after symptom onset, her headache resolved and did not recur upon discontinuation of verapamil. Repeat imaging demonstrated complete resolution of the multifocal vessels stenoses, confirming the diagnosis of RCVS (Figure 1E, F). However, her Horner's syndrome persisted, and she used apraclonidine drops as needed.

Red flags that warn of a secondary headache in this patient include an abrupt frequency change from 4 days per month to daily, a new location (from unilateral to holocephalic) and a change in her headache quality (thunderclap in nature). A thunderclap headache is a high-intensity, sudden-onset headache that reaches its maximal intensity within 60 seconds according to the International Classification of Headache Disorders.¹ A list of common causes of thunderclap headaches including secondary and primary headache disorders are illustrated in Table 1.

RCVS is a rare condition that occurs as a result of sudden cerebral vasoconstriction and it often presents with a thunderclap headache. It may be associated with cerebral ischemia, hemorrhages, and/or dissections leading to neurological deficits. There is no known cause for RCVS; however, it may be associated with some medications, such as antidepressants, triptans, immunosuppressants, decongestants, or illicit drugs. It is also associated with vasoactive secreting tumors, such as pheochromocytoma, carcinoid, or glomus tumors.²⁻⁵ Repeat imaging should be considered as CTA or magnetic resonance angiogram (MRA) may be normal for up to 20% of RCVS initially due to distal-to-proximal (centripetal) progression of vascular abnormalities.⁴

Horner's syndrome has previously been described in the context of RCVS due to ICA dissection through disruption of the third-order sympathetic neurons and it has previously been reported with normal vascular imaging,⁶ or it could also arise from ICA vasospasm.⁷ The vasoconstriction seen in RCVS is dynamic, and the centripetal progression could explain the absence of ICA vasospasm on imaging obtained at 4th week (vasoconstriction has not progressed to the ICAs yet). The prognosis of Horner's syndrome varies, and damage may be permanent.⁸

The patient was misdiagnosed on three separate occasions as having status migrainosus and migraine. The delay to accurate diagnosis may be explained by the following reasons: first, ptosis and anisocoria secondary to oculosympathetic pathway disruption are difficult to appreciate. It is vital to exclude a third nerve palsy from an aneurysm in the context of ptosis and anisocoria; however, for third nerve palsy, dilated pupil, profound ptosis, and/or ocular misalignment should be present. Second, head imaging, such as CTA and/or MRA, may be normal initially for RCVS due to the centripetal progression of angiographic abnormalities: small distal vessels were likely involved early in the disease course and there was a possibility that angiography could have missed the distal vasoconstrictions due to limitations related to angiographic techniques, interrogations, and/or quality of images.⁴ Third, there is a tendency to diagnose migraine exacerbation or status migrainosus among patients with a prior diagnosis of migraine. A thunderclap headache presenting with Horner's syndrome is a very rare presentation. However, this case emphasizes the importance of the physical examination, knowledge of clinical red flags, and understanding the strengths and limitations of

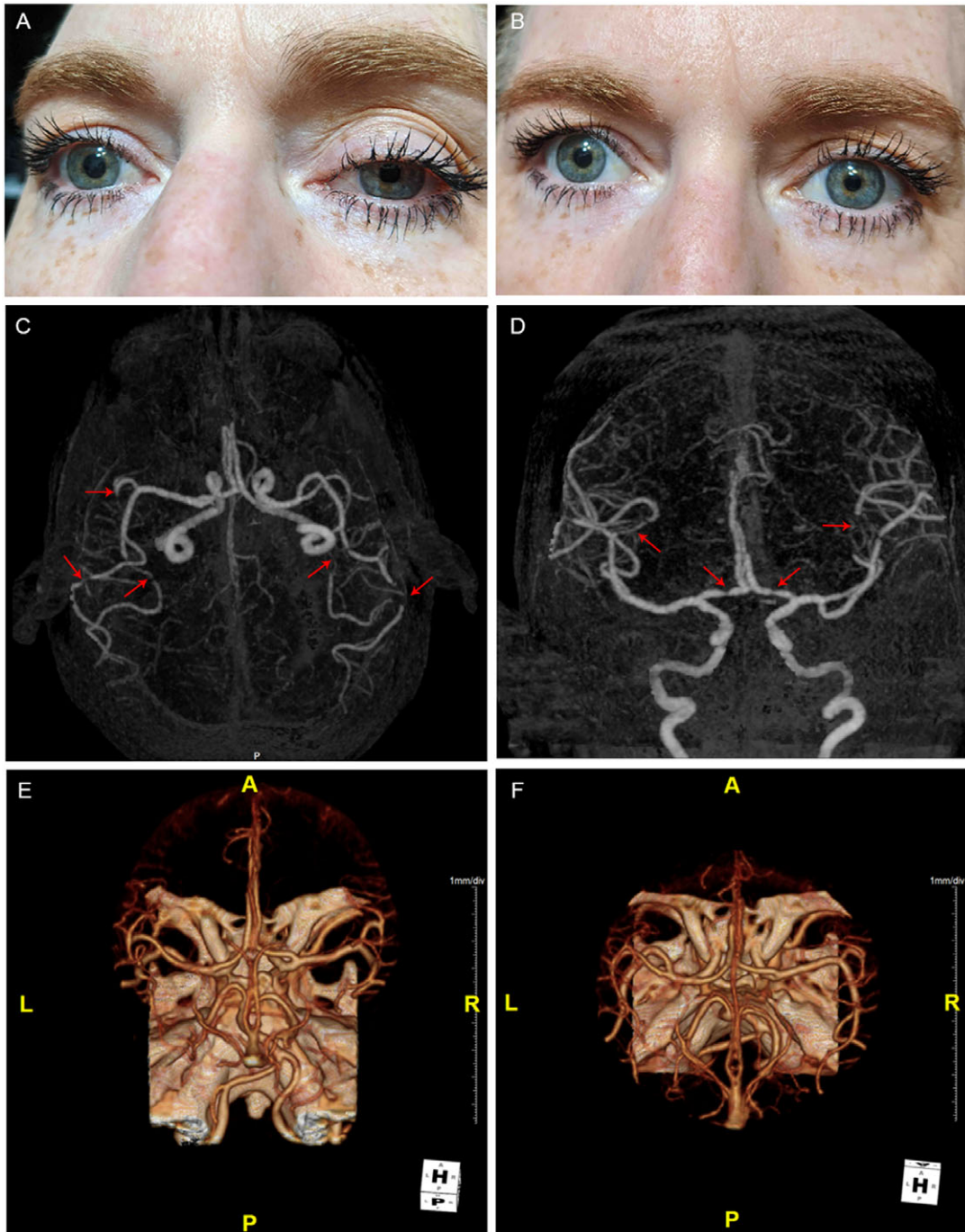


Figure 1: Before and after apraclonidine 0.5 mg eye drop: (A) (left) left-sided ptosis and miosis before apraclonidine and (B) (right) improvement of ptosis after apraclonidine. CTA 3D maximum intensity projection (MIP) of anterior circulation (4th week after symptom onset): (C) (left) multifocal stenoses of M2 branches of both middle cerebral arteries and (D) (right) multifocal stenoses of A1 branches of both anterior cerebral arteries and M2 branches of both middle cerebral arteries. CTA 3D MIP coronal (E) (left) and axial (F) (right) view (reformatted) (12th week after symptom onset): intracranial circulation at follow-up showed complete resolution of stenoses.

Table 1: Common causes of thunderclap headaches³

Differential diagnosis of thunderclap headaches	
Primary	Secondary
Migraine	Aneurysmal/non-aneurysmal subarachnoid hemorrhage
Trigeminal autonomic cephalalgias	Intracerebral hemorrhage
Primary thunderclap headache	Reversible cerebral vasoconstriction syndrome
Primary cough headache	Carotid/vertebral artery dissection
Primary exertional headache	Pituitary apoplexy
Primary headache associated with sexual activity	Cerebral vasculitis including primary angiitis of the central nervous system
	Spontaneous intracranial hypotension
	Cerebral venous sinus thrombosis
	Colloid cyst
	Meningitis

diagnostic tools in making a diagnosis, which is applicable for all neurological conditions.

CONFLICTS OF INTEREST

The authors have no conflicts of interest (financial or non-financial) to disclose relevant to this study. Dr. Tommy Lik Hang Chan reports no disclosures. Dr. David Dongkyung Kim reports no disclosures. Dr. Bryan Lanzman reports no disclosures. Dr. Addie Peretz reports no disclosures.

CONSENT TO PARTICIPATE

Informed consent was obtained from the patient.

AVAILABILITY OF MATERIAL


The material analyzed during the current study is available from the corresponding author on a reasonable request.

AUTHORS' CONTRIBUTIONS

TLHC examined the patient and wrote the manuscript. DKK edited and reviewed the manuscript. BL provided the radiographs. AP examined the patient and edited the manuscript. All authors read and approved the final version of the manuscript.

Tommy Lik Hang Chan 

Department of Neurology & Neurological Sciences, Stanford University, California, USA

David Dongkyung Kim 

Department of Clinical Neurological Sciences, Western University, Ontario, Canada

Bryan Lanzman

Department of Radiology, Stanford University, California, USA

Addie Peretz

Department of Neurology & Neurological Sciences, Stanford University, California, USA

Correspondence to: Tommy Lik Hang Chan, Department of Neurology & Neurological Sciences, Stanford University, Palo Alto, California, USA. Email: tommychan424@gmail.com

REFERENCES

- Headache Classification Committee of the International Headache Society (IHS). The International Classification of Headache Disorders, 3rd edition. Cephalalgia. 2018 Jan;38(1):1–211.
- Ducros A, Boussier M-G. Thunderclap headache. BMJ. 2013 Jan 8;346:e8557.
- Schwedt TJ, Matharu MS, Dodick DW. Thunderclap headache. Lancet Neurol. 2006 Jul;5(7):621–31.
- Ducros A, Boukobza M, Porcher R, Sarov M, Valade D, Boussier M-G. The clinical and radiological spectrum of reversible cerebral vasoconstriction syndrome. A prospective series of 67 patients. Brain. 2007 Dec;130(Pt 12):3091–101.
- Mawet J, Boukobza M, Franc J, et al. Reversible cerebral vasoconstriction syndrome and cervical artery dissection in 20 patients. Neurology. 2013 Aug 27;81(9):821–4.
- Mansukhani SA, Eckel LJ, Wu KY, et al. Horner syndrome due to internal carotid artery dissection with normal vascular imaging: a radiological conundrum. J Neuroophthalmol. 2020 [epub ahead of print]. doi: [10.1097/WNO.0000000000000981](https://doi.org/10.1097/WNO.0000000000000981).
- Janzarik WG, Ringleb PA, Reinhard M, Rauer S. Recurrent extracranial carotid artery vasospasms: report of 2 cases. Stroke. 2006 Aug;37(8):2170–3.
- Martin TJ. Horner syndrome: a clinical review. ACS Chem Neurosci. 2018 Feb 21;9(2):177–86.