

# Cystic hygroma of the head and neck

## A review of 37 cases

by

P. J. EMERY, F.R.C.S., C. M. BAILEY, BSc, F.R.C.S. and J. N. G. EVANS,  
F.R.C.S. (London)

### Introduction

Cystic hygroma is an uncommon benign developmental tumour which may grow so large that serious symptoms develop: treatment may be hazardous when the neck is involved. A brief discussion of cystic hygroma and its management is presented, followed by a review of 37 children with cystic hygroma of the head and neck seen at The Hospital for Sick Children, Great Ormond Street, London, over a 21-year period.

### Definition

Cystic hygroma consists of a multilocular cystic mass with individual cysts that vary from 1 mm. to 5 cm. or more in diameter. Some of the cysts communicate with each other, while others are isolated. The mass is usually not discrete: cysts and sheets of tissue pass in various directions, separating nerves, vessels and fascial planes. The cyst walls are lined with a single layer of flattened endothelium supported by a connective tissue stroma. The fluid within the cysts is serous, being clear or straw-coloured and occasionally blood-stained. Often the mass is intimately associated with groups of enlarged lymph nodes and the cysts may even contain lymph nodes, muscle fibres and thrombosed vessels which probably represent neighbouring tissues engulfed by the tumour.

### Development

Florence Sabin (1901) has shown that the lymphatic system arises from 5 primitive sacs developed from the venous system. These consist of paired jugular sacs, a single retroperitoneal sac and paired posterior sacs

near the sciatic veins. Endothelial out-buddings from these sacs extend centrifugally to form the peripheral lymphatic system. The cisterna chyli, the thoracic duct and the subclavian lymph sacs develop as secondary structures. McLure and Sylvester (1909) first suggested that cystic hygroma probably arises from sequestrations of lymphatic tissue derived from portions of the primitive sacs during embryonic life. He believed that these rests retain their rapid and proliferative growth potential. These sequestrations may never achieve anastomoses with the larger lymphatic channels. Goetsch (1938) did some further histological work, and found that sequestered lymphoid tissue formed cysts: endothelial fibrillar membranes sprout from the walls of the cysts, penetrate into surrounding normal tissue, and then canalize to produce more cysts filled with secretions from the fibrillae.

### General features

The most common site for cystic hygroma is the neck. Less frequent sites are the mediastinum, axilla, inguinal and retro-

peritoneal regions. The sexes are affected equally. 50–65 per cent are present at birth and 80–90 per cent are detected before the end of the second year of life. They may appear in adults as late as the fourth and fifth decades but this is very unusual. A review of surgical cases at the two largest hospitals in Phoenix, Arizona (Brooks, 1973) yielded 18 histologically authenticated cases during a 15-year period 1955–1970. An annual average of 19,000 surgical procedures were performed at these hospitals during this time. 27 cases of cystic hygroma (Mousattos and Baffes, 1963) were found from a total of 267 patients treated surgically for cervical masses over a 15-year period at the Children's Memorial Hospital in Chicago.

The most common presenting feature is a soft mass in the posterior triangle of the neck. It is usually fluctuant, lobulated and not attached to the skin but fixed to the deep tissues, and it will generally transilluminate. The mass may remain the same size, enlarge or appear to regress. There may be dysphagia or airway obstruction, and sudden enlargement with infection is common, particularly following trauma or respiratory tract infection. A common error in diagnosis is the small cystic hygroma which may be thought pre-operatively to be a branchial cleft cyst or lipoma.

## Treatment

Various forms of treatment have been used and these are outlined briefly.

### (1) *Expectant*

Some investigators advise that surgical treatment should be withheld because cystic hygroma may undergo spontaneous regression. Broomhead (1964) reported complete spontaneous regression in about 15 per cent of cases but many other workers dispute this concept, indicating that they have never seen complete involution. Although some cysts will decrease in size, they usually refill and there is always enlargement if the patient is followed over a long period of time.

### (2) *Aspiration*

Repeated aspirations are accompanied by

the risk of infection and haemorrhage into the cysts.

### (3) *Injection of sclerosing agents*

The sclerosing agent diffuses through the cyst fluid and penetrates the thin endothelial lining of the cysts, producing unpredictable scarring. However, the sclerosant may also penetrate into the venous system and surrounding tissues and may make subsequent surgical excision more difficult.

### (4) *Radium treatment*

Figi (1929) described 12 patients treated by radiotherapy, with complete regression in 3 and partial regression in 2, but the remaining 7 died of infection. Other workers have had similar results, and radiotherapy is no longer used because of its failure to completely destroy the tumour, possible damaging effects on the growth of local structures, and the potential induction of malignancy.

### (5) *Surgical excision*

This is considered to be the treatment of choice. Surgery is advised sooner rather than later as excision is technically easier before the tumour has further invaded normal tissue, and before infection has occurred and caused fibrosis and scarring. The dissection is usually difficult and tedious, especially when the hygroma closely involves the jugular vein, carotid artery and nerves of the carotid sheath. It is wiser to leave small bits of cyst than to divide important structures. However, remaining cysts increase the recurrence rate, although recurrence can be minimized by opening any cysts left behind. In an enormous cystic hygroma involving both sides of the neck it may be sensible to remove the tumour in sections as a staged procedure. With the removal of the cervical portion there may be appearance or enlargement of cysts in the parotid area.

Post-operative complications include infection, Horner's syndrome, recurrent laryngeal nerve palsy, and damage to the spinal accessory and marginal mandibular nerves.

Recurrence of cystic hygroma following surgical excision is generally said to occur within one year. Ravitch and Rush (1969)

report a recurrence rate of 10–15 per cent when portions of the cystic tumour are left behind. Leipzig and Rabuzzi (1978) reported a case which was dormant for 21 years following incomplete excision but then grew and extended rapidly in association with a mild upper respiratory infection.

The post-operative mortality is said to be 2.5 per cent (Brooks, 1973) although Brooks had no mortalities in his series of 18 cases of cystic hygroma operated upon over a 15-year period.

### **Patients**

37 children with cystic hygroma involving the neck were seen at The Hospital for Sick Children, Great Ormond Street, over a 21-year period 1962–82. The hospital case records of these patients were used as the basis for a retrospective study of the management and prognosis of the condition. Histology was available to confirm the diagnosis in 35 patients and the clinical findings were typical of cystic hygroma in the remaining 2 cases where histology was missing. The 37 children consisted of 19 females and 18 males. The main interest of this study was in those children who suffered upper airway obstruction or major feeding difficulties because of the size and site of their cystic hygroma.

### **Findings in children with airway or swallowing difficulties**

A total of 15 children were found to have suffered airway obstruction at some stage during the course of their condition. Feeding problems were often found to coexist. The enormous size of the cystic hygroma caused 3 babies to require forceps delivery because of delay in the second stage of labour. The cystic hygroma was present at birth in 13 of the children and first became noticeable in the neonatal period in the remaining 2 children.

Those cystic hygromas which gave rise to airway or feeding problems all involved the anterior triangle of the neck, with major cysts arising in the submandibular area and often extending into the floor of the mouth, base of

tongue and epiglottis. A sharp demarcation between anterior and posterior cervical triangles was not always entirely clear because of the extensive infiltration of tissue by further growth of the cystic hygroma. In 4 cases the cystic hygroma extended into the mediastinum and the parotid area was infiltrated in a further 6 cases. Airway problems were first apparent from the moment of birth in 2 children and during the neonatal period in 8. The remaining 5 children developed upper airway obstruction at an average age of 1 year 10 months (range 2 months—5 years 9 months). The precipitating factor was enlargement of cysts, often in association with an upper respiratory tract infection or local trauma. The severity of symptoms necessitated feeding gastrostomy in 2 children and tracheostomy in 10 of the children. Tracheostomy was performed at an average age of 1 year 8 months (range 2 days—5 years 9 months) and was required for an average duration of 8 months (range 5 days—3 years).

1 of the 15 children did not undergo surgical excision of the cystic hygroma; this child is awaiting endoscopic use of the carbon dioxide laser. 33 surgical excisions were performed in the remaining 14 children: only 5 had a single excision. The average age of the first operative procedure was 10 months (range 1 day—4 years 10 months). A wedge resection of the tongue was necessary in 4 cases with extensive glosal infiltration by cystic hygroma. In 7 of the children cyst aspiration with instillation of hypertonic saline or boiling water was used as an alternative treatment to excision, but in only one case was this successful. Repeated aspiration generally gave only very short-term benefit. In none of these 15 children was spontaneous regression significant over a period of follow-up lasting on average 8 years 10 months (range 3 months—20 years).

As a direct result of surgery, one-third of the children suffered a permanent nerve palsy. 2 children had a residual palsy of the marginal mandibular branch of the facial nerve and 1 child a complete facial nerve palsy; 1 child sustained phrenic nerve

damage and 1 an accessory nerve palsy. The morbidity of the condition, apart from involving frequent hospital admissions or attendances, included 1 child with significant cerebral dysfunction resulting from severe hypoxic episodes and another child with major psychological problems. Almost all had suffered episodic infection of the cystic hygroma requiring antibiotic treatment. Dental problems were common and consisted mainly of widespread caries secondary to poor oral and dental hygiene. An extensive cystic hygroma involving floor of mouth, tongue or cheek makes it difficult to clean teeth without inflicting trauma with bleeding and introduction of infection into the cysts, and thus some major dental conservation work was required. Mandibular bone growth was also affected in 2 children as a direct result of the position and site of the cystic hygroma. A mandibular augmentation was performed on one and is planned for the other.

Post-operative scarring was generally acceptable cosmetically except where infection had been a major problem.

#### **Findings in children without major symptoms**

There were 22 children with cystic hygroma of the neck which did not lead to significant feeding or airway problems. 11 of these had involvement of the submandibular area but in only one child was the floor of mouth infiltrated with cysts. The size of the cystic hygroma tended to be slightly smaller with 15 presenting at birth, 1 in the neonatal period and 5 between the ages of 3 months and 6 years 3 months. All were treated by excision and drainage apart from 2 children who were successfully managed by cyst aspiration alone. The average age at the first operation was 1 year 6 months (range 3 days–8 years) with only 4 children requiring an average of two further excisions.

In 3 children there was significant spontaneous resolution of residual cysts but 5 other children had recurrence at an average age of 4 years 6 months (range 2 years–9 years). The 22 children were followed for an

average of 5 years 6 months (range 8 months–14 years 3 months). The post-operative morbidity included one complete facial nerve palsy, two palsies of the mandibular branch of the facial nerve, one phrenic nerve palsy, one accessory nerve paresis and one Horner's syndrome.

#### **Discussion**

41 per cent of the children with cystic hygroma involving the neck suffered significant upper airway and feeding problems. The major factors appeared to be cyst size and site with extension into the floor of mouth, tongue, epiglottis or mediastinum being particularly dangerous. Initial growth or enlargement of the cystic hygroma occurred in all cases, often in association with upper respiratory tract infections. Initial surgery was performed an average of 8 months earlier in those children with airway or feeding problems than in those without major symptoms. Indications for surgery were usually local enlargement or failure to regress. The occurrence of post-operative nerve palsy appeared to be related to the size and extent of the cystic hygroma rather than to the age of the child at operation. The incidence of permanent post-operative nerve palsy was 33 per cent of all children who had their cystic hygroma treated surgically and 18 per cent of all operative excisions. There was an impression that, the sooner the excision was attempted, the better the long-term result. This was because delay generally resulted in further extension and enlargement of the cysts, with the added complication of scarring from infections: subsequent successful total excision was then less likely. Only 18 per cent of the children who had their cystic hygroma removed surgically were thought at the time of the operation to have had a complete excision. Because of this, low pressure suction drainage was used post-operatively in almost all cases for up to two weeks in duration. This prevented collections of secretions from cysts which had been left decapped or partially diathermized. There was a recurrence of cystic hygroma in 52 per cent of children known to have had an

incomplete excision. Spontaneous regression appeared to be a lucky occurrence rather than an event to be planned.

Children with airway obstruction due to infiltration of the supraglottis by cystic hygroma present a particularly difficult problem. However, preliminary results indicate that endoscopic use of the carbon dioxide laser may be an effective method of treatment, superseding diathermy coagulation.

Brief case summaries of the 15 children with airway or feeding problems are presented in the form of a table, with one illustrative case history included.

**Illustrative Case Report**

This child was referred to the Hospital for Sick Children, Great Ormond Street, at the age of 3 weeks. She had been born at full term by normal delivery following an uneventful pregnancy. However, she had a massive cystic hygroma which was present since birth and involved the floor of mouth, left parotid region and both anterior and posterior triangles of the neck. During the neonatal period she developed increasing respiratory obstruction made worse by crying. Tracheostomy was performed at the age of 4 weeks (Fig. 1). At this time cysts

TABLE SHOWING DETAILS OF 15 CASES WITH AIRWAY OR FEEDING PROBLEMS

Case	1	2	3	4	5	6	7	8	9	10	11	12	13	14	15
Sex	M	F	M	M	F	M	M	M	F	F	F	M	M	F	M
Site of cystic hygroma;															
R anterior triangle		+	+	+	+	+	+	+	+				+	+	+
L anterior triangle	+	+	+		+	+			+			+		+	+
R posterior triangle					+									+	
L posterior triangle	+											+		+	
submandibular					+				+		+	+	+	+	+
cheek		+	+	+					+		+			+	
floor of mouth		+	+	+	+	+			+	+	+		+	+	+
tongue			+		+				+		+			+	
supraglottic larynx				+	+	+			+	+	+			+	+
mediastinum							+	+				+	+		
C.H. present at birth	+	+	+	+	+	+	+	+	+		+	+	+	+	
C.H. appeared as neonate										+					+
Onset of dysphagia at birth									+						
Onset of dysphagia as neonate			+	+	+					+	+			+	
Onset respiratory obstruction;															
birth						+			+						
neonate	+	+		+	+					+			+	+	+
first year								+				+		+	+
after first year				+			+				+				
Tracheostomy				+	+	+	+	+	+	+	+			+	+
Total number of excisions	1	2	6	3	1	3	1	2	2	0	3	1	2	5	1
Wedge resection of tongue			+						+		+			+	
Cyst aspiration	+	+	+						+			+	+	+	
Morbidity;															
residual cystic hygroma	+	+	+		+	+	+		+	+	+	+		+	+
palsy 7th N. complete														+	
palsy 7th mandibular branch		+									+				
palsy 11th N.	+														
palsy phrenic N.								+							
cerebral defect						+									
occlusal defect		+												+	
Follow-up in years	2	14	20	3	$\frac{1}{4}$	11	16	6	$13\frac{1}{2}$	2	$13\frac{1}{2}$	5	8	17	$\frac{3}{4}$

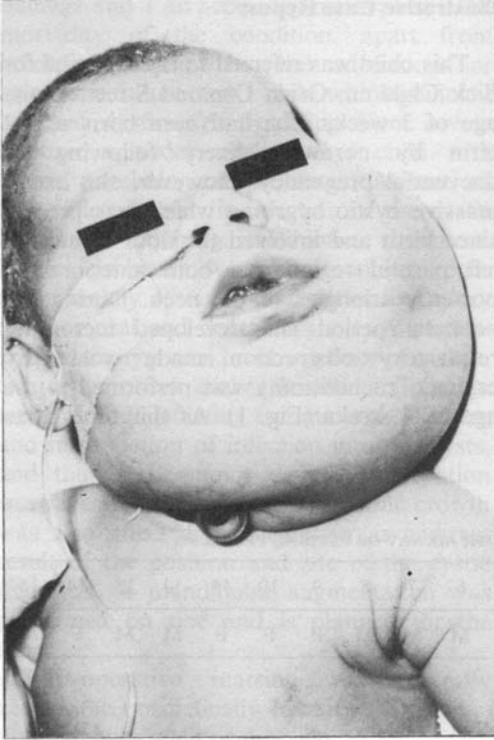


FIG. 1

Child aged 4 weeks. A large cystic hygroma involving the submandibular area, floor of mouth, tongue and parotid region. Note the protrusion of the tongue, feeding nasogastric tube and tracheostomy.

were noted on the epiglottis. Multiple cysts in the submandibular area were aspirated prior to partial excisions at the ages of 2 and 3 months. Decannulation was successful following a partial glossectomy performed at the age of 6 months. However, she continued to have problems with occasional bleeding from the tongue, and the cystic hygroma became infected and enlarged. This led to a further excision of cystic hygroma in the left cheek at the age of 2 years and post-operatively there was a complete left facial nerve palsy (Fig. 2). Multiple aspirations of cysts followed: the left facial nerve was explored at the age of  $2\frac{1}{4}$  years, but a cosmetic facial sling procedure was needed at the age of  $2\frac{3}{4}$  years. Recurrent cystic hygroma in the cheek and submandibular region was partially excised at the ages of  $3\frac{1}{2}$  and  $8\frac{1}{2}$  years. Many dental conservation pro-

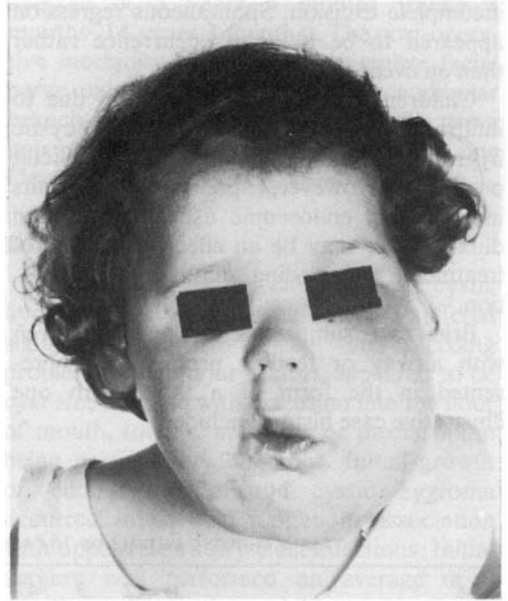

FIG. 2

The same child aged  $2\frac{1}{4}$  years following three subtotal excisions and partial glossectomy. There is residual cystic hygroma mainly involving the left cheek with a left facial nerve palsy and successful decannulation.

cedures were needed and a left mandibular augmentation was performed at the age of 16 years. Post-operative infection and sequestration led to subsequent removal of the graft. Follow-up at 17 years shows some poor scars, a complete left facial nerve palsy and some residual cystic hygroma.

### Summary

37 children with cystic hygroma of the head and neck are reviewed. 92 per cent of the children required surgical excision of the cystic hygroma and one-third of these children suffered a permanent nerve palsy. Spontaneous resolution of the cystic hygroma occurred in 8 per cent of the children over a period of follow-up lasting on average 7 years 2 months (range 3 months–20 years). 41 per cent of the children suffered significant upper airway and feeding problems.

### Acknowledgements

We would like to thank Mr. H. H. Nixon

(Consultant Paediatric Surgeon), and Mr. I. W. Broomhead and Mr. E. H. Gustavson (Consultant Plastic Surgeons) for kind permission to draw upon the experience of their cases at The Hospital for Sick Children, Great Ormond Street.

#### References

- BROOKS, J. E. (1973) Cystic hygroma of the neck. *Laryngoscope*, **83**: 117–128.
- BROOMHEAD, I. W. (1964) Cystic hygroma of the neck. *British Journal of Plastic Surgery*, **17**: 225–244.
- FIGI, F. A. (1929) Radium in the treatment of multilocular lymph cysts of the neck in children. *American Journal of Roentgenology*, **21**: 473–480.
- GOETSCH, E. (1938) Hygroma Colli Cysticum and Hygroma Axillae. *Archives of Surgery*, **36**: 394–479.
- LEIPZIG, B. and RABUZZI, D. D. (1978) Recurrent massive cystic lymphangioma. *Otolaryngology September–October*; **86(5)**: ORL: 758–760.
- MCLURE, C. F. W. and SYLVESTER, C. F. (1909) A comparative study of the lymphaticovenous communications in adult mammals. *Anatomical Record*, **3**: 534–552.
- MOUSATTOS, G. H. and BAFFES, T. G. (1963) Cervical masses in infants and children. *Paediatrics*, **32**: 251–256.
- RAVITCH, M. M. and RUSH, B. F. Jr. (1969) Cystic hygroma. In *Paediatric surgery*. 2nd Edition. Mustard W. T., Ravitch, M. M., Synder, W. H. Jr., Welch, K. J., Benson, C. D., Editors. Year book Medical Publishers, Inc., Chicago, Ill., **1**: 273–279.
- SABIN, F. R. (1901) On the origin of the lymphatic system from the veins and the development of the lymph heart and thoracic duct in the pig. *American Journal of Anatomy*, **1**: 367–389.

Address for correspondence:

Pauline Emery  
Senior Registrar in ENT  
The Hospital for Sick Children  
Great Ormond Street  
London WC1N 3JH

