

Delayed pericardial effusion and cardiac tamponade following penetrating chest trauma

Laura Donahoe, MD*[†]; Maral Ouzounian, MD[†]; Scott MacDonald, MD[†]; Simon Field, MBBCh[†]

ABSTRACT

We present the case of a 20-year-old man who was stabbed in the left chest and was diagnosed with a large pericardial effusion by focused emergency department (ED) ultrasonography. After placement of a left chest tube for presumed tension pneumothorax, the pericardial effusion had resolved. The patient's postinjury course was complicated by pericarditis and recurrent tamponade, which required repeated pericardiocentesis for management. This case illustrates the role of focused ED ultrasonography for diagnosis of pericardial effusion in penetrating trauma and the potential for delayed pericardial effusion and tamponade in such patients. Although the pathophysiology of delayed pericardial effusion is unclear, autoimmune postpericardiotomy syndrome has been proposed as the cause of this rare condition. Our case underscores the importance of close monitoring of patients with known or suspected pericardial injuries due to their potential for the development of life-threatening complications.

RÉSUMÉ

Nous faisons état, dans le présent article, du cas d'un homme de 20 ans qui a reçu des coups de couteau dans le thorax gauche; une échographie focalisée, effectuée au service des urgences (SU) a permis de diagnostiquer un important épanchement péricardique. Après la pose d'un drain thoracique à gauche pour traiter un pneumothorax à soupape présumé, l'épanchement péricardique s'est résorbé. Toutefois, la convalescence s'est compliquée d'une péricardite et de tamponnades récidivantes, qui ont nécessité des ponctions péricardiques à répétition. L'exposé de cas met en évidence le rôle de l'échographie au SU dans le diagnostic d'un épanchement péricardique consécutif à une blessure pénétrante et le risque d'apparition tardive d'un épanchement péricardique et de tamponnade en pareilles circonstances. L'on ne connaît très bien le processus physiopathologique de l'épanchement péricardique, mais certains ont avancé le syndrome de postpéricardiotomie auto-immune comme

cause possible de cette affection rare. La description du cas fait ressortir l'importance de la surveillance étroite des patients chez qui il y a une présence présumée ou avérée de lésions péricardiques, en raison du risque d'apparition de complications potentiellement mortelles.

Keywords: delayed tamponade, focused emergency department ultrasonography, stab wound

Penetrating trauma to the heart has historically resulted in prehospital mortality.¹ However, owing to improvements in emergency medical service care, an increasing number of such patients now survive to reach the emergency department (ED). Focused ED ultrasonography is now used with increasing frequency to diagnose pericardial effusion in the setting of penetrating trauma. When an effusion is diagnosed, pericardiocentesis, subxiphoid pericardial window, or open thoracotomy is indicated, either alone or in combination, to prevent or relieve tamponade. Occasional cases have been reported of delayed pericardial effusion and tamponade after a thoracic stab wound. We present the case of a traumatic pericardial effusion that initially resolved but was subsequently followed by pericarditis and delayed tamponade and illustrate the role ultrasonography played in the diagnosis and management of the case.

CASE REPORT

A 20-year-old man presented to the ED after being stabbed twice in the chest, once in the left sixth interspace in the anterior axillary line and once in the right posterior sixth interspace. On assessment in the

From the *Division of General Surgery; †Division of Cardiac Surgery, and ‡Department of Emergency Medicine, Dalhousie University, Halifax, NS.

Correspondence to: Dr. Laura Donahoe, Dalhousie University, Division of General Surgery, QEII Health Sciences Centre, 1276 South Park Street, Halifax, NS B3H 2Y9; Laura.Donahoe@Dal.ca.

This article has been peer reviewed.

© Canadian Association of Emergency Physicians

CJEM 2013;15(3):187-190

DOI 10.2310/8000.2012.120729



CJEM • JCMU

2013;15(3) 187

ED, he was alert, oriented, and complaining of chest pain. His blood pressure (BP) was 110/62 mm Hg, and his heart rate (HR) was 92 beats/min, but he quickly became somnolent, and his BP fell to 60 mm Hg systolic. Focused ED ultrasonography was performed, and a large pericardial effusion was noted by two emergency physicians, both of whom had training in ED ultrasonography. A right-sided tension pneumothorax was suspected on clinical grounds as there was decreased air entry on the right with distended neck veins, and a chest tube was rapidly placed on that side. Once this action was taken, the patient's vital signs stabilized. The ultrasonography was then repeated and indicated that the pericardial effusion had resolved. The absence of an effusion was confirmed 1 hour later by formal echocardiography. A chest radiograph 2 hours later demonstrated a left pleural effusion, and a left chest tube was placed.

The patient was admitted for monitoring in an intermediate care unit. On postadmission day 1, his left chest tube was removed. On day 2, the patient was noted to have diffuse ST segment elevation in his precordial leads, consistent with pericarditis. An echocardiogram showed a small pericardial effusion, and the patient was commenced on ibuprofen. On day 3, the patient was found to have a persisting air leak from the right chest tube and was therefore kept in hospital. He did well until the early hours of day 6, when he complained of a "funny feeling" in his chest. Soon afterward, he became pale and diaphoretic with reduced responsiveness and

was found to have a BP of 46/20 mm Hg. He was initially resuscitated with intravenous fluids and inotropes in the intensive care unit, and a moderate-sized pericardial effusion with evidence of right atrial and right ventricular collapse consistent with cardiac tamponade was found on an echocardiogram (Figure 1). A pericardial drain was urgently placed under echocardiographic guidance, with immediate resolution of his symptoms and hemodynamic instability. Three hundred millilitres of hemorrhagic fluid was drained, which subsequently grew *Propionibacterium acnes*. The patient was initially treated for this with parenteral antibiotics; however, the Infectious Disease team felt that this was likely a contaminant and not pathogenic. On day 10, there was resolution of the diffuse ST elevation, and the drain was removed. The patient was discharged from hospital on day 11 without any residual pericardial effusion on his pre-discharge echocardiogram.

Four weeks later, the patient was sent for a follow-up outpatient echocardiogram. At that time, he was found to be pale and described increased shortness of breath, fatigue, and orthopnea over the preceding week. The echocardiogram showed an extremely large pericardial effusion with evidence of tamponade. Assessment of left and right ventricular function was difficult owing to swinging of the heart. The patient was immediately transferred to the ED, where he was found to have an HR of 116, BP of 114/74 mm Hg, jugular venous pulsation at the angle of the jaw, a pulsus paradoxus of 10 mm Hg, and electrical alternans on an electrocardiogram.

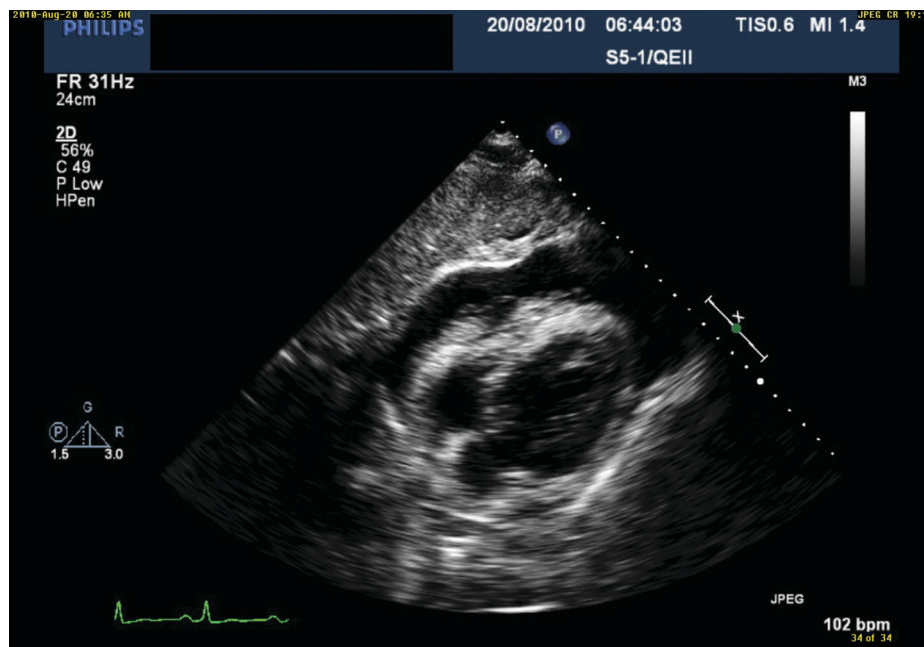


Figure 1. Echocardiogram illustrating moderate-sized pericardial effusion with right atrial and right ventricular collapse consistent with cardiac tamponade.

Pericardiocentesis was performed, 1.8 L of fluid was drained, and the patient was readmitted to hospital. During this admission, he was also diagnosed with a pulmonary embolus and started on anticoagulation. On a repeat echocardiogram 3 days after admission, a little pericardial fluid was found. He was discharged home, and on a repeat echocardiogram 2 weeks later showed that no pericardial effusion was present.

DISCUSSION

Delayed pericardial effusion with tamponade after penetrating trauma, although previously reported, is exceedingly rare. A review by Aaland and Sherman in 1991 identified 30 previously reported cases, only 8 of which were after 1950.² Given the paucity of published experience with this condition, our understanding of the pathophysiology and treatment of delayed pericardial tamponade is limited.

As trauma care and technological resources evolve, an increasing number of emergency physicians are employing focused ED ultrasonography in trauma patients. Although ED ultrasonography was initially advocated only for blunt trauma, Boulanger and colleagues found that it is useful for diagnosing pericardial effusion in penetrating trauma.³ In our patient, the initial sonogram was positive for a large pericardial effusion. As the patient was deteriorating, a chest tube was placed on the right side, after which he improved, almost certainly from decompression of a tension pneumothorax on that side. However, his pericardial effusion also resolved subsequent to the right chest tube placement; thus, there may also have been a component of cardiac tamponade contributing to his initial hemodynamic instability. It is conceivable that the stab wound to the left chest wall caused the pericardial effusion and later the left pleural effusion. Horton and Slovis reported a case of spontaneous resolution of cardiac tamponade and hemodynamic instability prior to thoracotomy.⁴ In their case, a right thoracostomy tube had been placed after diagnosis of cardiac tamponade from a stab wound to the right chest. Although the chest tube initially only drained a minimal amount of blood, the patient's worsening clinical status suddenly improved after drainage of a large amount of blood through the chest tube, and only a small amount of blood in the lacerated pericardial sac was found at the time of thoracotomy.

The pathophysiology of delayed pericardial effusion causing tamponade is unclear. In the largest published

review, Harris and colleagues reported 24 patients with delayed pericardial effusion after a stab wound to the chest.⁵ They concluded that postpericardiotomy syndrome, an autoimmune pericarditis and pleuritis most commonly following cardiac surgery, was the most likely cause of the delayed pericardial effusions as no cases were found to have active bleeding on repair. Other proposed mechanisms that have been proposed for this condition are lacerations of the coronary arteries and smaller blood vessels with initial thrombus formation and later seepage of blood from the injured vessel⁶ or spasm of the vessels with bleeding once the spasm resolves.⁷ Although we suspect that postpericardiotomy syndrome was the etiology in our patient, he had a pericardial fluid culture that was positive for *P. acnes*, raising the possibility that inoculation from the weapon resulted in bacterial contamination of the pericardium, causing a delayed effusion.

In most reported cases, diagnosis of pericardial effusion and tamponade has been made with two-dimensional echocardiography.^{2,6,8-10} There have, however, been reports of normal imaging prior to effusion development.^{9,10} Although the initial treatment of pericardial tamponade with volume resuscitation and effusion drainage is well known, the optimal definitive treatment of this condition remains unclear. The 24 patients described by Harris and colleagues underwent subxiphoid pericardial exploration,⁵ whereas in the review by Aaland and Sherman, the 8 patients managed after 1950 were treated with thoracotomy, sternotomy, or repeated pericardiocentesis.² In many other reported cases, sternotomy or thoracotomy has been performed for definitive management.⁶⁻¹¹ In the case of our patient, management included placement of a pericardial drain, which was removed 2 days after insertion. The recurrent effusion that subsequently developed was also treated with percutaneous drainage. Conservative management may be an option for such patients, although close surveillance with imaging is mandatory.

CONCLUSION

Delayed pericardial effusion after penetrating trauma is rare, and, as a result, no guidelines or consensus exists for its management. There are insufficient data to make firm recommendations regarding the length and frequency of surveillance for such patients; however, our case illustrates the importance of close monitoring with regular clinical assessment and patient instructions to return if

recurrent symptoms develop. Focused ED ultrasonography is a useful and increasingly common tool for the diagnosis and emergent treatment of pericardial effusion in the setting of penetrating thoracic trauma.

Competing interests: None declared.

REFERENCES

1. Hensell MG. Review of blunt and penetrating trauma of heart and greater vessels. *Top Emerg Med* 2001;23:20-5.
2. Aaland MO, Sherman RT. Delayed pericardial tamponade in penetrating chest trauma: case report. *J Trauma* 1991;31:1563-5, doi:10.1097/00005373-199111000-00022.
3. Boulanger BR, Kearney PA, Tsuei B, et al. The routine use of sonography in penetrating torso injury is beneficial. *J Trauma Injury Infect Crit Care* 2001;51:320-5, doi:10.1097/00005373-200108000-00015.
4. Horton P, Slovis CM. Spontaneous drainage of cardiac tamponade. *Ann Emerg Med* 1983;12:96-8, doi:10.1016/S0196-0644(83)80382-5.
5. Harris DG, Janson JT, Van Wyk J, et al. Delayed pericardial effusion following stab wounds to the chest. *Eur J Cardiothorac Surg* 2003;23:473-6, doi:10.1016/S1010-7940(03)00006-X.
6. Bozinovski J, Wang S, Nakai S. Delayed cardiac tamponade after coronary artery laceration. *Ann Thorac Surg* 2002;73:1314-5, doi:10.1016/S0003-4975(01)03191-5.
7. Bellanger D, Nikas DJ, Freeman JE, et al. Delayed posttraumatic tamponade. *South Med J* 1996;89:1197-9, doi:10.1097/00007611-199612000-00013.
8. Mechem CC, Alam G. Delayed cardiac tamponade in a patient with penetrating chest trauma. *J Emerg Med* 1997;15:31-3, doi:10.1016/S0736-4679(96)00240-5.
9. Enriquez SG, Fernandez CG, Entem FR, et al. Delayed pericardial tamponade after penetrating chest trauma. *Eur J Emerg Med* 2005;12:86-8, doi:10.1097/00063110-200504000-00008.
10. Karmy-Jones R, Yen T, Cornejo C. Pericarditis after trauma resulting in delayed cardiac tamponade. *Ann Thorac Surg* 2002;74:239-41, doi:10.1016/S0003-4975(02)03477-X.
11. Nijjer SS, Dubrey SW, Dreyfus GD, et al. Delayed pericardial effusions: life-threatening complication presenting up to 100 days after chest trauma. *Clin Med* 2010;10:88-90.